

A preliminary study on possible effects of mitomycin-c on the collagen content of penis in rat

Abstract

Aim: Peyronie's disease is a disorder of the penile tunica albuginea characterized by development of a fibrotic plaque. This is a preliminary study that looking for the effects and probable side effects of mitomycin-C (as potential anti-fibroblast and anti-collagen properties) on normal tunica albuginea.

Methods: Ten rats were allocated to three groups. Group 1 (two rats as control group) received saline injection; in groups 2 (six rats) and 3 (two rats), 0.01 mg mitomycin-c were injected in tunica albuginea layer. The specimens were achieved after sacrificing of rats after 1 week in group 1 and 2 and 4 weeks in group 3. All tissue sections were stained by Haematoxylin-Eosin and Masson trichrome. The staining density reflects the collagen content of tissues was quantified by quantitative image analysis (QIA). Collagen density was determined one week following the injection in groups 1 and 2; after 4 weeks in group 3.

Results: Although the results were better after injection, there was no significant difference between the groups. We did not have any local complications.

Conclusion: Although collagen density was reduced after injection, there was no significant difference between the groups. Further investigations are warranted to confirm our study and evaluate the effect of mitomycin-C on pathologic penile tissue (PD).

Keywords: peyronie's disease, mitomycin-C, rat

Volume 3 Issue 4 - 2016

Seyed Reza Hosseini,¹ Mohammad Ghassem Mohseni,¹ Farshid Alizadeh²

¹Department of Urology, Tehran University of Medical Sciences, Iran

²Department of Urology, Isfahan University of Medical Sciences, Iran

Correspondence: Farshid Alizadeh, Department of Urology, Isfahan University of Medical Sciences, No. 20, Farhad Alley, Daneshgah Blvd., Isfahan, Iran, Tel 989133179509, Email f_alizadeh_md@yahoo.com

Received: July 30, 2016 | **Published:** September 7, 2016

Abbreviations: QIA, quantitative image analysis; PD, peyronie's disease; TA, tunica albuginea

Introduction

Peyronie's disease (PD) involves localized fibrotic plaque formation in the penile tunica albuginea (TA), leading to curvature of the erect penis and often to pain and/or erectile dysfunction, and affecting 9% of men.¹⁻³ The primary reason for this and the cause of the PD plaque is unknown and the molecular pathology is poorly understood, although it is thought that often the plaque develops as the result of an abnormal wound healing process after a TA trauma.⁴⁻⁶ Peyronie's disease is characterized by development of a fibrotic plaque.⁷ After the trauma fibrin triggers fibroblast activation and proliferation that results in excessive deposition of extracellular collagen matrix in the tunica albuginea.⁸⁻¹⁰ The formation of excessive fibrous tissue may also be triggered in genetically predisposed individuals, either from abnormal fibroblastic activity or decreased fibrinolysis.^{9,10} Indeed when a blunt trauma involves tunica albuginea, it can break the fibers of the tunica itself with extravasation, thus creating an area of inflammatory edema and cell infiltration that cytokines and secretions, such as TGF- β , are released by the inflammatory cells, producing a vicious cycle that finally leads to an excessive production of intercellular matrix and collagen fibers. The mitomycin-c has anti-fibroblast and anti-collagen properties and in sporadic reports of animals and clinical studies, it has increased the success rate of trabeculectomy for glaucoma and myringotomy in otitis media.¹¹⁻¹³ In the present study, we investigated the effect of the injection of mitomycin c, anti-fibroblast and anti-collagen agent, on the collagen density of normal tunica albuginea, aiming to evaluate its role as a treatment for PD.

Materials and methods

Ten rats Male Fisher (8-9 month old) were included in our study and assigned in 3 groups. The Review Board and Ethics Committee of Tehran University of Medical Sciences approved the study. In group 1 (two rats) and groups 2 (six rats) saline and 0.01 mg mitomycin-c were injected in tunica albuginea layers respectively, In group 3 (two rats), 0.01 mg mitomycin-c was injected in tunica albuginea layer and specimens were achieved after sacrificing of rats after 1 week in group 1 and 2 and 4 weeks in group 3. The confirmation of proper site injection in tunica albuginea was achieved by aspiration of syringe during injection and all of the injections were in tunica layer that confirmed in final pathology samples. All of the resected penile specimens were fixed in 10% buffered isotonic formaldehyde solution, cut longitudinally and embedded in paraffin blocks after routine tissue processing.

3-5 micron thick paraffin sections were submitted for routine Haematoxylin-Eosin (H&E) and trichrome staining after rehydration. The term "trichrome stain" is a general name for a number of techniques essentially using three dyes to demonstrate collagen fibers and to differentiate them from muscle and fibrin tissues. We applied Masson trichrome technique according to the procedure stated by Bradbury and Gordon. In this procedure collagen appears blue while the muscle, cytoplasm and erythrocytes appear red. Trichrome staining was done in a single run for all samples along with control tissue sections.¹⁴ All stained slides were dehydrated, cleared, mounted and subsequently examined blindly under light microscopy (Olympus model BX-51; Olympus optical Co. Ltd.). The average thickness (micrometer) of the sub epithelial connective tissue (Bucks fascia) and the tunica albuginea as well as the approximate number

of inflammatory cells per high power field were determined by the aid of computerized imaging software (Olysia Biorepot software- soft imaging system- GmbH) version 3.2 Build 8/0 and Olympus DP-12 digital camera (Figure 1).

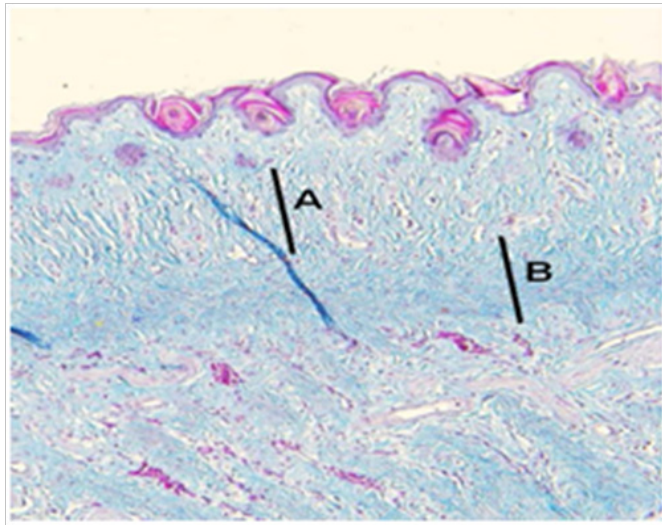


Figure 1 A section of the specimen.

Although visual estimation of collagen content is made by comparing the intensity of blue stain in connective tissue, we applied the digital imaging software for more accurate histological evaluation of the collagen content in bucks fascia and tunica albuginea, the blue pixel characteristics of at least 10 representative points in each specimens seen as blue stained areas in trichrome stained slides under the light microscope (100) were recorded and the mean values of blue color pixel characteristics including hue, intensity and saturation for each specimen was measured using the imaging software (Table 1 & Table 2). The pairs of groups were compared by the *t*-test. Multiple comparisons among groups were analyzed by one-way ANOVA. Differences were considered significant at $P < 0.05$.

Table 1 Intensity and saturation of layers of buck's fascia

Group	Mean	Hue	Intensity	Saturation
1	220	188	202	22.1
2	205	178	185	17
3	195	170	170	13

Table 2 Intensity and saturation of tunical albuginea

Group	Mean	Hue	Intensity	Saturation
1	232	193.5	202	29
2	215	180	190	24
3	195	165	183	20

(Group 1= control; Group 2=1wk after injection; Group 3=4wk after injection).

Results

The density of collagen fibers was not significantly different in the three groups ($P > 0.05$). Table 1 and Table 2 shows the Mean Hue, intensity and saturation of layers of buck's fascia and tunical albuginea in stained specimen of the three groups respectively. Although this

data were better after injection, there was no significant difference between the groups. We did not have any local complications.

Discussion

The pathogenesis of Peyronie's disease remains poorly understood. A better knowledge of Peyronie's disease pathogenesis could help us have more treatment options. Therapy options, particularly for the late phase of Peyronie's disease are severely limited.^{4,5} No medical treatment that can relieve all symptoms in patients with Peyronie's disease is currently available. The efficacy of multiple intralesional therapy has been proved in a single blind, multicentre, placebo-controlled study.¹⁵ Peyronie's disease is a disorder of the penile tunica albuginea characterized by development of a fibrotic plaque. The pathogenic mechanisms of this disease are still unclear.⁷ Current research suggests that PD represents a localized aberration of the wound-healing process. Stimulation of cytokine release, predominantly TGF- β , was suggested to lead to the deposition of the extracellular matrix proteins.

Animal models and plaques derived from men with PD have increased TGF- β expression in the tunica albuginea.^{14,16} The focal areas of fibrous tissue are laid down in this subtunical layer, which is eventually completely replaced by fibrous tissue. The inflammatory infiltrate, with its activated cytokine network (particularly TGF β 1 and basic fibroblast growth factor) seem to play a major role in the ensuing fibrogenesis.^{14,17} Mitomycin-C is an alkylating antineoplastic antibiotic derived from *Streptomyces sp.* specially *S. caespitosus*. It acts by cross-linking DNA between adenine and guanine, thereby inhibiting DNA synthesis. It also suppresses cellular RNA and protein synthesis and is not cell cycle specific. Therefore, it is useful in delaying the healing process by prohibiting the replication of fibroblasts and epithelial cells and inhibiting collagen synthesis.^{18,19} Other studies on mitomycin-C have shown its efficacy in preventing fibroblast proliferations and the development of fibrosis after myringotomy and trabeculectomy, thus improving the success rate of these procedures. Heran et al.²⁰ showed topical mitomycin-C for recalcitrant esophageal strictures.

They showed that topical application of mitomycin-C to esophageal strictures that persist despite diligent pneumatic balloon dilation or esophageal bougienage appears to have therapeutic efficacy in reducing stricture recurrence owing to its inhibition of collagen synthesis. Although mitomycin-C has anti-fibroblast and anti-collagen properties, our study showed that the injection of mitomycin-c cannot alter collagen density in normal penile tissue (slow collagen turnover) significantly. The limitation of this study is not evaluating the effect of mitomycin-C in pathologic penile tissue (PD rat model [TGF]). The study puts forward the hypothesis that the injection of mitomycin-C may be used in treating PD; as a result, other animal or clinical studies are required to evaluate the effect of mitomycin-C on PD. The study is limited by its small sample size. Moreover, the response of a diseased tissue may differ from the normal one.

Conclusion

Although the results were better after injection, there was no significant difference between the groups. Further investigations are warranted to confirm our study and evaluate the effect of mitomycin-C on pathologic penile tissue (PD).

Acknowledgments

None.

Conflicts of interest

The author declares there is no conflict of interest.

References

- Gholami SS, Gonzalez-Cadavid NF, Lin CS, et al. Peyronie's disease: a review. *J Urol.* 2003;169(4):1234–1241.
- Gonzalez-Cadavid NF, Rajfer J. *Molecular and cellular aspects of the pathophysiology of Peyronie's disease.* Drug Discov Today: Disease mechanisms. 2005.
- Mulhall JP, Creech SD, Boorjian SA, et al. Subjective and objective analysis of the prevalence of Peyronie's disease in a population of men presenting for prostate cancer screening. *J Urol.* 2004;171(6 Pt 1):2350–2353.
- Davila HH, Ferrini MG, Rajfer J, et al. Fibrin as an inducer of fibrosis in the tunica albuginea of the rat: a new animal model of Peyronie's disease. *BJU Int.* 2003;91(9):830–838.
- Devine CJ, Somers KD, Jordan SG, et al. Proposal: trauma as the cause of the Peyronie's lesion. *J Urol.* 1997;157(1):285–290.
- Somers KD, Dawson DM. Fibrin deposition in Peyronie's disease plaque. *J Urol.* 1997;157(1):311–315.
- Hauck EW, Diemer T, Schmelz HU, et al. A critical analysis of nonsurgical treatment of Peyronie's disease. *Eur Urol.* 2006;49(6):987–997.
- Devine CJ, Somers KD, Ladaga LE. Peyronie's disease: pathophysiology. *Prog Clin Biol Res.* 1991;370:355–358.
- Pierce GF, Van de Berg J, Rudolph R, et al. Platelet-derived growth factor-B and transforming growth factor beta 1 selectively modulate glycosaminoglycans, collagen, and myofibroblasts in excisional wounds. *Am J Pathol.* 1991;138(3):629–646.
- Anafarta K, Beduk Y, Uluoglu O, et al. The significance of histopathological changes of the normal tunica albuginea in Peyronie's disease. *Int Urol Nephrol.* 1994;26(1):71–77.
- Sidoti PA, Belmonte SJ, Liebmann JM, et al. Trabeculectomy with mitomycin C in the treatment of pediatric glaucoma. *Am Acad Ophthalmol.* 2000;20:422–428.
- Beckers HJ, Kinders KC, Webers CA. Five-year results of trabeculectomy with mitomycin C. *Graefes Arch Clin Exp Ophthalmol.* 2003;241(2):106–110.
- Mazdak H, Meshki I, Ghassami F. Effect of Mitomycin C on Anterior Urethral Stricture Recurrence after Internal Urethrotomy. *Eur Urol.* 2007;51(4):1089–1092.
- Schwartz EJ, Wong P, Graydon RJ. Sildenafil preserves intracorporeal smooth muscle after radical retropubic prostatectomy. *J Urol.* 2004;171(2 Pt 1):771–774.
- Russell S, Steers W, McVary K. Systematic Evidence-Based Analysis of Plaque Injection Therapy for Peyronie's Disease. *Eur Urol.* 2007;51(3):640–647.
- Markou S, Perimenis P, Gyftopoulos K, et al. Vardenafil (Levitra) for erectile dysfunction: a systematic review and meta-analysis of clinical trial reports. *Int J Impot Res.* 2004;16(6):470–478.
- Hinman F. Etiologic factors in Peyronie's disease. *Urol Int.* 1980;35(6):407–413.
- Bradbury P, Gordon KC. Connective tissues and stains. In: Bancroft JD & Stevens A et al., editors, *Theory and practice of histological techniques.* (3rd edn), Churchill Livingstone, UK, 1990. p. 133(119–142).
- Brander WT. Mitomycin C: a clinical update. *Cancer Treat Rev.* 2001;27(1):35–50.
- Heran MK, Baird R, Blair GK, et al. Topical mitomycin-C for recalcitrant esophageal strictures: a novel endoscopic/fluoroscopic technique for safe endoluminal delivery. *J pediatr surg.* 2008;43(5):815–818.