

Pelvi Neurofibroma Extrinsic Compression of Bladder

Abstract

Solitary neurofibroma occurs only in peripheral nerves. Pelvic Neurofibroma is one of the rare cases; we are reporting an encapsulated mass in the retroperitoneum on the right side causing extrinsic compression of the bladder.

Keywords: Pelvic neurofibroma; Extrinsic compression of bladder; Solitary neurofibroma

Case Report

Volume 3 Issue 4 - 2016

Parikshith S^{1*} and Govindharaaju S²

¹Postgraduate department of urology, Chettinad health city, India

²Department of urology, Chettinad health city, India

***Corresponding author:** Parikshith S, Postgraduate department of urology, Chettinad health city, Kelambakkam, Kanchipuram, Tamilnadu, India, Email: paridoctor@gmail.com

Received: August 10, 2016 | **Published:** August 25, 2016

Introduction

Pelvic Neurofibroma is a very rare entity, so far approximately 60 cases reported [1]. Usually Neurofibroma arise from the pelvic organs, but in this case tumor was not involved any pelvic organ [2]. According to World Health Organization, it is an encapsulated nerve sheath tumor and common peripheral nerve tumors. About 10% are linked up with genetic neurofibromatosis type I (NF1). Neurofibroma without NF1 often described as slow growing, benign and painless tumor [3]. In NF1 associated Neurofibroma are found with other diseases like skin discoloration, skin tags or small cutaneous tumor, Lisch nodules of the iris and central nervous system tumors such as acoustic neurilemoma or tumors arise from nerve roots of the spinal column. Patients with NF1 associated with 15% of malignant risk factors [4]. Localized Neurofibroma with NF1 usually seen in childhood and adolescence age. Multiple lesions usually seen along the deep and long nerve sheath [5].

Case Report

30 years old gentleman arrived with complaints of lower abdominal discomfort for 6 months with vague right iliac pain with normal gut and bladder habits. He experienced no other co-morbidities. Clinical examination findings were normal. Blood investigation was done within normal limits. Ultrasound abdomen showed a complex cyst with internal echoes and absence of vascularity in the right side of the pelvis. Contrast CT abdomen revealed non enhancing unilocular cystic mass on the right lateral pelvic wall. MRI, abdomen with gadolinium revealed T1 hypotense, T2/STIR heterointense enhancement within the lesion. Colonoscopy was normal.

He underwent laparotomy under general anesthesia, through Pfannenstiel extra peritoneal approach mass lesion of size 8cm x 6 cm identified in the right pelvic region in the course of obturator nerve producing the compression over the lateral wall of the bladder without any infiltration of the bladder and bowel. It was arising from the nerve bundle, the lesion was well capsulated. It was highly vascular with blood supply from the branches of internal iliac arteries. The feeding arterial branch was ligated, outer capsule opened and an inner mass removed completely after leaving the capsule intact in view of nerve injury. Haemostasis achieved, postoperative period was uneventful. Histopathology revealed a mass of size 8x6.5x3.5cm section shows unencapsulated lesion comprised of spindle cells with wavy nuclei prominent myxoid stroma and scant collagen, conclusive of as Neurofibroma.

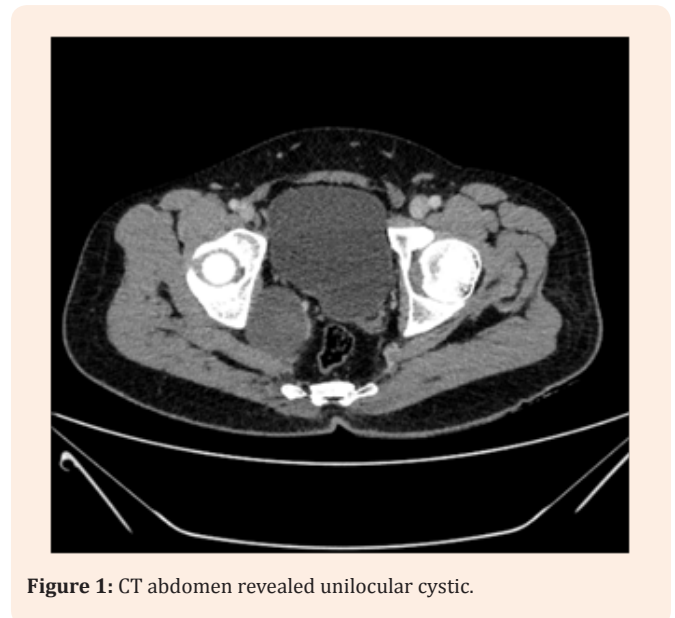


Figure 1: CT abdomen revealed unilocular cystic.

Discussion

Neurofibroma is classified into two groups; first group is the solitary tumor or a non NF1 neurofibroma which is not associated with other tumors. Solitary Neurofibroma commonly occurs in female and occurs on the right side of the body. It occurs in later ages than NF1 associated Neurofibroma. Second group of Neurofibroma is the plexiform Neurofibroma seen exclusively in conjunction with NF1. It has equal distribution in both the sides of the body and in sexes. In this study, Neurofibroma of pelvic origin producing extrinsic compression without any manifestation or involvement of Neurofibromatosis lesion. Only very less number of cases as has been reported without any malignant transformation. Narayana Pradeep et al. [6] reported as a case of Neurofibroma involving phrenic nerve without any other neurofibromatosis lesion involvement.

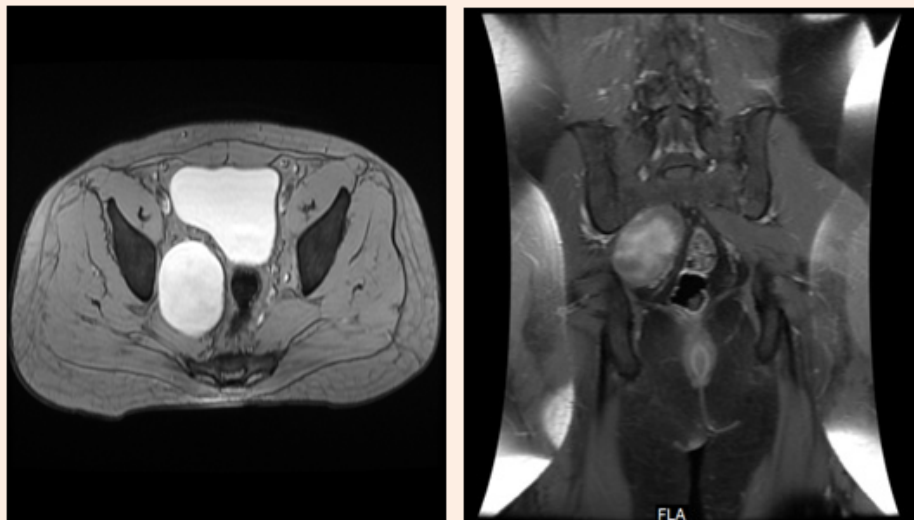

Figure 2 & 3: MRI, abdomen with gadolinium revealed T1 hypotense, T2/STIR heterointense enhancement within the lesion.

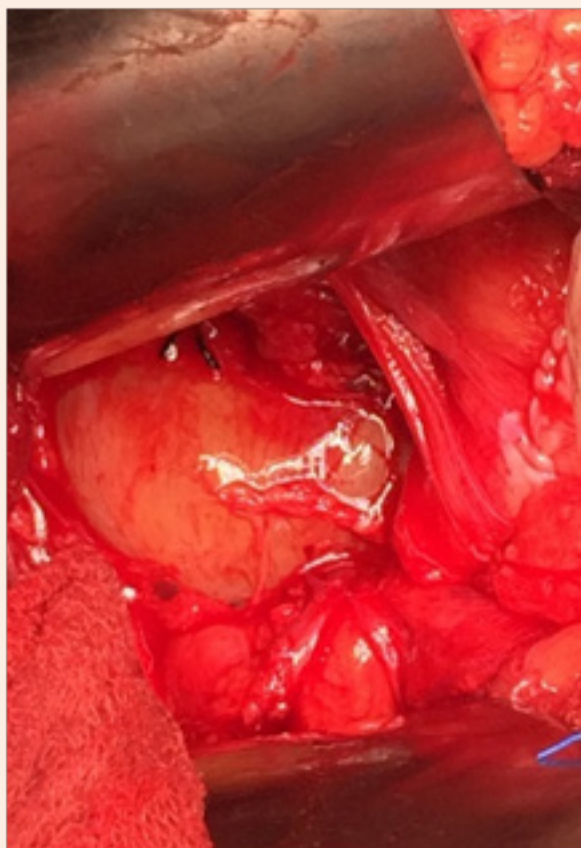


Figure 4: Shows intraoperative picture of mass with increased vascular supply.

Conclusion

Pelvic neurofibroma is the rare entity, usually associated with other organs; but unusual presentation may also present (not involving any pelvic organs). Surgical management is the only treatment available for compression symptoms or that Neurofibroma undergone malignant transformation.

References

1. Jana M, Gamanagatti S, Kumar R, Aggarwala S (2011) Pelvic neurofibroma arising from prostate in a case of neurofibromatosis-1. *Indian J Urol* 27(3): 415-417.
2. Bakhshi GD, Tayade MB, Yadav RB, Jadhav KV, Shenoy SS, et al. (2014) Pelvic neurofibroma. *Clinics Pract Clinics and Practice* 4(3): 660.
3. Bernthal NM, Jones KB, Monument MJ, Liu T, Viskochil D, et al. (2013) Lost in Translation: Ambiguity in Nerve Sheath Tumor Nomenclature and Its Resultant Treatment Effect. *Cancers* 5(2): 519-528.
4. Tumors of the peripheral nerve. In: Winn HR (Ed.) *Youmans neurological Surgery*, pp. 2521.
5. Patel NB, Stacy GS (2012) Musculoskeletal Manifestations of Neurofibromatosis Type 1. *AJR Am J Roentgenol* 199(1): W99-106.
6. Pradeepa NM, Kudri GM, Janne MS, Ashok AH (2012) Neurofibroma Arising from Phrenic Nerve. *Chest Dis Allied Sci* 54: 263-264.