

Bleomycin: An effective drug for intralesional injection treatment of vascular anomalies

Keywords: bleomycin, vascular anomaly, hemangioma, venous malformation, lymphatic malformation, sclerosing therapy

Introduction

Vascular anomalies are one of the challenging disease regarding management, which are presented in different age groups and different clinical courses. In 1982, Mulliken and Glowacki proposed a binary classification of vascular anomalies corresponding to endothelial characteristics.¹ In 1996, The International Society for the Study of Vascular Anomalies (ISSVA) adopted this model for classification scheme.² The update classification (2018) incorporating genetic and pathologic characterization of these diseases can be searched online (<http://www.issva.org/classification>) with links to the other associated clinical parameters including causative mutations.³ Bases on biological differences and natural behavior, vascular anomaly are categorized into two major groups which are tumors and malformations.¹⁻⁴

Infantile hemangiomas are the most common vascular tumors of infancy and childhood, particularly in girls, characterized by a growth phase with increased endothelial turnover and then to a stable plateau phase followed by an involuted phase.¹⁻⁴ Although most hemangiomas resolve spontaneously, certain indications call for active management are lesions at eyelid, orbit, tip of nose, oral cavity, subglottic or glottic locations, particularly in lesions associated with cardiac overload or coagulation disorder.⁵ Vascular malformations are the result of defective vessel remodeling without evidence of cellular proliferation. They are subdivided according to the predominant channel type as capillary malformation, arteriovenous malformation, venous malformation, lymphatic malformation and complex forms. Malformations with an arterial component are fast flow, the remainders are low flow in nature.¹⁻⁴

Recently, intralesional bleomycin injection has been proved its effectiveness as the initial treatment of hemangiomas and low flow vascular malformations (venous and lymphatic malformations), which are obviating the indication of primary surgery or systemic medical regimens.⁶⁻¹⁰ In our experience, bleomycin is the best choice, as compared to other sclerosing agents, due to its availability, low cost, good response, fast recovery and minimal side effects (Figure 1-6). It shows a dramatic response particularly with macrocystic type of lymphatic malformations (Figure 7). Bleomycin is a natural product in the family of glycopeptide antibiotics obtained from *Streptomyces verticillus*.¹¹ It was discovered and developed as a antitumour agent by Umezawa in 1966.¹² Bleomycin intercalates with DNA, in the presence of a redox reaction resulting to free radical releasing and subsequently induce DNA degradation.^{11,13} It has no effect of marrow toxicity and thrombocytopenia. Thus, it can be used in combination chemotherapy in patients with lymphoma, testicular tumors, and squamous cell carcinoma.^{4,14}

In addition to its antineoplastic activity, bleomycin was found to have a local sclerosing effect on vascular endothelium with nonspecific inflammatory reaction and occlusion of vessels.⁶⁻¹⁰ It was first therapeutically used bleomycin solution as a sclerosing agent for

Volume 8 Issue 1 - 2020

Anchalee Churojana

Associate Professor, Mahidol University, Thailand

Correspondence: Anchalee Churojana, M.D, Siriraj Center of Interventional Radiology, Siriraj Hospital, Mahidol University, Bangkok, Thailand, Email achurojan@gmail.com

Received: January 02, 2020 | **Published:** February 10, 2020

cystic hygroma by Jura et al with good outcome in 1977.¹⁵ After that, it came more studies and publications worldwide, with similar success, which was initially in Japan, then in Australia, Turkey, Sweden, China, South Africa and other countries.^{6-10,15-19} In our center, the procedures have been performed by local or sedative anesthesia, if the lesions are small or superficial location. However, for deep lesions of head and neck, particularly those which affect airway, the procedure must be performed under general anesthesia.

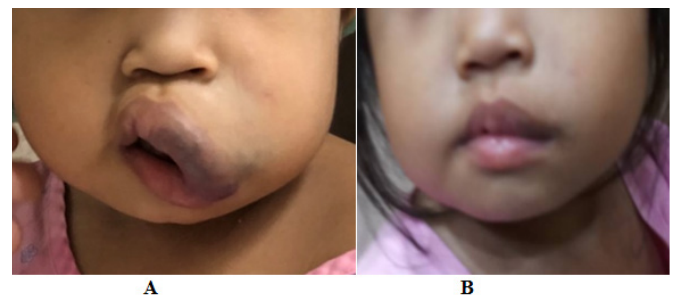

Figure 1 (A), A 2-year-old girl with venous malformation at left upper lip; (B), Post intralesional bleomycin injection (IBI) for 2 times with total accumulation dose at 22.5 mg.

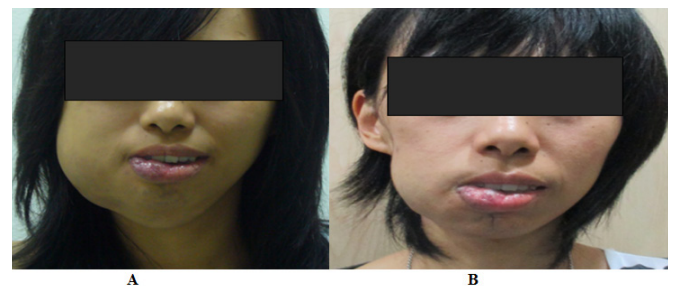


Figure 2 (A), Left facial venous malformation in a 17-year-old female; (B), Result after 11 sessions of IBI with 165 mg accumulation dose.

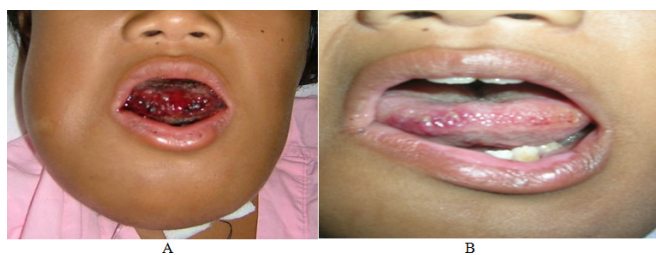

Figure 3 (A), A 5-year-old girl with venolymphatic malformation of tongue, presenting with pain and bleeding, status post partial glossectomy for a year; (B) Response after single IBI at 15 mg.

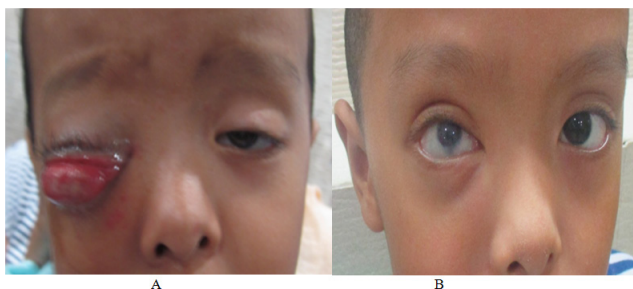


Figure 4 (A), A 3-year-old boy presenting with infection and inflammation of venous malformation at right upper eyelid causing blood tears; (B), Result from 3 sessions of IBI with 34 mg accumulation dose, after infection control. However, diminished right vision acuity from severe infection.

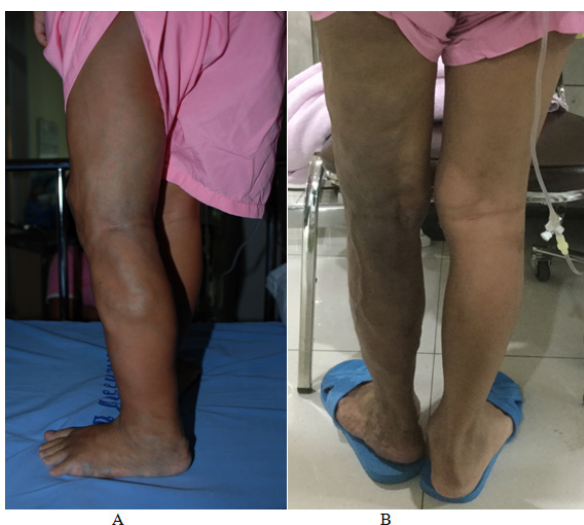


Figure 5 (A), A 3-year-old boy presenting with venous malformation of left leg since birth; (B), Result of IBI, 13 sessions with 182 mg accumulation dose during 9 years period.

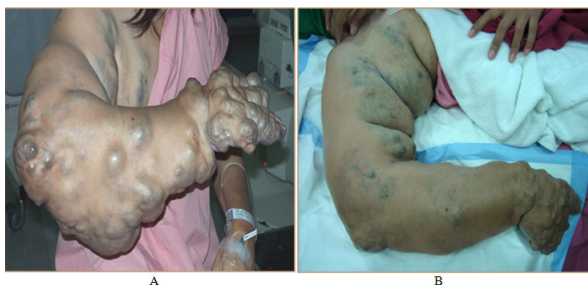

Figure 6 (A), A 40-year-old female with huge venous malformation involving right upper extremity and chest wall; (B), Outcome after 11 sessions of IBI with accumulation dose at 165 mg.

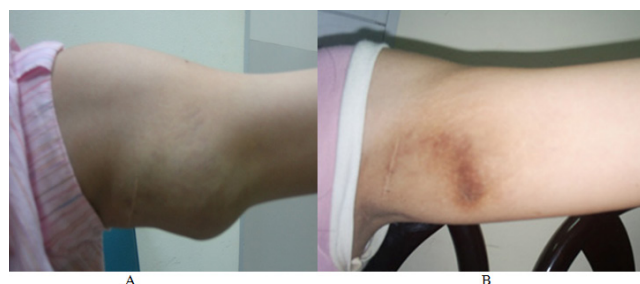

Figure 7 (A), A 20-year-old female with macrocystic lymphatic malformation, presenting with recurrence after surgery and several times of fluid aspiration; (B), Follow up at 3-month period after single IBI at 15 mg, showing complete cure. Note hyperpigmentation at periphery of the pre-existing lesion.

Percutaneously puncture is accomplished by using a 20 to 22 gauge Teflon-sheath needle canula through a normal skin. Once venous blood or lymphatic fluid is freely aspirated, venography is performed to estimate volume of the lesion and to access the anatomy of venous drainage. Manual compression of venous outlet or venous pressure tourniquet will be applied during maneuver, if systemic venous connection with the lesion is identified on venography, and it will be maintained for at least 10 minute after finishing to prolonged contact of bleomycin with endothelial surface and to minimize systemic contamination.

Bleomycin is mixed at the dilution of 1mg/ml by normal saline. Contrast medium is injected under roadmap fluoroscope, to visualize the malformation spaces. Then bleomycin solution is slowly infused, until the previously injected contrast agent is displaced to fill up the entire cavity or spillage into venous outlets. The amount of each injection varies according to the size of the lesion. For lymphatic malformations, before stepping of venography, the lymph fluid should be aspirated as much as possible with the aim to minimize dilution effect. Multiple punctures may be required in the same session, if the lesion contains several non-communicating cavities.

In children under 1 year of age, the maximum dose per injection was limited to 1mg/kg. Patients who were older than 1 year of age, a single dose of 15 mg was never exceed. For the large lesion, the volume can be expanded upto 45ml in the form of bleomycin foam preparation.²⁰ We use the solution of 15mg bleomycin in 7.5ml saline with the mixture of 7.5ml of 25% human serum albumin and 30ml of room air. Repeated intralesional bleomycin injection can be obtained in 6-8 weeks for the large or the remaining lesions which is re-evaluated at 4-week follow up period.

Although bleomycin has relatively low toxicity but one must keep in mind of its risk of pulmonary fibrosis. A review of 808 patients with a cumulative administered systemic bleomycin by Muir et al reveals that pulmonary toxicity is dose dependent. When total dose is more than 550 mg the incidence of pulmonary fibrosis is 17%, total dose at 450-550mg, the incidence is 13%, with a low risk below this level.² Thus, the accumulation dose of bleomycin should not be exceed 450mg. In our experiences, the complications of intralesional bleomycin injection are mostly related to localized reactions, such as local swelling, redness, pain. It is interested that skin hyperpigmentation, which can present at the injection site or remote region, is also found upto 16% (Figure 8,9). The other minor complications are low-grade fever or flu-like symptom. No pulmonary toxicity or any serious complications have occurred.

In conclusion, bleomycin is a safe with cost-effectiveness drug,

as a sclerosing agent for intralesional injection treatment of venous malformations, macrocystic type of lymphatic malformations and infantile hemangioma.

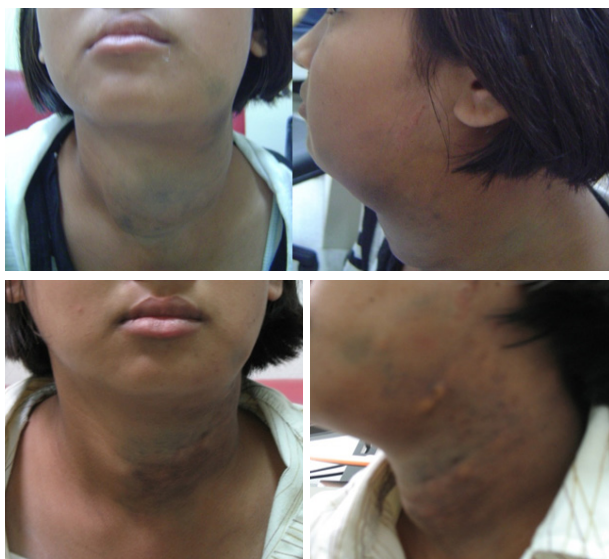

Figure 8 (A), Frontal and lateral views of a 18-year-old female with venous malformation at soft tissue of neck; (B) Result after 6 sessions of IBI with total accumulation dose at 90 mg. Note the small subcutaneous nodules which are pre-existing phelboliths that became visible after resolution of the malformation, and skin hyperpigmentation.

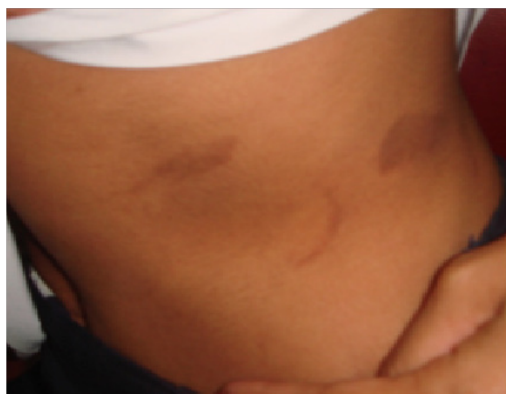

Figure 9 Several skin hyperpigmentation at abdominal wall and back, a minor complication after successful IBI at facial area (not shown).

Acknowledgments

None.

Conflicts of interest

Author declares that there is no conflict of interest.

References

1. Mulliken JB, Glowacki J. Hemangiomas and vascular malformations in infants and children: a classification based on endothelial characteristics. *Plast Reconstr Surg*. 1982;69(3):412–422.

2. Steiner JE, Drolet BA. Classification of vascular anomalies: an update. *Semin Intervent Radiol*. 2017;34(3):225–232.
3. 2018 ISSVA Classification of Vascular Anomalies ©. International Society for the Study of Vascular Anomalies; 2018. 20 p.
4. Kollipara R, Dinneen L, Rentas KE, et al. Current classification and terminology of pediatric Vascular Anomalies. *AJR*. 2013;201(5):1124–1135.
5. Lasjaunias P. *Vascular diseases in infants, neonates and children*. 1st ed. New York: Springer-Verlag Berlin Heidelberg; 1997.
6. Muir T, Kirsten M, Fourie P, et al. Intralesional bleomycin injection (IBI) treatment for haemangiomas and congenital vascular malformations. *Pediatr Surg Int*. 2004;19(12):766–773.
7. Mathur NN, Rana I, Bothra R, et al. Bleomycin sclerotherapy in congenital lymphatic and vascular malformations of head and neck. *Int J Pediatr Otorhinolaryngol*. 2005;69(1):75–80.
8. Sung MW, Chang SO, Choi JH, et al. Bleomycin sclerotherapy in patients with congenital lymphatic malformation in the head and neck. *Am J Otolaryngol*. 1995;16(4):236–241.
9. Redkar RG, Chigicherla S, Joshi S, et al. Efficacy of intralesional bleomycin as an alternative approach in the management of vascular anomalies. *Saudi Surg J*. 2017;5(2):60–65.
10. Lee HJ, Kim TW, Kim JM, et al. Percutaneous sclerotherapy using bleomycin for the treatment of vascular malformations. *Int J Dermatol*. 2017;56(11):1186–1191.
11. Palwai VR, Eriksson. Molecular dynamics simulations exploring the interaction between DNA and metalated bleomycin. *Journal of Biophysical Chemistry*. 2011;2(2):170–182.
12. Umezawa H, Maeda K, Takeuchi T, et al. New antibiotics, bleomycin A and B. *J Antibiot*. 1966;19(5):200–209.
13. Lopez-Larraz D, De Luca JC, Bianchi NO. The kinetics of DNA damage by bleomycin in mammalian cells. *Mutation Res*. 1990;232(1):57–61.
14. Blum RH, Carter SK, Agre K. A clinical review of bleomycin—a new antineoplastic agent. *Cancer*. 1973;31(4):903–914.
15. Yura J, Hashimoto T, Tsuruga N, et al. Bleomycin treatment for cystic hygroma in children. *Nihon Geka Hokan*. 1977;46(5):607–614.
16. Tanigawa N. Treatment of cystic hygroma and lymphangioma with the use of bleomycin fat emulsion. *Cancer*. 1987;60(4):741–749.
17. Okada A, Kubota A, Fukuzawa M, et al. Injection of bleomycin as a primary therapy of cystic lymphangioma. *J Pediatr Surg*. 1992;27(4):440–443.
18. Sarihan H, Mocan H, Yildiz K, et al. A new treatment with bleomycin for complicated cutaneous hemangioma in children. *Eur J Ped Surg*. 1997;7(3):158–162.
19. Saha AK, Haque SS, Islam KM. Effect of intralesional bleomycin as an alternative therapy for cystic hygroma. *Bangladesh Med J Khulna*. 2013;46(1-2):12–15.
20. Haq FUI, Mitchell SE, Tekes A, et al. Bleomycin foam treatment of venous malformations: a promising agent for effective treatment with minimal swelling. *J Vasc Interv Radiol*. 2015;26(10):1484–1493.