

# Laparoendoscopic single-site cystectomy in pregnancy for a benign mullerian serous cystadenofibroma: a case report with review of literature

## Abstract

**Background:** The incidence of adnexal masses in pregnancy is estimated to be 2%. Surgical intervention is required, particularly in the setting of potential malignancy, ovarian torsion, or direct mass affect on the pregnancy. Single incision laparoscopic surgery (SILS) averts the potential morbidity of multiple trocar insertions as it is associated with less bleeding, pain and better cosmetics and tissue retrieval. We describe the use of SILS technique in a 16 5/7-week pregnancy complicated by a 20cm left adnexal cystic mass that was managed with a single-incision laparoscopic left salpingectomy with cystectomy.

**Case:** The patient was a 24 year old, pregnant, Gravida 2 Para 0010 with gestational diabetes and morbid obesity (Body-Mass Index of 42.18). Her only pregnancy ended as a spontaneous abortion. She initially presented to our clinic at 15 3/7 weeks for further evaluation of a large, 19.0 x 15.8 x 9.0cm maternal abdominal cystic mass, which had been detected on prenatal ultrasound. She was managed by Single-Incision diagnostic laparoscopy and Single-incision laparoscopic left salpingectomy and left paratubal cystectomy at 16 5/7 weeks. Pathologic examination of the paratubal cyst revealed the mass to be a benign mullerian serous cystadenofibroma. Her recovery was uncomplicated, with discharge on the first postoperative day.

**Conclusion:** In summary, removal of this patient's adnexal mass in pregnancy was warranted to avert potential complications. The patient's paratubal cyst was drained without leakage and then removed intact through the umbilical incision. Single incision laparoscopic cystectomy for large ovarian and paratubal cysts in pregnancy is not only feasible, but has also been shown to result in better outcomes. There were no complications in this patient intraoperatively, postoperatively, or in a subsequent pregnancy.

**Keywords:** adnexal mass, cystectomy, paratubal cyst, pregnancy, salpingectomy, SILS cystectomy, single-incision laparoscopic surgery

Volume 9 Issue 4 - 2018

Shadi Rezaei,<sup>1,5</sup> Alexander C Hughes,<sup>2</sup> Emily Wang,<sup>2</sup> Ninad M Patil,<sup>3</sup> Elise Bardawil,<sup>5</sup> Cassandra E Henderson,<sup>4</sup> Xiaoming Guan<sup>5</sup>

<sup>1</sup>Department of Obstetrics and Gynecology, Southern California Kaiser Permanente, USA

<sup>2</sup>St. George's University, School of Medicine, St. George's, Grenada

<sup>3</sup>Department of Pathology & Immunology, Baylor College of Medicine, USA

<sup>4</sup>Maternal and Fetal Medicine, Department of Obstetrics and Gynecology, Lincoln Medical and Mental Health Center, USA

<sup>5</sup>Division of Minimally Invasive Gynecologic Surgery, Department of Obstetrics and Gynecology, Baylor College of Medicine, USA

**Correspondence:** Xiaoming Guan MD PhD, Section Chief and Fellowship Director, Division of Minimally Invasive Gynecologic Surgery, Department of Obstetrics and Gynecology, Baylor College of Medicine, 6651 Main Street, 10th Floor, Houston, Texas, 77030, USA, Tel (832) 826-7464, Fax (832) 825-9349, Email xiaoming@bcm.edu

**Received:** May 12, 2018 | **Published:** July 06, 2018

## Background

The incidence of adnexal masses in pregnancy is estimated at approximately 2%.<sup>1</sup> Most adnexal masses resolve spontaneously by the second trimester without needing intervention, as long as there is a low risk for malignancy or complications, such as ovarian torsion.<sup>2</sup> However, surgical intervention is indicated in cases of acute abdomen, hydronephrosis, risk of dystocia, and malignancy.<sup>3</sup>

Adnexal masses are radiologically classified as simple or complex, and each category includes both benign and malignant neoplasms. Among adnexal masses in pregnant women, 1% of simple masses, and 9% of the complex masses are found to be malignant.<sup>4</sup> Most adnexal masses in pregnancy are simple functional cysts less than 5 cm in diameter and therefore resolve without intervention by the second trimester.<sup>1</sup>

However, if the mass is symptomatic or large (usually greater than 10cm) surgery is recommended due to the risk of major complications otherwise aspiration may be considered.<sup>1</sup> Complications of adnexal masses in pregnancy include adnexal torsion, rupture, malignancy, abortion, and preterm delivery.<sup>3</sup> Traditionally, adnexal masses in pregnancy were managed by laparotomy, but recently, studies have shown that laparoscopy during any trimester is safe and feasible

although surgery is recommended in the second trimester.<sup>5,6</sup> In contrast to laparotomy, laparoscopic surgery is associated with faster recovery, less pain, and a shorter hospital stay.<sup>2</sup>

Single incision laparoscopic surgery (SILS) averts the potential morbidity of multiple trocar insertions as well as being associated with less bleeding and pain, as well as improved cosmetic outcomes and tissue retrieval.<sup>5,7,8</sup> We describe the case of a pregnant woman with a 20cm adnexal mass who underwent a SILS salpingectomy and cystectomy at 16 weeks and 5 days gestation.

## Presentation of the case

The patient was a 24 year old, pregnant, Gravida 2, Para 0010, with gestational diabetes and morbid obesity (BMI of 42.18kg/m<sup>2</sup>). She had history of a spontaneous abortion. She presented to our clinic at 15 weeks and 3 days gestation for further evaluation of a large maternal abdominal cystic mass incidentally detected on routine prenatal ultrasound. She denied gastrointestinal symptoms or abdominal pain. Her diabetes was controlled by dietary and lifestyle modifications under medical care with the support of a dietician.

Pelvic ultrasound revealed a large unilocular cyst slightly to the right of midline measuring 19.0 x 15.8 x 9.0cm. The cyst was superior

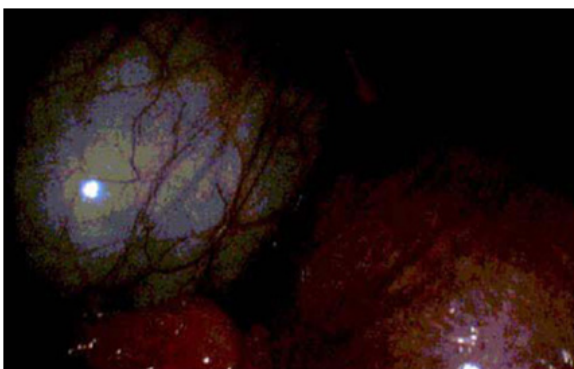
to the uterus and displayed no color flow on Doppler imaging. The right ovary was not visualized, and the ultrasound could not conclusively delineate the origin of the cyst, possibilities being ovary, mesentery or pancreas.

The patient was counseled that the best course of treatment is removal of the cyst in the second trimester due to the cyst's size and lack of flow. At 16 weeks and 5 days of gestation, the patient underwent a single-incision diagnostic laparoscopy and a single-incision laparoscopic salpingectomy with left paratubal cystectomy.

### SILS technique

Under general endotracheal anesthesia and in dorsal lithotomy position, a 15mm skin incision was made in the umbilicus, and the incision was carried down in layers until the abdominal cavity was entered. A GelPOINT mini advanced access single-site laparoscopy device was inserted into the incision. Carbon dioxide was used to insufflate the abdominal cavity with careful attention paid to intraabdominal pressure.

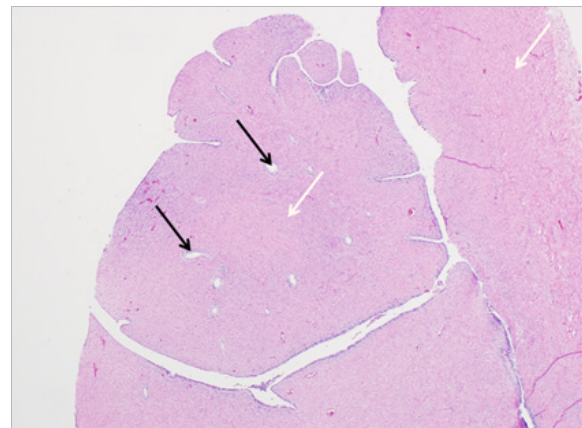
Upon visualization of the abdomen a 16 week gravid uterus was observed with a large unilocular left paratubal cyst (Figure 1). The left fallopian tube was extremely distended around due to the cyst, and the left ovary was not visualized. The right fallopian tube and ovary appeared grossly normal. A laparoscopic needle aspirator was introduced into the cyst under direct visualization and the cyst contents were aspirated. When approximately half the cyst contents had been aspirated, the articulating Enseal was used to expand the small puncture site allowing for continued aspiration with the laparoscopic suction-irrigator. Once the cyst was decompressed, the fallopian tube was transected near the cornu of the uterus with the articulating Enseal. An incision was carried along the mesosalpinx until the entire fallopian tube was detached. Excellent hemostasis was noted and area was examined. The left ovary appeared viable after the procedure, and no additional cyst was seen. There was approximately 50ml of blood loss, 1200ml intravenous fluids administered, and 100ml of urine output.



**Figure 1** Intraoperative image, showing a large, unilocular, clear left paratubal cyst. The cyst is superior to the 16 week gravid uterus.

The cyst specimen was removed and sent to pathology, which revealed a thick-walled cyst, with occasional branching solid papillae along its inner lining. The wall of the cyst showed prominent fibromatous stroma and the epithelium was benign, of serous-type. The papillae also contained benign serous epithelial inclusions surrounded by prominent fibromatous stroma. The pathologic diagnosis was consistent with a benign müllerian serous cystadenofibroma (Figure 2).

A postoperative bedside ultrasound confirmed a detectable fetal heart beat. The patient had an uncomplicated recovery course and was discharged from the hospital on the day after surgery. At the 3-week postoperative follow-up, the patient was doing well, with no complaints. At 38 weeks gestation the patient underwent primary low transverse cesarean delivery due to obstetric indications. Both mother and the baby had an uncomplicated hospital stay and postpartum course. Another pregnancy, 2 years later, was also noted to be uncomplicated with no recurrence of the cyst.



**Figure 2** Pathologic examination showed a serous cystadenofibroma, comprised of a cyst with occasional branching solid papillae, lined by benign serous epithelium. Serous inclusions (black arrows) are seen in the solid papillae. Prominent fibromatous stroma (white arrows) is seen around the cyst wall as well as in the solid papillae. (H&E stain).

### Discussions

Pelvic masses affect both pregnant and non-pregnant women alike at similar rates. Management during pregnancy involves either surgical intervention or observation, depending on clinical presentation. Observation carries the risk of allowing for malignant transformation or torsion. Surgery and anesthesia have their own risks to the mother and the fetus. A review of literature indicates that there are no universally agreed upon guidelines for the treatment of adnexal masses during pregnancy.

Traditionally, pelvic masses were removed via laparotomy with a midline incision<sup>8</sup> but with advances in minimally invasive surgical techniques laparoscopic surgery has become the standard of care. Some surgeons are hesitant to perform endoscopic surgery during pregnancy due to concerns such as poor surgical visualization, effects of CO<sub>2</sub> insufflation and iatrogenic trocar injury.<sup>8,2,3</sup> Many studies have shown endoscopic surgery to be safe and effective during pregnancy. Laparoscopic surgery in pregnancy is accepted to have lower rates of premature labor and shorter hospital stays compared to laparotomy.<sup>8,9,10</sup>

As mentioned above, the second trimester is the optimal time for surgery during pregnancy. The uterus is still contained within the pelvis and the second trimester has been shown to have the lowest rate of premature labor.<sup>2,6</sup> Surgery is best for adnexal masses during pregnancy not only for the non-gravid reasons such as torsion, but also because of the malignant potential of some of these masses.<sup>8</sup> Unfortunately, conservative management may result in the need for emergency surgery which is associated with higher incidence of negative outcomes as compared to planned surgery in the second trimester.<sup>11</sup>

SILS in pregnancy is being performed more commonly. As with a non-pregnant patient, the entire procedure involves a small skin incision in the umbilicus through which all instruments are introduced. This method is believed to prevent injury to an enlarged uterus from insufflation needle or trocar. By entering the pelvis through the umbilicus, the surgeon is able to visualize adnexal ligaments, especially because the uterus will overstretch these structures during pregnancy.<sup>12</sup>

Studies show that in contrast to a traditional laparoscopic approach, SILS has improved cosmetic results from fewer trocar incisions, lesser postoperative pain, and reduced need for narcotic use.<sup>2,12,13</sup> SILS has also been reported to have a lower incidence of hernia formation than other forms of endoscopic surgery.<sup>2</sup>

A majority of smaller (less than 5cm) adnexal masses will resolve spontaneously and many by the second trimester.<sup>11</sup> However, when surgery is necessary the least invasive approach should be used. Some surgeons have reservations about performing endoscopic surgery during pregnancy, as there is fear of trocar injury to the uterus especially as gestation progresses. With SILS there is only one site of entry reducing this risk. Additionally, the peritoneum is entered in an open fashion rather than blind insertion of trocars, further minimizing the risk of injury to intraabdominal structures.

One drawback of SILS as compared to multi-port laparoscopy in pregnancy is limited scope for uterine manipulation. Not only is the gravid uterus larger than a non-gravid uterus taking up abdominal space but a uterine manipulator cannot be inserted. In traditional laparoscopic surgery, the uterus can be pulled out away from the field of view but with SILS the uterus must be pushed atraumatically from behind through the surgical field of view. This difference can still be overcome by surgeons with experience and should be a consideration.

## Conclusion

In summary, the patient's paratubal cystic mass was drained without leakage and then removed intact through the umbilical incision. Single incision laparoscopic cystectomy for large ovarian and paratubal cysts in pregnancy is not only feasible, but also leads to better outcomes.<sup>7</sup> There were no complications intraoperatively, postoperatively, or in a subsequent pregnancy.

Adnexal masses are often incidentally detected in pregnancy due to routine use of ultrasound. Most masses resolve spontaneously, but some may be malignant or cause adverse outcome. Based on ultrasound features and the development of symptoms, surgery should be considered. For experienced surgeons, studies have shown that SILS appears to be a safer alternative to laparotomy.

## Acknowledgments

Dr. Xiaoming Guan is a speaker for Applied Medical, Rancho Santa Margarita, and California.

## Conflicts of interest

Authors did not report any potential conflicts of interests.

## References

1. Lee JH, Lee JR, Jee BC, et al. Safety and feasibility of a single-port laparoscopic adnexal surgery during pregnancy. *J Minim Invasive Gynecol.* 2013;20(6):864–70.
2. Scheib SA, Jones HH, Boruta DM, et al. Laparoendoscopic single-site surgery for management of adnexal masses in pregnancy: case series. *J Minim Invasive Gynecol.* 2013;20(5):701–7.
3. Cavaco-Gomes J, Jorge Moreira C, Rocha A, et al. Investigation and Management of Adnexal Masses in Pregnancy. *Scientifica (Cairo).* 2016;2016:3012802.
4. Runowicz CD, Brewer M. *Adnexal mass in pregnancy.* In: Goff B, Falk SJ, editors. UpToDate Inc; 2016.
5. Fader AN, Levinson KL, Gunderson CC, et al. Laparoendoscopic single-site surgery in gynecology: A new frontier in minimally invasive surgery. *J Minim Access Surg.* 2011;7(1):71–7.
6. American College of Obstetricians and Gynecologists. Practice Bulletin No. 174: Evaluation and Management of Adnexal Masses. *Obstet Gynecol.* 2016;128(5):e210–e226.
7. Zhang Y, Blazek K, Guan X. Single-Incision Laparoscopic Ovarian Cystectomy in a 26 Weeks Pregnancy Patient with 17 cm Cyst, Video Session 6 – Single-Port Laparoscopy, Video Number 257. *J Minim Invasive Gynecol.* 2017;24(7):S93–S94.
8. Balthazar U, Steiner AZ, Boggess JF, et al. Management of a persistent adnexal mass in pregnancy: what is the ideal surgical approach?. *J Minim Invasive Gynecol.* 2011;18(6):720–5.
9. Duncan RP, Shah MM. Laparoscopic salpingectomy for isolated fallopian tube torsion in the third trimester. *Case Rep Obstet Gynecol.* 2012;239352.
10. Walsh CA, Tang T, Walsh SR. Laparoscopic versus open appendectomy in pregnancy: a systematic review. *Int J Surg.* 2008;6(4):339–44.
11. Schmeler KM, Mayo-Smith WW, Peipert JF, et al. Adnexal masses in pregnancy: surgery compared with observation. *Obstet Gynecol.* 2005;105(5 Pt 1):1098–103.
12. Al-Badawi IA, Alshankiti H, Ahmad S. Single Incision Laparoscopic Surgery in Pregnancy. *CRSLS MIS Case Reports from SLS.org.* 2014.
13. Escobar PF, Fader AN, Paraiso MF, et al. Robotic-assisted laparoendoscopic single-site surgery in gynecology: initial report and technique. *J Minim Invasive Gynecol.* 2009;16(5):589–91.