

# Iatrogenic endometriosis after laparoscopic hysterectomy with vaginal power morcellation: a case report

## Abstract

New-onset endometriosis is a very rare complication after a laparoscopic hysterectomy. The use of power morcellation systems may contribute to the development of this condition associated with the spread of endometrial tissue in the peritoneal cavity. We report the case of a 41-year-old woman with symptomatic multiple leiomyomas who underwent laparoscopic hysterectomy with vaginal power morcellation to remove the specimen. Four months after the procedure, she started complaining of cyclic bleeding and pain and subcutaneous and vaginal vault nodules appeared. Ultrasonography and magnetic resonance images revealed subcutaneous and vaginal vault endometriosis not present previously. Even though there are several potential explanations for this case, we hypothesize that the spread of endometrial tissue in the pelvis during the electromechanical morcellation procedure triggered the appearance of multiple subcutaneous and pelvic endometriosis nodules.

**Keywords:** Uterine fibroids, Laparoscopic surgery, Morcellation, Endometriosis

Volume 9 Issue 1 - 2018

Maria Angeles Leal García,<sup>1</sup> Ana López,<sup>1</sup> Antonio Piñera,<sup>1</sup> Ignacio Zapardiel,<sup>1</sup> Alicia Hernández,<sup>1</sup> Javier De Santiago<sup>2</sup>

<sup>1</sup>Department of Gynecology, La Paz University Hospital, Spain

<sup>2</sup>MD Anderson Cancer Center Madrid, Spain

**Correspondence:** Maria Angeles Leal García MD, Department of Gynecology, La Paz University Hospital, Paseo de la Castellana 261, 28046. Madrid, Spain, Tel 34625744865, Email angelesleal@gmail.com

**Received:** December 31, 2017 | **Published:** February 21, 2018

**Abbreviations:** US, Ultrasound; MRI, Magnetic resonance imaging; FDA, The Food and Drug Administration

## Introduction

Hysterectomy is one of the most common gynecological surgical procedures. The most frequent indications include bleeding and pelvic pain.<sup>1</sup>

Both endometriosis and uterine fibroids are gynecologic disorders that affect many women of reproductive age. They are a prevalent indication for surgical intervention and share symptoms like menorrhagia, dysmenorrhea, pelvic pain and subfertility<sup>2</sup> and other common features such as sex hormone sensitivity.<sup>3,4</sup>

While myomas are accurately diagnosed via pelvic imaging such as ultrasound (US) or magnetic resonance imaging (MRI), the gold standard for endometriosis diagnosis is surgical visualization or biopsy.<sup>2</sup> However, there are useful imaging techniques like enhanced MRI and endoanal US for patients with suspected rectovaginal endometriosis which give an accurate picture of the whole pelvic disease.<sup>3</sup>

Although the pathogenesis of endometriosis remains unclear, the most accepted classical theory is the retrograde menstruation described by Sampson in 1927.<sup>5</sup> However, is mandatory to take into account other possibilities, such as the iatrogenic factor.<sup>1</sup>

Morcellation is a procedure useful for the fragmentation and extraction of big specimens during laparoscopic surgery without the need to perform a laparotomy. Several reports can be found in the literature about the new-onset of endometriosis after laparoscopic surgery.<sup>6,7</sup> There are different hypotheses that may explain this fact: endometriosis focus not visualized at the preoperative evaluation or surgical time, spread of endometrial glands during morcellation or retrograde flow from remaining endometrial tissue in the cervical stump during supracervical hysterectomy.

We report a case of a new-onset endometriosis in a patient who underwent laparoscopic hysterectomy assisted with vaginal power morcellation.

## Case report

Written informed consent was obtained from the patient. We report the case of a 41-year-old nulliparous woman with abnormal vaginal bleeding and dysmenorrhea secondary to a big myomatous uterus who produced anemia. Previous medical and surgical history was uneventful.

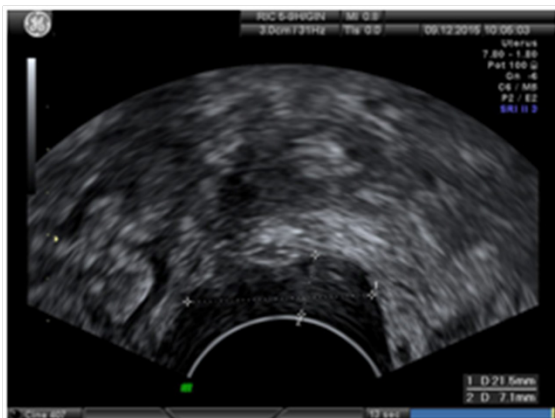The patient was included in a randomized, double blind, clinical trial comparing mifepristone to GnRH analogues for bleeding treatment. No improvement was obtained after one year of treatment so surgical treatment was decided. Two experienced gynecological surgeons in a standard fashion performed laparoscopic total hysterectomy with adnexa conservation. They used a 10-mm trocar in the umbilicus, a 5-mm suprapubic trocar and 5-mm trocars in each lower quadrant. Laparoscopic abdominal cavity exploration did not show any pathology. An enlarged uterus measuring 13 cms was removed using Liga Sure™ (Valley Lab Tyco Healthcare, Boulder, CO, USA) sealing device. Both adnexa were grossly normal in appearance. A Storz Rotocut G1 morcellator® (Karl Storz GmbH & Co, Tuttlingen Germany) was introduced through the vagina into the pelvic cavity and the uterus was morcellated and removed under direct laparoscopic vision. The uterine weight was 717 grams and the macroscopic inspection of the specimen was consistent with myomatous uterus without any evidence of adenomyosis or endometriosis focus. The vaginal vault was sutured laparoscopically using a multifilament absorbable suture.

Operative time was 70 minutes and there were no intraoperative or postoperative complications. The patient was discharged 48 hours after the procedure, and the anatomopathological study of the specimens confirmed the diagnosis of uterine leiomyomas without any additional finding.

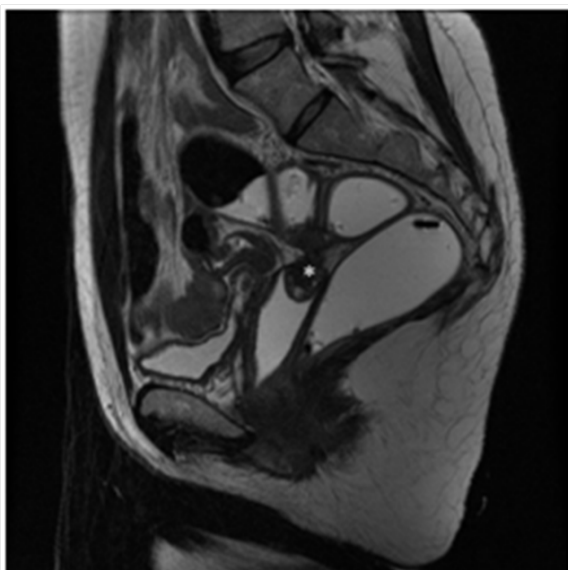
After four months of follow-up, the patient started with cyclic vaginal bleeding and pelvic pain, which improved with conventional analgesic treatment. In addition, a 2.5 cm subcutaneous palpable nodule appeared on the left fossa causing recurrent pain. During one year the patient experienced progressive clinical worsening and appearance of tenesmus. Physical examination evidenced subcutaneous nodules in

both iliac fosses and a friable and indurated 2-cm endometriosis area in the vaginal vault confirmed by biopsy.

A pelvic ultrasound revealed the presence of 1-cm endometriomas in three of the four laparoscopic trocar sites, a 3-cm right ovarian endometrioid cyst, a 17x9mm endometriosis focus in the vaginal vault, and a 21x7mm endometriosis focus in the recto-sigmoid colon (Figure 1). An MRI confirmed these findings and demonstrated a severe deep pelvic endometriosis focus in the vaginal vault with extension into the recto-sigmoid colon and bladder peritoneal surfaces. It also evidenced bilateral endometriomas (Figure 2). Serum CA-125 was 33.5 IU/mL (normal range <30 IU/mL) and CA-19.9 was 45.6 IU/mL (normal range <37 IU/mL).



**Figure 1** Sonography showing an endometriosis focus in the recto-sigmoid colon.



**Figure 2** MRI showing hyperintense endometriosis focus on fat-suppressed T1-weighted sequences.

The patient underwent hormonal therapy with oral progestagens (desogestrel 75 micrograms daily) with clinical improving. After a year of follow-up, the patient remains well but continues with an occasional vaginal bleeding.

## Discussion

Although the pathogenesis of endometriosis in our case could be unexplained by our theories, from our point of view the more

plausible explanations could be:<sup>1</sup> the presence of undiagnosed and asymptomatic endometriosis before surgery that could be spread by power morcellation. This is unlikely because the patient had a preoperative physical examination and a transvaginal and transabdominal ultrasound without endometriosis findings. In addition, the intraoperative examination was normal;<sup>2</sup> the spread of endometrial tissue in the pelvis during the power morcellation procedure that remained in the abdominal cavity after surgery. This one could be the most logical explanation, although very rare and infrequent tough.

It has been reported that cutaneous and soft tissue endometriosis appears in 70% of cases in surgical scars, especially following operations of the uterus. The remaining 30% appears spontaneously. The reported prevalence of this condition is 3.5-5.5% of all cases of endometriosis and its incidence seems to be increasing nowadays.<sup>6-9</sup> The majority of extrapelvic or subcutaneous endometriosis nodules may cause abdominal pain and/or a mass.<sup>8</sup> However, no standard treatment is generalized for this condition.

In April 2014, The Food and Drug Administration (FDA) published a safety communication discouraging laparoscopic power morcellation during hysterectomy or myomectomy for uterine fibroids to avoid the spread of unsuspected malignant disease, which would influence its prognosis.<sup>10</sup> We consider it could be applied for endometriosis pathogenesis. Due to it, endometriosis patients could also benefit from contained morcellation techniques.<sup>11-13</sup> However, there is no evidence that any kind of contained intraabdominal morcellation technique can totally prevent the dissemination of malignant tissue.<sup>14</sup>

Due to this reason, and according with FDA recommendations, there is an increasing interest in the development of new morcellation techniques that minimize the risk of tissue spreading, improving the safety of the procedure that should be also applied for endometriosis patients.

## Conclusion

Intraabdominal power morcellation could influence in the pathophysiology of endometriosis appearance or spread by means of the transplantation of viable endometrial cells within the pelvic area. In the case of laparoscopic surgery port-sites and vaginal vault could be the most frequent endometriosis development locations. We recommend the use of contained or in-bag morcellation method to diminish the current reported case.

## Acknowledgements

None.

## Conflicts of Interest

The authors have no commercial, proprietary, or financial interest in the products or companies described in this article. No funds have been received.

## References

- Schuster MW, Wheeler TL, Richter HE. Endometriosis after Laparoscopic Supracervical Hysterectomy with Uterine Morcellation: A Case Control Study. *J Minim Invasive Gynecol.* 2012;19(2):183-187.
- Paramythiotis D, Stavrou G, Stravros P, et al. Concurrent appendiceal and umbilical endometriosis: a case report and review of the literature. *J Med Case Rep.* 2014;8:258.

3. Takeuchi H, Kuwatsuru R, Kitade M, et al. A novel technique using magnetic resonance imaging jelly for evaluation of rectovaginal endometriosis. *Fertil Steril*. 2005;83(2):442–447.
4. Okolo S. Incidence, etiology and epidemiology of uterine myomas. *Best Pract Res Clin Obstet Gynaecol*. 2008;22(4):571–588.
5. Sampson JA. Peritoneal endometriosis due to menstrual dissemination of endometrial tissue into the peritoneal cavity. *Am J Obstet Gynecol*. 1927;14(4):442–469.
6. Sepilian V, Della Badia C. Iatrogenic Endometriosis Caused by Uterine Morcellation During a Supracervical Hysterectomy. *Am J Obstet Gynecol*. 2003;102(5 Pt 2):1125–1127.
7. Omori M, Ogawa T, Nara M, et al. Umbilical endometriosis with giant degenerated uterine leiomyomas: a case report. *Gynecol Oncol Rep*. 2014;9:18–20.
8. Ecker AM, Donnellan NM, Shepherd JP, et al. Abdominal wall endometriosis: 12 years of experience at a large academic institution. *Am J Obstet Gynecol*. 2014;211(4):363.
9. Choi CH, Kim JJ, Kim WJ, et al. A rare case of post-hysterectomy vault site iatrogenic endometriosis. *Obstet Gynecol Sci*. 2015;58(4):319–322.
10. US Food and Drug Administration: Laparoscopic uterine power morcellation in hysterectomy and myomectomy: FDA safety communication.
11. Gunthert AR, Christmann C, Kostov P, et al. Safe vaginal uterine morcellation following total laparoscopic hysterectomy. *Am J Obstet Gynecol*. 2014;212(4):546.
12. Einarsson JI, Cohen SL, Fuchs N, et al. In-Bag Morcellation. *J Minimally Invasive Gynecol*. 2014;21(5):951–953.
13. Cohen SL, Einarsson JI, Wang KC, et al. Contained power morcellation within an insufflated isolation bag. *Obstet Gynecol*. 2014;124(3):491–497.
14. Kho KA, Anderson TL, Nezhat CH. Intracorporeal electromechanical tissue morcellation: a critical review and recommendations for clinical practice. *Obstet Gynecol*. 2014;124(4):787–793.