

Ca 19-9 elevation in a benign ovarian cystic teratoma, a case report and review of literature

Abstract

Background: Cancer Antigen 19-9 (CA 19-9), a tumor-associated glycoprotein antigen related to the Lewis blood group, is primarily utilized in the screening, treatment, and monitoring of pancreatic adenocarcinoma and other GI malignancies. However, this antigen can be elevated in the presence of other benign and malignant neoplasms, as well as in healthy individuals. Though rarely present in the literature, CA 19-9 level has, on occasion, been associated with Mature Cystic Teratoma (MCT). Yet, its role in diagnosis remains unclear. CA 19-9 may be a useful tool in the diagnosis of MCT, as well as a possible predictor of larger tumor diameter and increased rate of torsion. In combination with CA125 it may also prove to be important in differentiating between MCT and ovarian cancer.

Case: We present a case of a 29-year-old female with Mature Cystic Teratoma (MCT) with significantly elevated CA 19-9 levels (2179.62 U/ml), who underwent left salpingo-oophorectomy and lysis of adhesion. During the immediate postoperative period, the CA 19-9 measurement decreased to 270.30 U/mL and subsequently lowered to 33.98 U/mL.

Conclusion: The diagnostic value of tumor markers in the management of human neoplasms is constantly evolving. While tumor markers cannot be used as a single entity to make a diagnosis, they have been shown to complement other diagnostic modalities in identifying certain conditions. Combined with evidence from the literature, our case highlights the potential importance of the CA 19-9 tumor marker in the diagnosis of mature cystic teratoma. Tumor diameter, rate of torsion, and rate of malignant transformation are discussed here. Previous studies have found the antigen to be present in tissues of the pancreas, biliary duct cells, stomach, gall bladder, colon, endometrium, salivary glands, and prostate. More investigation into CA-19 and its relationship with ovarian tissue may benefit our pursuit of early, accurate diagnosis and thus efficient treatment of ovarian disease.

Keywords: Benign, CA 19-9, Dermoid Cyst, Mature Cystic Teratoma (MCT), MCT, Ovarian Dermoid Cyst, Ovarian Tumors, Pancreatic Cancer, Teratoma, Tumor Markers

Volume 6 Issue 3 - 2017

Shadi Rezaï,¹ Daniel Lieberman,² Ali Raza,³ Khaldun Ferreira,¹ Cassandra E Henderson,¹ Harvey Saskaen⁴

¹Department of Obstetrics and Gynecology, Lincoln Medical and Mental Health Center, USA

²St. George's University, West Indies

³Department of Surgery, Lincoln Medical and Mental Health Center, USA

⁴Department of Pathology, Lincoln Medical and Mental Health Center, USA

Correspondence: Shadi Rezaï, Department of Obstetrics and Gynecology, Lincoln Medical and Mental Health Center, Bronx, New York, 10451, USA, Email shadi.rezaï@nychhc.org

Received: November 25, 2016 | **Published:** March 03, 2017

Background

Cancer Antigen 19-9 (CA 19-9), a tumor-associated glycoprotein antigen related to the Lewis blood group, is primarily utilized in the screening, treatment, and monitoring of pancreatic adenocarcinoma and other GI malignancies. However, this antigen can be elevated in the presence of benign and other malignant neoplasms, as well as in healthy individuals. In general, the accepted normal reference range of CA 19-9 is <37 U/mL. Aside from a handful of case reports¹⁻⁵ and larger analyses⁵⁻⁷ the association between elevated CA 19-9 level and Mature Cystic Teratoma (MCT) is scarcely reported. Yet, CA 19-9's role in diagnosis remains unclear. CA 19-9 may be a useful tool in the diagnosis of MCT, as well as a possible predictor of larger tumor diameter and increased rate of torsion.^{1,8} In combination with CA125 it may also prove to be important in differentiating between MCT and ovarian cancer.⁹ Here we present a case of a 29-year-old female with MCT who, prior to resection, had significantly elevated CA 19-9 levels.

Presentation of the case

This 29-year-old, Para 1-0-0-1 female with a history of asthma and obesity presented to the emergency department complaining of severe left lower quadrant pain and vomiting. Her initial CT Abdomen/Pelvis scan showed a 10 cm complex mass in the left adnexa, likely a Mature Cystic Teratoma (MCT), and an incidental 4.2 cm adrenal mass. Endocrine investigation of the adrenal mass was benign; findings

were consistent with lipogenic adenoma. Pelvic sonogram showed a left adnexal mass (8.8 cm) (Figure 1) and a pelvic MRI confirmed an 8 cm dermoid cyst (MCT). One year prior to the study the patient had no adnexal masses as concluded by review of an obstetrical sonogram. On pre-operative evaluation, the patient's CA 19-9 was 2179.62 U/ml. Other tumor markers, including HE4 (25 U/ml), CEA (<0.5 U/mL), CA125 (8.7 U/mL), and AFP (7.1), were all within normal limits. Intraoperatively a large dermoid cyst was found torsed and adhered to the posterior uterine wall, right adnexa and bowel. Detorsion, lysis of adhesions and left salpingo-oophorectomy were performed. The resected specimen consisted of multiple fragments of reddish/tan, soft tissue and material with hair, measuring 8 x 6 x 6 cm in aggregate. The final pathological report demonstrated: mature cystic teratoma (dermoid cyst). Postoperatively, repeat CA 19-9 measurement dropped to 270.30 U/mL and eventually down to 33.98 U/mL.

Discussion

Mature cystic teratomas comprise 10-20% of all ovarian neoplasms and they commonly present in woman aged 20 to 40 years old.⁶ We present this case in order to build on the growing body of evidence suggesting that CA 19-9 levels are useful in the diagnosis and management of MCT.^{7,10} Cases of ovarian neoplasms such as ovarian clear-cell and endometrioid carcinomas,¹¹ with increased CA 19-9 levels, and benign neoplasms with increased CA 19-9 have been documented in the literature previously.³⁻⁵ Pyeon et al.⁵ reported a

case of a benign ovarian cyst with CA 19-9 levels of 2,753 U/mL that then returned to normal postoperatively.⁵ Similarly, Sampaio et al.⁴ reported an MCT in a 50-year-old woman with the second highest reported level of CA 19-9 (8922.75 U/mL).⁴ These findings have led to more comprehensive research.

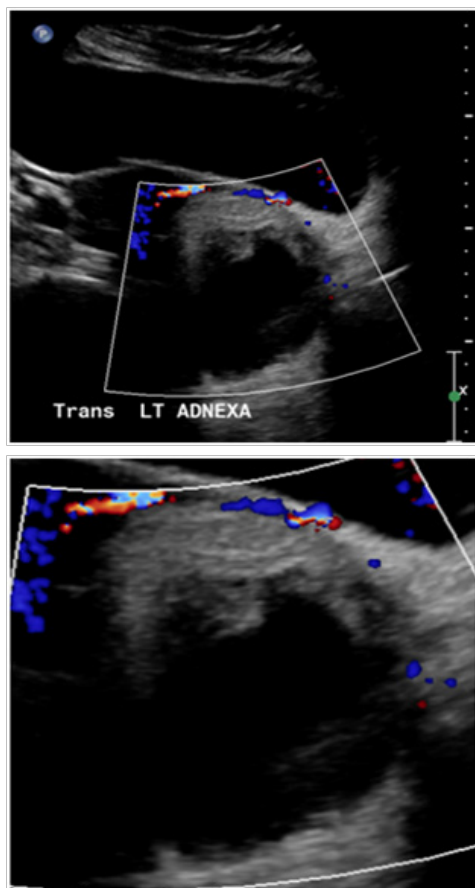


Figure 1 Pelvic ultrasound showing Complex left adnexal mass measuring approximately 8.2 × 8.8 × 7.9 cm as well as small amount of free fluid.

Elevated levels of CA19-9 and CA125 may be an indicator of bilaterality. Since levels of CA19-9 and CA125 may be elevated in both benign and malignant conditions, interpretation of these findings must be made in light of the clinical condition of the patient.¹² Ovarian torsion associated with Mature cystic teratoma (MCT) and rapid, significant changes in the serum levels of CA19-9 and CA125 in a postmenopausal woman have been reported as well.¹³

A study of 215 pathologically confirmed MCT's found the preoperative mean serum CA 19-9 level to be 83.5 ± 179.2 U/mL with an overall elevated rate of 39.6%.⁶ Comparatively, CA 125 was elevated above its threshold value in 23.3% of the patient population, and AFP was elevated above threshold in only 0.6% of the population. This study also concluded that elevated CA 19-9 levels correlated with increased tumor size, but that the diagnostic value is only significant in the presence of other indicators such as radiographic or clinical evidence. Similarly, Coskun et al.⁸ suggest that besides bedside ultrasound and CT scan, CA 19-9 might also aid in the diagnosis of MCT.⁸

Bedside ultrasound detection of MCT is highly efficacious, however it cannot determine whether or not ovarian torsion is present. In 2009 a study by Kyung et al.¹ hypothesized that CA 19-9 could

be a predictor of ovarian torsion and the extent of cystic necrosis. This retrospective investigation found that CA 19-9 and CA 125 levels were elevated in 31.9% and 12.5% of cases, respectively. In addition, CA 19-9 levels correlated with larger tumor diameters and elevated torsion rates.¹ Abiding by Kyung et al.'s¹ hypothesis, our patient also exhibited large tumor size, significant torsion, and high CA 19-9 level (2179.62 U/mL).

The role of CA 19-9 as it pertains to diagnosing MCT vs. ovarian cancer has also been investigated. One to three percent of MCT cases will undergo malignant transformation, often in postmenopausal women.⁵ Squamous cell carcinoma is the most common type of malignant transformation in mature cystic teratoma of the ovary that can be associated with elevated carbohydrate antigen 19-9 in a young patient.¹⁴ Regardless of these rare transformations, it is chiefly important to be able to differentiate between benign and malignant ovarian pathology. In 2014, one study found that serum levels of CA 19-9 were higher in borderline and malignant ovarian tumors vs. benign tumors (57.9% vs. 16.7%, $P = 0.001$).⁹ Elsewhere in the literature, reports suggest the adjunctive value of CA-125 might be important. Specifically, when both CA 19-9 and CA-125 were elevated, there was a higher probability of malignancy, whereas singular elevation of CA 19-9 correlated with benign conditions, such as MCT.²

Nevertheless, a consensus is lacking. In a retrospective cohort analysis Sagi-Dain et al.¹⁵ concluded that the combination of CA 19-9 and CA 125 does not aid in the detection of malignant adnexal masses compared with CA 125 alone.¹⁵ However, CA 19-9 could differentiate metastatic ovarian masses from primary ovarian malignancies.¹⁵ Another study that attempted to analyze the diagnostic accuracy of various tumor markers concluded that only CA-125 and CA 15-3 were significant in distinguishing between a benign and a malignant adnexal mass.¹⁶ Comparatively, CA 19-9, CEA, and AFP added insignificant value to diagnostic accuracy.^{16,17} Clearly, more in-depth investigation is needed to evaluate the potential role of CA 19-9, as well as other tumor markers. Potential clinical utility of these tumor marker's during screening, evaluation, and surveillance of a subtle ovarian mass has important implications, given the broad range of possible outcomes. Noting that abnormal tumor marker elevations need not always be cause for alarm, this additional marker may contribute to the clinical picture, with the goal of avoiding unnecessary medical intervention.

Conclusion

The diagnostic value of tumor markers in dealing with human neoplasms is constantly evolving. While tumor markers alone are not pathognomonic for a malignant diagnosis, they have been shown to complement other diagnostic modalities in identifying certain conditions. Combined with evidence from the literature our case highlights the potential importance of the CA 19-9 tumor marker as it pertains to the diagnosis of mature cystic teratoma. Tumor diameter, rate of torsion, and rate of malignant transformation are just a few aspects that have been discussed here. Studies have found the antigen to be present in tissues of the pancreas, biliary duct cells, stomach, gall bladder, colon, endometrium, salivary glands, and prostate, although abnormal CA 19-9 levels are not always associated with malignancy. This case study adds evidence to the literature that suggests that further study addressing CA 9-19 and its relationship with ovarian tissue could aide in our pursuit of early and accurate recognition and thus efficient treatment of ovarian disease. Such work can add to the known clinical value of CA-125 and transvaginal ultrasound to strengthen our ability to stratify ovarian tumors.

Acknowledgments

None.

Conflicts of interest

None.

References

1. Kyung MS, Choi JS, Hong SH, et al. Elevated CA 19-9 levels in mature cystic teratoma of the ovary. *Int J Biol Markers*. 2009;24(1):52-56.
2. Cho HY, Kim K, Jeon YT, et al. CA19-9 elevation in ovarian mature cystic teratoma: discrimination from ovarian cancer – CA19-9 level in teratoma, *Med Sci Monit*. 2013;19:230-235.
3. Artunc Ulkumen B, Goker A, Pala HG, et al. Abnormal Elevated CA 19-9 in the Dermoid Cyst: A Sign of the Ovarian Torsion? *Case Rep Obstet Gynecol*. 2013;2013:860505.
4. Sampaio J, Sarmento-Gonçalves I, Barros JM, et al. Mature Cystic Teratoma of Ovary with Abnormally High Levels of Ca19-9: A Case Report. *Rev Bras Ginecol Obstet*. 2016;38(7):365-367.
5. Pyeon SY, Park JY, Ki KD, et al. Abnormally high level of CA-19-9 in a benign ovarian cyst. *Obstet Gynecol Sci*. 2015;58(6):530-532.
6. Ustunyurt E, Gungor T, Iskender C, et al. Tumor markers in mature cystic teratomas of the ovary. *Arch Gynecol Obstet*. 2009;279(2):145-147.
7. Ugur MG, Ozturk E, Balat O, et al. Do high levels of CA 19-9 in women with mature cystic teratomas of the ovary warrant further evaluation? *Eur J Gynaecol Oncol*. 2012;33(2):207-210.
8. Coskun A, Kiran G, Ozdemir O. CA 19-9 can be a useful tumor marker in ovarian dermoid cysts. *Clin Exp Obstet Gynecol*. 2008;35(2):137-139.
9. Cho HY, Kyung MS. Serum CA19-9 as a predictor of malignancy in primary ovarian mucinous tumors: a matched case-control study. *Med Sci Monit*. 2014;20:1334-1339.
10. Saks M, Deckardt R. Laparoscopic Treatment of Benign Ovarian Dermoid Cysts. *J Am Assoc Gynecol Laparosc*. 1994;1(4, Part 2):S31-S32.
11. Helle M, Helin H, Ashorn P, et al. The expression of CEA, CA 19-9 and HMFG antigens in ovarian clear-cell and endometrioid carcinomas, *Pathol Res Pract*. 1992;188(1-2):74-77.
12. Dede M, Gungor S, Yenen MC, et al. CA19-9 may have clinical significance in mature cystic teratomas of the ovary. *Int J Gynecol Cancer*. 2006;16(1):189-193.
13. Suh DS, Moon SH, Kim SC, Joo JK, Park WY, et al. (2014) Significant simultaneous changes in serum CA19-9 and CA125 due to prolonged torsion of mature cystic teratoma of the ovary. *World J Surg Oncol* 12: 353.
14. Arioz DT, Tokyol C, Sahin FK, Koker G, Yilmaz S, et al. (2008) Squamous cell carcinoma arising in a mature cystic teratoma of the ovary in young patient with elevated carbohydrate antigen 19-9. *Eur J Gynaecol Oncol*. 2006;29(3):282-284.
15. Sagi-Dain L, Lavie O, Auslander R, et al. CA 19-9 in evaluation of adnexal mass: retrospective cohort analysis and review of the literature. *Int J Biol Markers*. 2015;30(3):e333-e340.
16. Bozkurt M, Yumru AE, Aral I. Evaluation of the importance of the serum levels of CA-125, CA15-3, CA-19-9, carcinoembryonic antigen and alpha fetoprotein for distinguishing benign and malignant adnexal masses and contribution of different test combinations to diagnostic accuracy. *Eur J Gynaecol Oncol*. 2013;34(6):540-544.
17. Santotoribio JD, Garcia-de la Torre A, Cañavate-Solano C, et al. Cancer antigens 19.9 and 125 as tumor markers in patients with mucinous ovarian tumors. *Eur J Gynaecol Oncol*. 2016;37(1):26-29.