

# A rare case report of cornual pregnancy

## Abstract

**Introduction:** Cornual pregnancy is rare condition; its incidence remains 2-4% of all ectopic pregnancies. We are hereby reporting a case of cornual pregnancy managed by laparotomy.

**Case presentation:** A cornual pregnancy was diagnosed at 10+2 weeks of amenorrhea in a 28-year-old healthy woman. Ultrasound examination showed a well-formed right cornual gestation with detectable fetal heart pulsation. We performed the right cornual resection with right salpingectomy by laparotomy.

**Conclusion:** Cornual pregnancy is a very rare and potentially dangerous condition. Diagnosis of cornual pregnancy could be made on ultrasound examination in this patient. Laparotomy is preferred in patients with unstable vitals and ruptured cases where as the routine choice should be Laparoscopy as an alternative in confirming the diagnosis and further management.

**Keywords:** Pregnancy, Tubal pregnancy, Corneal pregnancy, Laparotomy, Laproscopy

Volume 5 Issue 6 - 2016

Mamatha shetty, Chaitra Shivananjaiiah, Asha Swarup, Neha Sharma, Nisha Sharma  
MS Ramaiah Medical College, India

**Correspondence:** Chaitra Shivananjaiiah, Junior resident, M S Ramaiah Medical College, no 11, Devi Krupa, 11th A cross, 2nd stage, West of chord road, Bangalore, India, Tel 9844539891  
Email Chaitra.shiv@gmail.com

**Received:** August 01, 2016 | **Published:** December 07, 2016

## Introduction

The interstitial (cornual) part of the fallopian tube is situated in the uterine wall musculature and measures 1.2 cm in length and 0.7 cm in width. Ectopic pregnancies are more common in the ampullary region of the fallopian tube. However, cornual (interstitial) pregnancy, which is seen in about 2-4% of ectopic pregnancies, is more dangerous as it can lead to several complications. Rupture of cornual pregnancy may result in severe hemorrhage and shock, with mortality rates ranging between 2-2.5%.

## Case report

A 28 year old pima gravida presented with an episode of acute abdominal pain following 10+4 weeks amenorrhea to our accidental emergency, on examination her general conditions and vitals were well within normal limits with mild pallor. On pervaginal examination a mass of around 8 weeks was found in the right fornix with mild cervical motion tenderness when the cervix was pushed to the left side. An abdominal ultrasound revealed an empty uterine cavity and right live cornual pregnancy, with CRL corresponding to 10+2 weeks of gestation. Patient was posted and taken up for an emergency laparotomy. Intra op findings right cornual pregnancy with impending rupture (Figure 1 & 2). We performed the right cornual resection with right salpingectomy (Figure 3). Post operatively the patient was stable and discharged on the third postoperative day without any complication.

## Discussion

Early diagnosis and management of cornual pregnancy is often challenging. A cornual pregnancy may appear as an intrauterine eccentric pregnancy on ultrasound. Also, as the myometrium can distend to accommodate the pregnancy, these cases are usually diagnosed late. Diagnosis is made by transvaginal or transabdominal ultrasonography. 3D ultrasonography has shown to be more accurate.<sup>1,2</sup> Diagnostic criteria includes:

- Absence of gestational sac in uterine cavity
- Gestational sac seen independently and less than 1cm from the lateral edge of the uterine cavity

c. Thin layer of myometrium around the gestational sac

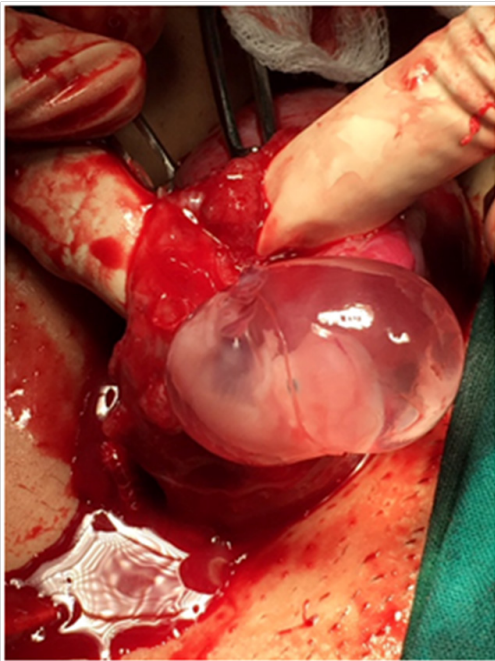
d. Interstitial line sign (echogenic line extending to the gestational sac): During early cornual gestation, the sac is located in the lateral part of the uterus. Later on, the gestational sac may be located above the uterine fundus. Thus, cornual pregnancy detected late may appear as an eccentric uterine pregnancy.<sup>3,4</sup>

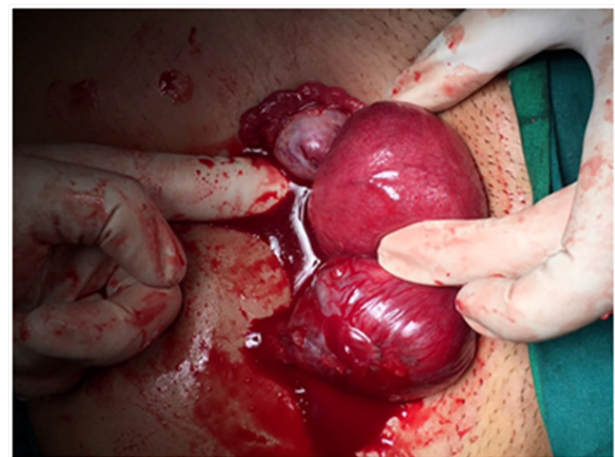

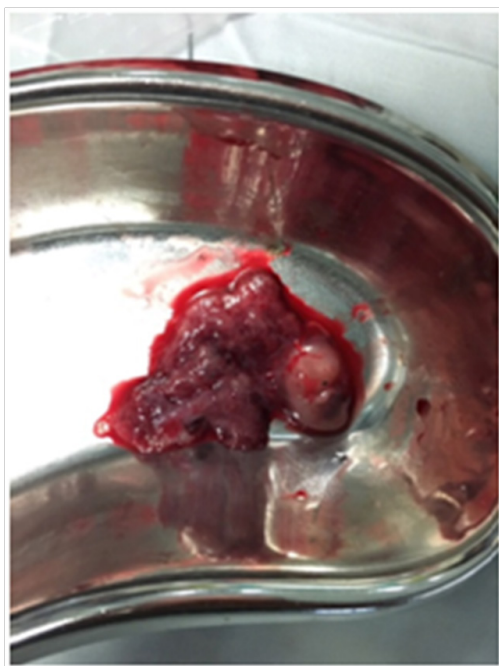Figure 1 Right cornual pregnancy with impending rupture.

## Management

Medical management of cornual pregnancy can be managed medically with systemic methotrexate. Methotrexate can be used if there is hemodynamic stability, no medical contraindications to methotrexate, and no signs of rupture. The modes for administration of methotrexate (dose: 1mg/m<sup>2</sup>) include laparoscopy, transvaginal, and through ultrasound guidance. According to the Royal College of Obstetricians and Gynaecologists, methotrexate can be given only when levels of beta human chorionic gonadotrophin are less than 3000 IU/L and the patient's symptoms are minimal. However, methotrexate may lead to severe hemorrhage and uterine rupture. Uterine artery embolization in addition to methotrexate is another effective mode for medical management of cornual pregnancy.<sup>5</sup>



**Figure 2** Gestation sac in the corneal end.



**Figure 3** Specimen following procedure.

Surgical management can be laparotomy, laparoscopy or hysteroscopy.

### Laparoscopic management

Surgical management of cornual pregnancy includes cornual resection, cornuostomy, and hysterectomy. Laparotomy or laparoscopy may be used for conservative methods of surgical management. In

patients with ruptured cornual pregnancy, laparotomy is preferred. Hysterectomy is reserved to cases in which hemorrhage is profuse and life threatening. Cornual rupture, which usually occurs between 7-12 weeks, can be fatal and requires immediate management. The cornual region has a high vascularity due to blood supply from both the uterine and ovarian vessels. Laparotomy is preferred for management of cornual rupture. The size of the cornual gestation is can be used to determine which laparoscopic technique should be applied. When gestation is less than 3.5cm, salpingostomy may be performed. Cornual resection is preferred for gestation of more than 4cm. Conservative management is also associated with higher risk of recurrence as well as uterine rupture in future pregnancies.

### Hysteroscopic management

Hysteroscopic management can be used in women who are non-compliant with treatment with methotrexate or in women who did not respond to management with methotrexate. With this technique, cornual endometrium is removed (including tubal ostium) under laparoscopic guidance.<sup>6</sup>

### Conclusion

The difficulty in early diagnosis of cornual pregnancy remains a challenge. Furthermore, the risk of uterine rupture and profuse hemorrhage can be life threatening and lead to an increase in maternal mortality. Cornual pregnancies can be managed conservatively either medically or surgically. Common modalities of treatment include local or systemic methotrexate, laparoscopic techniques such as cornuostomy and cornual resection, and hysterectomy. In addition, counseling plays an important role in terms of risk during future pregnancies. Early diagnosis and management remains the mainstay for tackling maternal mortality due to cornual pregnancy.

### Acknowledgments

None.

### Conflicts of interest

None.

### References

1. Ackerman TE, Levi CS, Dashefsky SM, et al. Interstitial line: Sonographic Finding in Interstitial (Cornual) Ectopic Pregnancy. *Radiology*. 1993;189(1):83–87.
2. Akrivis Ch, Varras M, Kyparos J, et al. Early Ultrasonographic Diagnosis of Unruptured Interstitial Pregnancy: A Case Report and Review of the Literature. *Clin Exp Obstet Gynecol*. 2003;30(1):60–64.
3. B Rizk, M Abuzeid, C Rizk, et al. Ectopic Pregnancy. In: B Rizk (Ed.), *Ultrasound in reproductive medicine and infertility, Chapter 31*, Cambridge University Press, Cambridge, USA. 2010;pp.259–270.
4. Auslender R, Arodi J, Pascal B, et al. Interstitial Pregnancy: Early Diagnosis by Ultrasonography. *Am J Obstet Gynecol*. 1983;146(6):717–718.
5. Faraj R, Steel M. Review Management of Cornual (Interstitial) Pregnancy. *Obstet Gynaecol*. 2007;9:249–255.
6. Pal B, Akinfenwa O, Harrington K. Hysteroscopic Management of Cornual Ectopic Pregnancy. *BJOG*. 2003;110(9):879–880.