

Cyst of Nuck: The Importance of Histopathological Evaluation

Abstract

A cyst of Nuck or hydrocele of Nuck, also called the forgotten diagnosis, [1] is a rare anatomical anomaly in women. Because of its rarity it is often misdiagnosed and due to the treatment pitfalls it is important to properly diagnose this tumour. Clinical examination and imaging must be performed to differentiate and diagnose the cyst correctly. However, even these modalities are not specific enough as we present in this case of a 28 year old woman with a suspected abscess of Nuck that was shown to be a cyst of Bartholin by histopathological examination. Furthermore, we reviewed the literature on this subject.

Introduction

The canal of Nuck was first described in 1691 by Anton Nuck, a Dutch anatomist [2]. During the embryological development the gubernaculum is responsible for the descent of the ovary from high in the abdomen to the inguinal canal. Eventually the gubernaculum attaches to the labium major. Inferior and superior remnants of the gubernaculum develop respectively into ligament teres uteri, also called the round ligament and ligamentum ovary proprium (Figure 1).

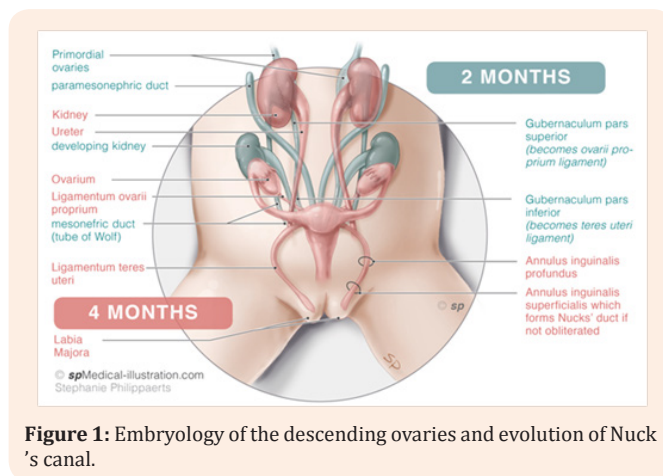


Figure 1: Embryology of the descending ovaries and evolution of Nuck's canal.

As the teres ligament evaginates out of the abdominal cavity into the inguinal canal it is covered by parietal peritoneum. This structure of peritoneum in the inguinal canal is called the canal of Nuck. The canal of Nuck also holds the ilio-inguinal nerve and the genital branch of the genitor femoral nerve.

In most cases, the canal of Nuck obliterates before birth. The cause of this obliteration is unknown, but some studies show that the calcitonin-gene related peptide (CGRP), that is being released from the genitofemoral nerve, plays a role [3]. However, in some cases there is incomplete obliteration or even no obliteration at all. This can cause cases a non-communicating cyst or even a communicating hernia in guinalis. The fluid inside the cyst of this

Review Article

Volume 5 Issue 2 - 2016

F Benali^{1,2}, A Daniels Gooszen³, C Wetzels⁴ and JMJ Piek^{1*}

¹Department of Obstetrics and Gynaecology, Catharina hospital, Netherlands

²Department of Radiology, Maastricht University Medical Center, Netherlands

³Department of Radiology, Catharina hospital, Netherlands

⁴Department of Pathology, Catharina hospital, Netherlands

*Corresponding author: JMJ Piek, Department of Obstetrics and Gynaecology, Catharina hospital, Netherlands, Email: jurgen.piek@gmail.com

Received: July 29, 2016 | Published: September 21, 2016

canal of Nuck is a result of disbalance between production and absorption of fluid produced by the parietal peritoneum [4].

A cyst of Nuck is a rare entity. The incidence is not exactly known but literature estimates an incidence of 1% in young girls [5]. However, this might be an underestimation, since the cyst might be misdiagnosed.

Case Report

A 25 year old null gravid with no medical history presented with a painful vulvar swelling superior lateral of the right major labium of approximate four centimetres in diameter. The swelling fluctuated and was red. This swelling was present since one month, however the intense pain was present since three days. There was no history of fever. On examination an in durated, red frontal part of the labium with swelling of the tissue between the top of the labium and the inguinal canal was seen. No enlarged inguinal lymph nodes were palpable. The Valsalva manoeuvre was negative, further gynaecologic examination was impossible due to intense pain. Ultra sonography showed a fluid filled cyst of five centimetres in diameter in the upper part of the labium up to the inguinal canal, without positive Doppler flow.

The initial differential diagnosis consisted of an infected cyst of Bartholin, an infected cyst of Nuck, an infected lipoma, leiomyoma or a sarcoma. Since Bartholin glands are located slightly posterior and to the left and right of the opening of the vagina, an infected cyst of Nuck was our working diagnosis. Marsupialisation of the complete cyst wall was performed under general anaesthesia. The cyst wall was located in the upper part of the labium and ended in the direction of the right inguinal canal. Afterwards a redon-drain was placed and the wound was closed. Post-operative there were no complications except for pain. This was treated with tramadol,

ibuprofen and pantoprazol. One day postoperatively, the patient was discharged. The drain remained for two days. On follow up after one week, the wound was closed and healing properly. Microbiological investigation of the pus showed no chlamydia, *Neisseria gonorrhoea*, *mycoplasma genitalium* or *trichomonas*

vaginalis. Histological examination revealed fragments of a cystic lesion adjacent to normal Bartholin's gland acini. The cyst wall was partially lined by a stratified squamous, transitional and columnar epithelium. There was a moderately to heavy active inflammatory component causing erosion and abscess formation (Figure 2).

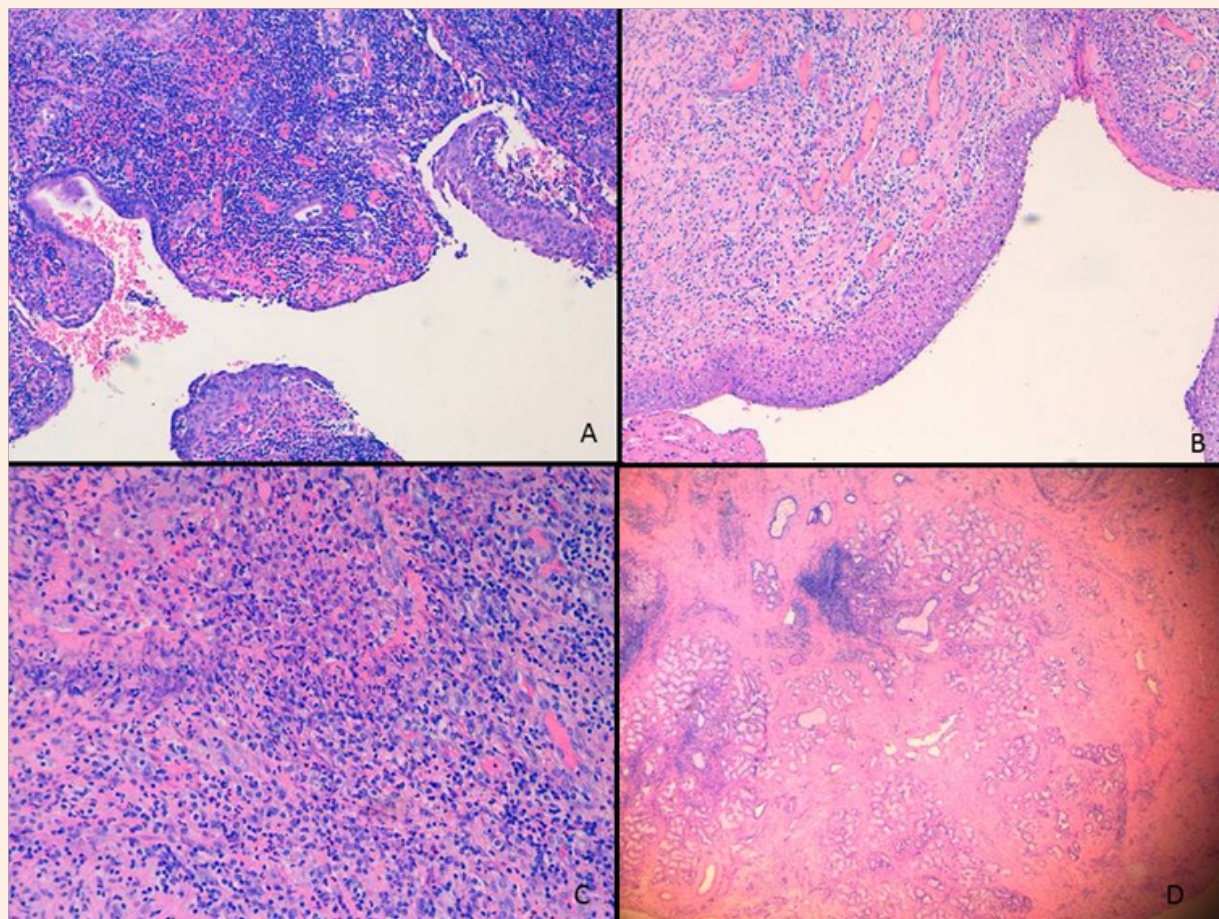


Figure 2: A. Heavily inflamed cyst wall with columnar, transitional and stratified squamous epithelium. (HE, 10x magnification)
B. Erosive part of the cystic wall. (HE, 10x magnification)
C. Active inflammation with abscess formation. (HE, 20x magnification)
D. Lobules of Bartholin's gland acini adjacent to the cyst. (HE, 2,5x magnification)

Literature Search

A pubmed search was performed with mesh term: "nuck" until June 2016. A total number of 72 studies are mentioned in literature. Forty-six cases are on a hydrocele of Nuck / infected cyst of Nuck [5,9-51]. Thirteen cases on endometriosis in a cyst of Nuck [52-61]. One case of an ectopic pregnancy [62] as well as six cases on herniation of Nucks' duct are described [63-68]. Furthermore, one case of angiofibroblastoma [69] and one case of

angiomyofibroma [70], two cases of adenocarcinoma [71,72] and two cases of haematocole of Nucks' duct [73,74] are described. All articles were analysed for complaints at presentation, whether histopathological investigation was done and which radiological investigation was done (Table 1). This information was available in 32 of the studies. In only Fifty-six percent (18 studies) histopathological investigation was performed.

Table 1: Results of the literature review with data on complaints at presentation, whether histopathological evaluation was performed and what imaging modality was used.

Sarkar S. et al. [8]	Complaint: Tender right in guino-labial swelling Histopathology: Yes Imaging modality: surgical exploration
Patnam V et al. [9]	Complaint: Swelling was non-tender, cystic and irreducible. No cough impulse. Histopathology: No Imaging modality: CECT, MRI
Heer J et al. [11]	Complaint: painless "boil" to the right groin, Histopathology: No Imaging modality: CT
Kono R et al. [12]	Complaint: Swelling in the right inguinal region Histopathology: YES Imaging modality: MRI
Mazzeo C et al. [54]	Complaint: Unknown Histopathology: No Imaging modality: MRI
Husaric E et al. [13]	Complaint: Left sided groin swelling Histopathology: No Imaging modality: surgical exploration
Hensgens RL et al. [14]	Complaint: Painful swelling in right groin Histopathology: No Imaging modality: surgical exploration
Matsumoto T et al. [22]	Complaint: Painless and reducible swelling in left groin Histopathology: Yes Imaging modality: US and MRI
Uno Y et al. [55]	Complaint: Lump in right inguinal region Histopathology: Yes Imaging modality: MRI
Qureshi NJ et al. [15]	Complaint: Pain and swelling in left inguinal region Histopathology: Yes Imaging modality: US
Noguchi D et al. [67]	Complaint: Painful swelling in right groin Histopathology: Yes Imaging modality: US, MRI
Mandhan P et al. [17]	Complaint: Tender swelling in guino-labial swelling left Histopathology: Yes Imaging modality: US, MRI
Jagdale R et al. [16]	Complaint: Painful swelling in right groin Histopathology: Yes Imaging modality: US
Choi YM et al. [19]	Complaint: Inguinal groin with (case 1) and without (case 2) tenderness Histopathology: Case 1: No, Case 2: Yes Imaging modality: US and MRI

Manjunatha Y et al. [24]	Complaint: Palpable mass in right inguinal region with occasionally pain Histopathology: Yes Imaging modality: MRI and US
Bagul A et al. [56]	Complaint: Swelling in right groin with mild discomfort Histopathology: Yes Imaging modality: surgical examination
Ozel A et al. [25]	Complaint: Inguinal groin right Histopathology: Yes Imaging modality: MRI
Hernández Monge A et al. [75]	Complaint: Unknown Histopathology: Yes Imaging modality: Unknown
Bhattacharjee PK et al. [27]	Complaint: Painless left groin swelling Histopathology: No Imaging modality: ultrasound
Cervini P et al. [59]	Complaint: Mass overlying right pubis Histopathology: Yes Imaging modality: Ultra sonography
Ameh EA et al. [29]	Complaint: Right groin swelling Histopathology: No Imaging modality: surgery
Huang CS et al. [30]	Complaint: Asymptomatic palpable movable mass Histopathology: No Imaging modality: Ultra sonography
Turpin F et al. [61]	Complaint: Unknown Histopathology: No Imaging modality: US and MRI
Hernández-Monge A et al. [75]	Complaint: Unknown Histopathology: Yes Imaging modality: Unknown
Laskin WB et al. [74]	Complaint: Painless mass Vulvar Region (15 cases) Histopathology: Yes Imaging modality: Unknown
Josefsson ML et al. [69]	Complaint: Pelvic pain Histopathology: No Imaging modality: Ultra sonography
Caviezel A et al. [38]	Complaint: Unknown Histopathology: Yes Imaging modality: MRI and Ultra sonography
Wang CJ et al. [63]	Complaint: Tender mass in left groin Histopathology: No Imaging modality: Ultra sonography
Jedrzejewski G et al. [71]	Complaint: Palpable movable mass in right inguinal region Histopathology: No Imaging modality: Ultra sonography

Khanna PC et al. [39]	Complaint: Right inguinal pain and discomfort Histopathology: No Imaging modality: Ultra sonography
De Meulder F et al. [40]	Complaint: Bulge in right groin Histopathology: Yes Imaging modality: Ultra sonography
Miklos JR et al. [44]	Complaint: Painful vulvar mass Histopathology: No Imaging modality: Ultra sonography

Discussion

In the differentiation of causes of a vulvar swelling, imaging is of importance. In this case ultra sonography was used. This technique is seen as the golden standard for assessing swellings in the vulvar area⁶. This technique is simple, non-invasive and radiation free. Figure 3 shows examples from different patients from our population of MRI and ultrasound images from a cyst

of Nuck and Bartholin. However, in this case the vulvar swelling was mistakenly taken for a cyst of Nuck, because of the anatomical location and the relation with the inguinal canal. It was only by histopathological examination that a cyst of Bartholin was diagnosed. We therefore urge histopathological examination of all removed vulvar swellings, because a cyst of Nuck might be even more rare, since most case reports in our literature search did not mention the results of the histopathological examination.

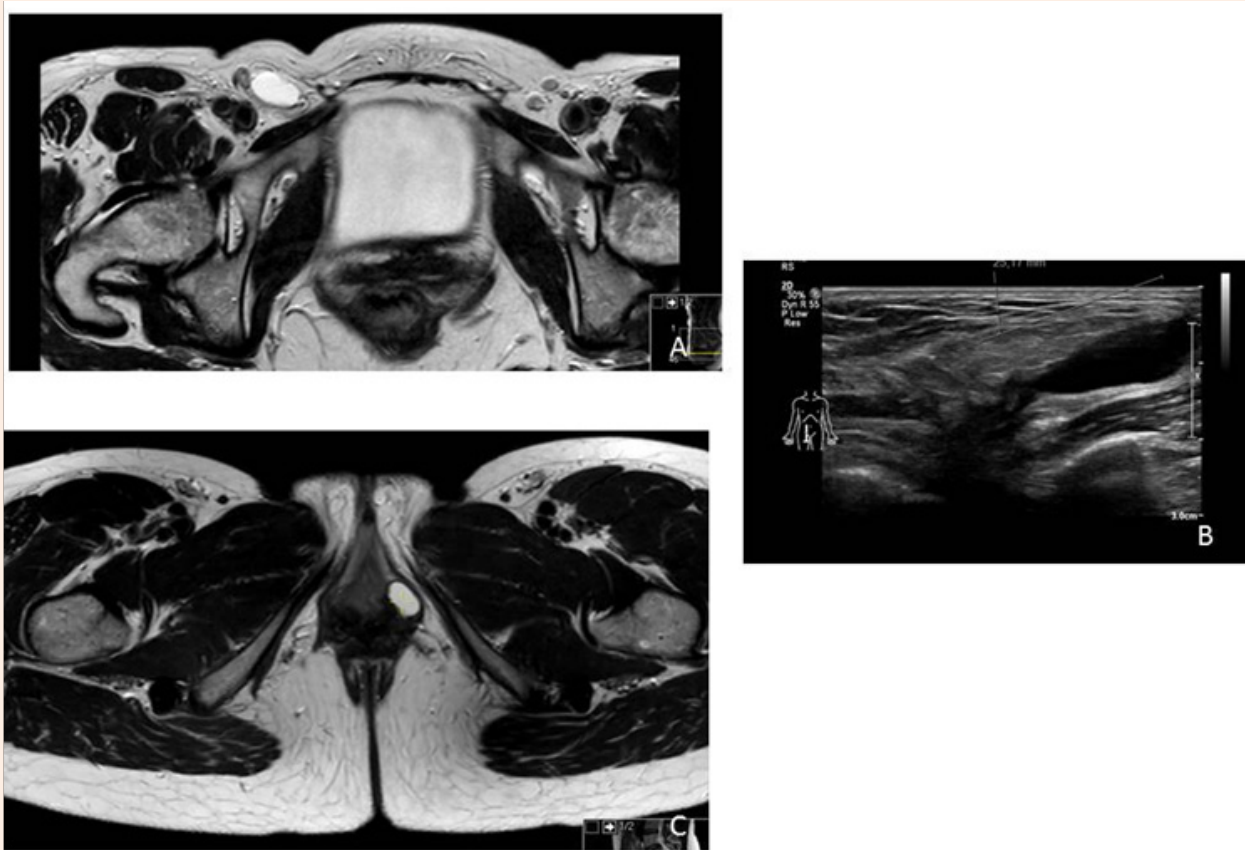


Figure 3: A. example of an MRI image of a cyst of Nuck.
B. example of an ultrasound image of a cyst of Nuck.
C. example of an MRI image of a cyst of Bartholin.

In all cases it is important to exclude vascularisation of the cyst, which can easily be done by ultra sonography. This can be a sign of a true inguinal hernia or a malignancy [7]. Most prevalent malignancies in the vulvar area that have a similar presentation as a cyst of Bartholin or Nuck are liposarcoma, leiomyosarcoma, fibro sarcoma and undifferentiated sarcoma [6]. An inguinal hernia is characterized by an hypo-echo genic mass usually containing intestines, omentum or other structures.

Conclusion

Ultra sonography has a place in the differential diagnosis of a vulvar swelling. However, as shown in the case report histopathological examination is always warranted when assessing cysts in the vulvar area.

References

- Riquard L, Hensgens en Jan-Kees Breek (2016) Een vrouw met een pijnlijke zwelling in de lies. De cyste van Nuck een vergeten diagnose. *Ned. Tijdschrift Geneeskde* 160: A9476.
- De peritonaeidiverticulitidis "the new peritone diverticulitis" adenografia curiosa et uteri foemineianatome nova. Leiden. pp. 130-138.
- Pediatricernias, Andre Hebra, MD et al. (2015) Surgery and Pediatrics, Medical University of South Carolina College of Medicine, USA.
- SJ Park, HK Lee, HS Hong, HC Kim, DH Kim (2004) Hydrocele of the canal of Nuck in a girl: ultrasound and MR appearance. *The British Institute of Radiology* 77(915).
- Sarkar S, Panja S, Kumar S (2016) Hydrocele of the Canal of Nuck (Female Hydrocele): A Rare Differential for Inguino-Labial Swelling. *J Clin Diagn Res* 10(2): PD21- PD22.
- Rathaus V, Konen O, Shapiro M, Lazar L, Grunebaum M, et al. (2001) Ultrasound features of spermatic cord hydroceles in children. *Br J Radiol* 74(885): 818-820.
- Walter H. Stickel, Martin Manner (2004) Female Hydrocele (Cyst of the Canal of Nuck) Sonographic Appearance of a Rare and Little-Known Disorder. *J Ultrasound Med* 23: 429-432.
- Patnam V, Narayanan R, Kudva A (2016) A cautionary approach to adult female groin swelling: hydrocoele of the canal of Nuck with a review of the literature. *BMJ Case Reports*.
- Heer J, McPheeters R, Atwell AE, Aguiniga P, Blake J (2015) Hydrocele of the Canal of Nuck. *West J Emerg Med* 16(5): 786-787.
- Kono R, Terasaki H, Murakami M, Tanaka M, Takeda J, et al. (2015) Hydrocele of the canal of Nuck: a case report with magnetic resonance hydrography findings. *Surg Case Rep* 22(1): 86.
- Husaric E, Hotic N, Halilbasic A, Husaric S, Rahmanovic E, et al. (2014) Cyst of the canal of nuck in a two year old girl. *Husaric Med Arch* 68(4): 289-290.
- Hensgens RL, Breek JC (2015) [A woman with a painful swelling in the groin: the cyst of Nuck, a forgotten diagnosis]. *Ned Tijdschr Geneeskde* 160: A9476.
- Qureshi NJ, Lakshman K (2014) Laparoscopic excision of cyst of canal of Nuck. *J Minim Access Surg* 10(2): 87-89.
- Jagdale R, Agrawal S, Chhabra S, Jewan SY (2012) Hydrocele of the canal of Nuck: value of radiological diagnosis. *J Radiol Case Rep* 6(6): 18-22.
- Mandhan P, Raouf Z, Bhatti K (2013) Infected hydrocele of the canal of nuck. *Case Rep Urol* 2013: 275257.
- Akkoyun I, Kucukosmanoglu I, Yalinkilinc E (2013) Cyst of the canal of nuck in pediatric patients. *N Am J Med Sci* 5(6): 353-356.
- Choi YM, Lee GM, Yi JB, Yoon KL, Shim KS, et al. (2012) Two cases of female hydrocele of the canal of nuck. *Korean J Pediatr* 55(4): 143-146.
- Janssen K, Klinkner D, Kumar T (2011) Encysted hydrocele of canal of nuck: a case report with review of literature. *J Surg Tech Case Rep* 3(2): 97-98.
- Manjunatha Y, Beeregowda Y, Bhaskaran A (2012) Hydrocele of the canal of Nuck: imaging findings. *Acta Radiol Short Rep* 1(3): pii: arsr.2012.
- Matsumoto T, Hara T, Hirashita T, Kubo N, Hiroshige S (2014) Laparoscopic diagnosis and treatment of a hydrocele of the canal of Nuck extending in the retroperitoneal space: A case report. *Int J Surg Case Rep* 5(11): 861-864.
- Pérez-Colon L, Mejía-Berrios D, Cruz-Correa J, Rivera-Pedrogo J, Laboy-Torres J (2010) Female hydrocele of the canal of Nuck: a case report. *Bol Asoc Med P R* 102(4): 59-61.
- Deuschle P, Michel M, Lenz F, Wessel L (2012) [First case of an antenatally diagnosed cyst of Nuck]. *Ultraschall Med* 33(2): 185-186.
- Ozel A, Kirdar O, Halefoglu AM, Erturk SM, Karpaz Z, et al. (2009) Cysts of the canal of Nuck: ultrasound and magnetic resonance imaging findings. *J Ultrasound* 12(3):125-127.
- Hammond I (2007) Cyst of the canal of Nuck. *J Ultrasound Med* 26(1): 147.
- Bhattacharjee PK, Ghosh G (2006) Hydrocele of the canal of Nuck. *J Indian Med Assoc* 104(3): 150-151.
- Yuksel KZ, Senoglu M, Yuksel M, Ozkan KU (2006) Hydrocele of the canal of Nuck as a result of a rare ventriculo peritoneal shunt complication. *Pediatr Neurosurg* 42(3): 193-196.
- Ameh EA, Garba ES (2003) Infected hydrocoele of the canal of Nuck in a neonate. *Urol Int* 71(2): 226-227.
- Huang CS, Luo CC, Chao HC, Chu SM, Yu YJ, et al. (2003) The presentation of asymptomatic palpable movable mass in female inguinal hernia. *Eur J Pediatr* 162(7-8): 493-495.
- Schneider CA, Festa S, Spillert CR, Bruce CJ, Lazaro EJ (1994) Hydrocele of the canal of Nuck. *N J Med* 91(1): 37-38.
- Kucera PR, Glazer J (1985) Hydrocele of the canal of Nuck. A report of four cases. *J Reprod Med* 30(5): 439-442.
- Koike H, Mori N (1983) Hydrocele of the canal of Nuck in a girl. *Nihon Sanka Fujinka Gakkai Zasshi* 35(11): 2031-2033.
- Chiappa A, Tanferna M, Panazzolo A, Fantoni A, Julitta R, et al. (1982) Description of bilateral hydrocele of the canal of Nück. Clinical case. *Arch Sci Med (Torino)* 139(4): 549-551.
- Block RE (1975) Hydrocele of the canal of nuck. A report of five cases. *Obstet Gynecol* 45(4): 464-466.
- Cleary RE, Spadoni LR, Herrmann WL (1968) Unilateral labial swelling: patent Canal of Nuck and ascites. *Gynaecologia* 166(6): 461-465.
- Beltrán Marín M, MayayoSinués E, Angulo Hervias E (2010) Solution to case 18: Hydrocele of the canal of Nuck. *Radiologia* 52(3): 270-272.

36. Caviezel A, Montet X, Schwartz J, Egger JF, Iselin CE (2009) Female hydrocele: the cyst of Nuck. *Urol Int* 82(2): 242-245.
37. Khanna PC, Ponsky T, Zagol B, Lukish JR, Markle BM (2007) Sonographic appearance of canal of Nuckhydrocele. *Pediatric Radiology* 37(6): 603-606.
38. De Meulder F, Wojciechowski M, Hubens G, Ramet J (2006) Female hydrocele of the canal of Nuck: a case report. *Eur J Pediatr* 165(3): 193-194.
39. Yigit H, Tuncbilek I, Fitoz S, Yigit N, Kosar U, et al. (2006) Cyst of the canal of Nuck with demonstration of the proximal canal: the role of the compression technique in sonographic diagnosis. *J Ultrasound Med* 25(1): 123-125.
40. Stickel WH, Manner M (2004) Female hydrocele (cyst of the canal of Nuck): sonographic appearance of a rare and little-known disorder. *J Ultrasound Med* 23(3): 429-432.
41. Dawam D, Kanu P (1998) Giant hydrocele of the canal of Nuck. *British Journal of Urology* 81(4): 636.
42. Miklos JR, Karram MM, Silver E, Reid R (1995) Ultrasound and hookwire needle placement for localization of a hydrocele of the canal of Nuck. *Obstet Gynecol* 85(5 Pt 2): 884-886.
43. Ballas S, Gitstein S, Peyser MR, Toaff R (1978) Hydrocele of the canal of Nuck. *Harefuah* 95(10): 349-351.
44. Mc Elfatrick RA (1973) Hydrocele of the canal of Nuck. A report of two adult cases. *Condon WB Rocky Mt Med J* 1975 72(3): 112-113. No abstract available. Hydrocele of the canal of Nuck. *Ariyan S J Urol* 110(2): 172-175.
45. Kapsinow R (1959) Hydrocele of the Canal of Nuck; report of case. *J La State Med Soc* 111(1): 25-26.
46. J Richard Thistlethwaite (1951) Hydrocele of canal of Nuck with retroperitoneal extension. *Postgrad Med* 9(1): 35-37.
47. Ellis JT, Windham SW, Latiolais SG (1949) Hydrocele of the canal of Nuck. *South Surg* 15(9): 718-722.
48. David R, Lunski I, Laor D, Mizrahi S (1987) Nuck canal cyst simulating inguinal hernia. *Harefuah* 113(7-8): 163.
49. William S, MC Cune (1948) Hydrocele of the Canal of Nuck with Large Cystic Retroperitoneal Extension. *Annals of Surgery* 127(4): 750-753.
50. Counseller VS, Black BM (1941) Hydrocele of the Canal of Nuck: Report of Seventeen Cases. *Ann Surg* 113(4): 625-630.
51. Koike H, Mori N (1983) Hydrocele of the canal of Nuck in a girl. *Nihon Sanka Fujinka Gakkai Zasshi* 135(11): 2031-2033.
52. Mazzeo C, Gammeri E, Foti A, Rossitto M, Cucinotta E (2014) Vulvar endometriosis and Nuck canal. *Ann Ital Chir* 85(ePub).
53. Yoshiko Uno, Shintaro Nakajima, Fumiaki Yano, Ken Eto, Nobuo Omura, et al. (2014) Mesothelial cyst with endometriosis mimicking a Nuck cyst. *Surg Case Rep* (6).
54. Bagul A, Jones S, Dundas S, Aly EH (2011) Endometriosis in the canal of Nuck hydrocele: An unusual presentation. *International Journal of Surgery Case Reports* 2(8): 288-289.
55. Gaeta M, Minutoli F, Mileto A, Racchiusa S, Donato R, et al. (2010) Nuck canal endometriosis: MR imaging findings and clinical features. *Abdom Imaging* 35(6): 737-741.
56. Kirkpatrick A, Reed CM, Bui-Mansfield LT, Russell MJ, Whitford W (2006) Radiologic-pathologic conference of Brooke Army Medical Center: endometriosis of the canal of Nuck. *AJR Am J Roentgenol* 186(1): 56-57.
57. Cervini P, Mahoney J, Wu L (2005) Endometriosis in the canal of Nuck: atypical manifestations in an unusual location. *AJR Am J Roentgenol* 185(1): 284-285.
58. Cervini P, Wu L, Shenker R, O Blenes C, Mahoney J (2004) Endometriosis in the canal of Nuck: Atypical manifestations in an unusual location. *Can J Plast Surg* 12(2): 73-75.
59. Turpin F, Daclin PY, Karam R, Mény R, Salanon AP, et al. (2001) A case of muscular and canal of nuck involve endometriosis. *Journal de Radiologie* 82(8): 933-935.
60. Scaglione V, Granieri A (1981) [Bilateral endometriosis of the canal of Nuck simulating strangulated hernia]. *Ann Ostet Ginecol Med Perinat* 102(1): 55-61.
61. Wang CJ, Chao AS, Wang TH, Wu CT, Chao A, et al. (2009) Challenge in the management of endometriosis in the canal of Nuck. *Fertility and Sterility* 91(3): 936.e9-936.e11.
62. Noguchi D, Matsumoto N, Kamata S, Kaneko K (2014) Ectopic pregnancy developing in a cyst of the canal of Nuck. *Obstet Gynecol* 123(2 Pt 2 Suppl 2): 472-476.
63. Garteiz Martínez D, Nieto González SE, Bravo Torreblanca C, Weber Sánchez A (2013) Cyst of Nucks canal associated with recurrent inguinal hernia. *Ginecol Obstet Mex* 81(1): 52-56.
64. Josefsson ML, Mitra S, Gupta S (2013) Inguinal ovary in adult women-case report and literature review. *Springer plus* 2: 545.
65. Yang DM, Kim HC, Kim SW, Lim SJ, Park SJ, et al. (2014) Ultrasonographic diagnosis of ovary-containing hernias of the canal of Nuck. *Ultrasonography* 33(3): 178-183.
66. Jedrzejewski G, Stankiewicz A, Wiczorek AP (2008) Uterus and ovary hernia of the canal of Nuck. *Pediatr Radiol* (11):1257-1258.
67. Tubbs RS, Loukas M, Shoja MM, Salter EG, Oakes WJ (2007) Indirect inguinal hernia of the urinary bladder through a persistent canal of Nuck: case report. *Hernia* 11(3): 287-288.
68. Harbeson AE (1933) Congenital Hernia of the Ovary and Tube into the Canal of Nuck With Report of a Case. *Can Med Assoc J* 29(3): 295-297.
69. Laskin WB, Fetsch JF, Tavassoli FA (1997) Angiomyofibroblastoma of the female genital tract: analysis of 17 cases including a lipomatous variant. *Hum Pathol* 28(9): 1046-1055.
70. Hernández Monge A, Estrada Moscoso I, MárquezIribe P, Alanis Fuentes J, Pacheco Pineda R (2006) Vulvar cellular angiofibroma. A report of a case and bibliographic review. *Ginecol Obstet Mex* 74(9): 499-502.
71. Mesko JD, Gates H, McDonald TW, Youmans R, Lewis J (1988) Clear cell ("mesonephroid") adenocarcinoma of the vulva arising in endometriosis: a case report. *Gynecol Oncol* 29(3): 385-391.
72. Sun CC, Toker C, Masi JD, Elias EG (1979) Primary low grade adenocarcinoma occurring in the inguinal region. *Cancer* 44(1): 340-345.
73. Forsyth JA (1912) Hæmatocele of the Canal of Nuck. *Proc R Soc Med* 5(Obstet Gynaecol Sect): 334-335.
74. Ryan JD, Joyce MR, Pierce C, Brannigan A, O'Connell PR (2009) Haematoma in a hydrocele of the canal of Nuck mimicking a Richter's hernia. *Hernia* 13(6): 643-645.