

Genital Reconstructive Surgery after Female Genital Mutilation

Abstract

Background: Female Genital Mutilation (FGM,) the partial or total removal of the external genitalia for non-medical reasons, is a cultural tradition widely practiced in Africa and other parts of the world for the past 3000 years, with severe health hazards and serious complications on the physical, and psychological levels. Most FGM victims are unaware of the availability of clitoral reconstructive surgery to reverse the ill effects of FGM.

Method: 107 patients were selected for this study, with female genital mutilation Type II and Type III (91 Type II & 16 Type III), aged 18 - 36 years, who consulted the Urogynecology & Reconstructive Vaginal Surgery unit at El Galaa Teaching Hospital for Women. All patients answered a Female Sexual Function Index (FSFI) questionnaire on admission, noting their sexual characteristics, and pain level. Postoperatively; patients were asked to come in every 3 months for 1 year for follow up.

Results: Mean age of women was 28.3 years, mean age at cutting 9.1 years, countries where the mutilation was done include Egypt, Sudan, Somalia, Djibouti, and Yemen. Reconstructive repair procedures were performed at El Galaa Teaching Hospital.

Conclusion: Clitoral Reconstructive Surgery after Female Genital Mutilation provides an improvement in patient's psychology noted by an increase in confidence, self-esteem, and feminine body image, it has also improved sexual desire, arousal, and satisfaction; with minimal improvement in orgasm, lubrication, and pain. We suggest it be offered to FGM victims, who consult gynecology clinics, in other hospitals, and training doctors in genital reconstructive techniques.

Keywords: Female Genital Mutilation; Clitoral Reconstructive Surgery; De-infibulation

Research Article

Volume 4 Issue 6 - 2016

Seifeldin A*

El Galaa Teaching Hospital for Women, Egypt

***Corresponding author:** Amr Seifeldin, El Galaa Teaching Hospital for Women, 12, Deglast, Mahandessine, Giza 12411, Cairo, Egypt, Tel: +2-0100-5250230; +2-0122-3675300; Email: amr@seifeldin.org; a.seifeldin@gmail.com

Received: April 19, 2016 | **Published:** June 23, 2016

Introduction

FGM seems to have originated in ancient Egypt and is documented by Herodotus in 440 BC, a papyrus from Memphis dated 163 BC, and Strabo in 25 BC. Some ancient Egyptian mummies have been found circumcised on examination. It is estimated that 150 million young women have been circumcised worldwide, and an additional 3 million are at risk / circumcised every year [1], approximately 8000 per day, mainly in Sub-Saharan Africa. In Egypt type 1a (sunna circumcision / clitorodotomy) is more common, about 70% of cases. Egypt has the highest number of FGM/C cases in the world [2]. The Egyptian parliament banned and criminalized FGM practice in 2008, helping to drop FGM/C rates to 61% in 2015, from 91% in 1995, while aiming to stop FGM/C in Egypt by 2030. Hoping other African countries would follow. Female genital mutilation has spread globally with the increased influx of African refugees and immigrants to Europe and North America [3], and has become a global problem (650,000 cases in Europe & 570,000 in the United States) with severe physical and psycho-sexual medical consequences [4], increasing health care financial burdens on the host country. Female circumcision is believed to decrease sexual desire, arousal, and orgasm [5], which is the leading reason for the practice of FGM. Many women mistakenly believe that sexual dysfunction in

women with FGM results from the cutting of sexual organs, for which no treatment is available [6]. The WHO reports that FGM may involve total removal of the clitoris. However, it is the visible part of the clitoris (the glans) that is cut. The rest of the body and crura of the clitoris remain intact under the scar [7,8] (Figure 1).

The clitoris is composed of the glans (visible portion of the clitoris, covered by the prepuce), the body (attached to the pubic symphysis by the suspensory ligament), the crura (two stems attached to the ischio-pubic rami), and bulbs (erectile structures that become engorged during arousal and lie under the labia) [8]. FGM can involve cutting of the labia minora or majora (type II or III). Because most erectile structures are not excised, healthy women with FGM can reach orgasm and experience satisfying sexual relationships, since most of the clitoris remains, the clitoral stump palpable beneath the scar tissue can be exposed, a neoglans reconstructed, and repositioned at the clitoral anatomical site [3,9]. The surgery is reported to improve sexual function as it decreases clitoral pain by removing peri-clitoral fibrosis, thus making the clitoris more accessible to stimulation [10].

However, many women are unaware of the availability of clitoral reconstructive surgery, and request it after it is offered to them to improve their female identity and genital image, despite

having an already functional clitoral stump [4,11]. In these cases, sexual function is improved by enhanced body image, female identity, and self-confidence, rather than by a more accessible clitoris (psycho- sexual impact) [12]. Genital reconstructive surgery after FGM/C remains a major challenge in reconstructive gynecology; new techniques of clitoral reconstruction, clitoral hood restoration, and labial de-infibulation have been adopted to reverse the effects of FGM; the effectiveness and safety of such techniques are debated and inconclusive [12]. Further scientific study regarding sexual function in women with FGM is required to offer the best available medical, surgical, and psychosexual care for complications after FGM.

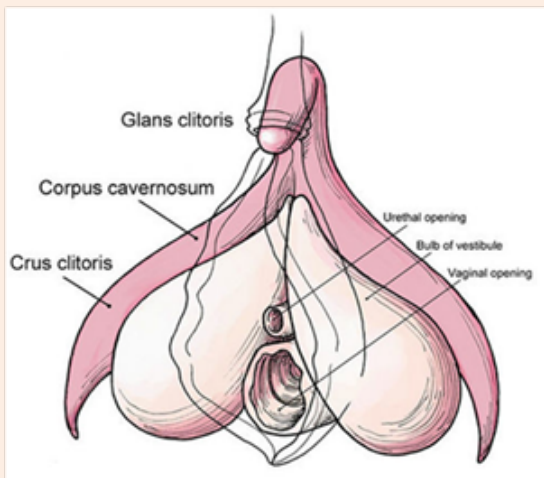


Figure 1: The female clitoris.

Aim

To study the impact of genital reconstructive surgery on females with FGM type II & type III with regards to; improvement of desire, arousal, lubrication, orgasm, satisfaction, and pain reduction.

Patients

107 selected patients with female genital mutilation aged 18 - 36 years who had mostly consulted the Urogynecology & pelvic reconstructive surgery unit at El Galaa Teaching Hospital in Cairo were included in the study. Mean patient age was 28.3 years, mean age at cutting 9.1 years. Countries where the mutilation was done include Egypt, Sudan, Somalia, Djibouti, and Yemen. Reconstructive repair procedures were performed mostly at El Galaa Teaching Hospital. We used the WHO classification to include women with type II or type III mutilation (infibulation) with excision of clitoris. (91 with Type II & 16 with Type III) Our study complied with all medical ethics requirements according to Egyptian research guidelines. Patients were informed about outcome and side effects of the procedures and signed a written consent.

Procedure

All patients came to the clinic asking to improve physical appearance or reduce pain, most were unaware of the availability

of clitoral reconstructive surgery services [13-15]. They all filled out a Female Sexual Function Index questionnaire on admission, clitoral reconstructive surgery was offered to these women, all patients received spinal anesthesia.

De-fibulation: Infibulation is narrowing of the vaginal orifice with creation of a covering seal by cutting and suturing the labia minora and labia majora together on both sides, after excision of the clitoris (infibulation), women who have undergone type III mutilation require a de-fibulation (cutting the skin seal) before delivery or vaginal surgery. Functional improvements have been described after this de-fibulation procedure in many women with type III [13,14,16-18]. (Figure 2 & 3)

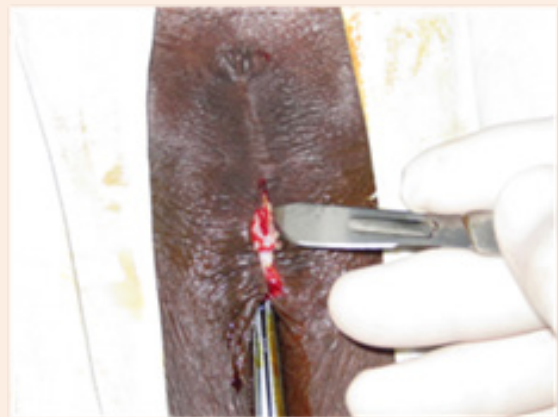

Figure 2: Infibulation.

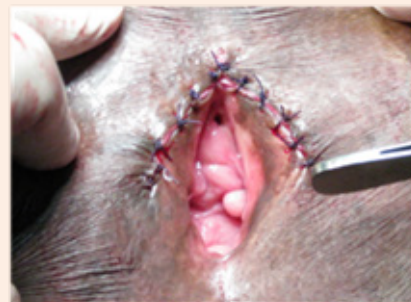

Figure 3: De-fibulation

Clitoral Reconstructive Surgery: Restoring clitoral anatomy and improve clitoral function. Most patients had undergone type II mutilation (removal of the clitoris glans and part of the labia minora). The skin covering the clitoris stump was cut longitudinally with knife or scissors, and the fibrous tissue around the clitoral stump removed. The suspensory ligament was cut close to the bone to allow sufficient downward freeing and mobilization of the clitoris, bringing it to the original glans' anatomical position; the dorsal neurovascular bundle was preserved. PDS sutures were used to hold the tip of the neo-clitoris inferiorly at 5 & 7 O'clock to the vestibular skin to prevent retraction; additional interrupted sutures were carefully placed fixing the sides of the clitoral shaft to underlying structures. (Figures 4 & 5)

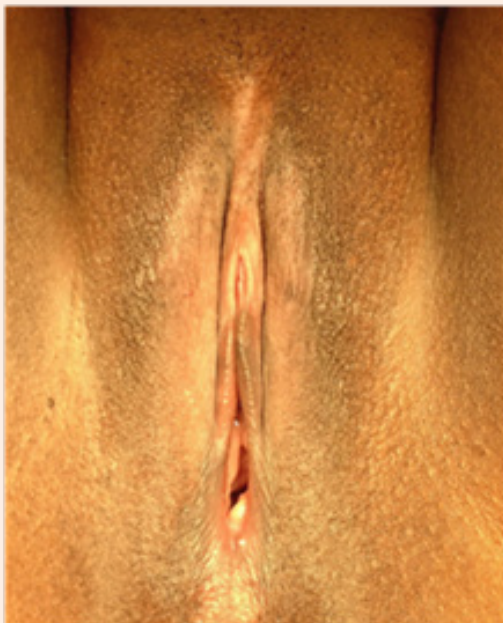

Figure 4: Type II FGM.

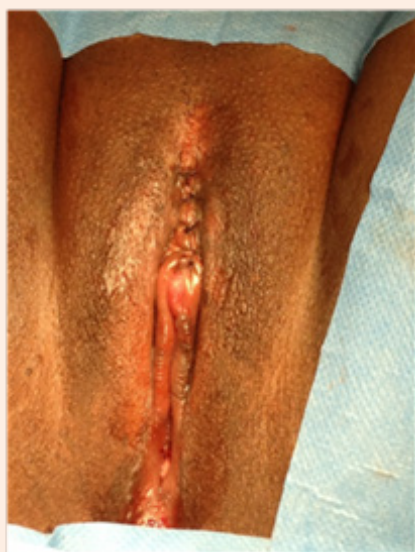

Figure 5: Clitoral Reconstructive Surgery.

Above the clitoris, the opened hood skin was closed with interrupted absorbable stitches passing on both sides. Dissected areas were infiltrated with local anesthetic (5 ml of lidocaine), to decrease post operative pain. Patients were discharged the following day with minimal pain and little or no bleeding, with hygiene instructions and medication for one week, and re-consultation for follow up after 2 weeks, then every 3 months for one year. Platelet Rich Plasma (PRP) from autologous blood was used in recent cases, PRP activates pluripotent stem cells in the area of injection, and increases blood flow, resulting in

rejuvenation and enhancement of damaged tissue due to FGM and dissection during clitoral reconstruction, which might injure nerve endings around the neuro-vascular bundle. Injection of PRP in the clitoris in newer cases (2015 - 2016), improved numbness, clitoral sensation, and promoted healing; noted after 12 weeks from the primary injection [19]. Laser and radiofrequency heat releasing devices may also help increase blood supply and may be beneficial in improving numbness, sensation, and healing; but still have to be tried [20].

Results

a. Cosmetic outcome satisfaction	90%
b. Psychological improvement	82%
c. Sexual desire improvement	24%
d. Sexual arousal improvement	27%
e. Sexual lubrication improvement	4%
f. Sexual orgasm improvement	8%
g. Sexual satisfaction improvement	16%
h. Pain reduction improvement	12%
i. Clitoral numbness incidence	18% (improves after 8 weeks)

No significant improvement in lubrication, and orgasm were noted

We believe the psychological benefit of clitoral reconstructive surgery far exceeds the physical and sexual improvement effects [12], it may also enhance intimate interest and acceptance, as indicated in our study; the question whether we should offer this type of surgery to all women with FGM is a difficult one. However we have seen an increase in confidence, self-esteem, and enhanced perception of ones sexuality and genital image, which makes us more optimistic to continue this line of treatment [21,22]. All 107 patients had a follow up after 2 weeks, and 3 months; 6 month and 12 month follow ups were made by phone. As we are a referral center, few patients see a need to travel for follow up checkups [23-25].

Conclusion

Women's sexual function is multifactorial and depends on more than the genitals. FGM can physically and psychologically affect the sexuality of women and should be abolished [2,26]. In women with FGM, most erectile organs responsible for sexual function are present beneath scar tissue. The widespread but incorrect notion that women with FGM no longer have a clitoris should be revised. Women with FGM who experience sexual dysfunction should be counseled and treated appropriately regardless of whether FGM was the cause. Safe and effective medical, psycho-sexual, and surgical treatments should be studied further in future studies [12]. More long term, multicenter studies, applying advanced reconstructive surgical techniques should be performed, to better evaluate the outcome of surgery in regards to improvement of psychological and sexual function in women with FGM.

References

1. World Health Organization, Department of Reproductive Health and Research (2008) Eliminating female genital mutilation: an interagency statement. OHCHR, UNAIDS, UNDP, UNECA, UNESCO, UNFPA, UNHCR, UNICEF, UNIFEM, WHO. World Health Organization, p Geneva. 48.
2. Thabet SM, Thabet AS (2003) Defective sexuality and female circumcision: the cause and possible management. *J Obstet Gynaecol Res* 29(1): 12-19.
3. WHO (2012) Female genital mutilation, Fact sheet N241. World Health Organization, Geneva, Switzerland.
4. Puppo V, Puppo G (2015) Anatomy of sex: revision of the new anatomical terms used for the clitoris and the female orgasm by sexologists. *Clin Anat* 28(3): 293-304.
5. Abdulcadir J, Rodriguez MI, Say L (2015) Research gaps in the care of women with female genital mutilation: an analysis. *BJOG* 122(3): 294-303.
6. Paterson LD, Davis SN, Binik YM (2012) Female genital mutilation/cutting and orgasm before and after surgical repair. *Sexologies* 21(1): 3-8.
7. O'Connell HE, Sanjeevan KV, Hutson JM (2005) Anatomy of the clitoris. *J Urol* 174(4): 1189-1195.
8. Abdulcadir J, Margairaz C, Boulvain M, Irion O (2011) Care of women with female genital mutilation/cutting. *Swiss Med Wkly* 140: w13137.
9. Foldes P, Louis-Sylvestre C (2006) Résultats de la réparation chirurgicale du clitoris après mutilation sexuelle: 453 cas. *Gynécologie Obstétrique & Fertilité* 34(12): 1137-1141.
10. Population Reference Bureau Report (2010) Female Genital Mutilation/Cutting: Data and Trends. p. 1-9.
11. Berg RC, Denison E, Fretheim A (2010) Psychological, social and sexual consequences of female genital mutilation/cutting (FGM/C): a systematic review of quantitative studies. Report from Kunnskapsenteret nr 13-2010. Oslo: Nasjonalt kunnskapssenter for helsetjenesten.
12. Abdulcadir J, Rodriguez MI, Petignat P, Say L (2015) Clitoral reconstruction after female genital mutilation/cutting: case studies. *J Sex Med* 12(1): 274-281.
13. Gruenbaum E (2006) Sexuality issues in the movement to abolish female genital cutting in Sudan. *Med Anthropol Q* 20(1): 121-138.
14. Nour NM, Michels KB, Bryant AE (2006) Defibulation to treat female genital cutting: effect on symptoms and sexual function. *Obstet Gynecol* 108(1): 55-60.
15. Johnsdotter S, Essen B (2004) Sexual health among young Somali women in Sweden: living with conflicting culturally determined sexual ideologies. International Network to Analyze, Communicate and Transform the Campaign against Female Genital Cutting, Female Genital Mutilation, Female Circumcision (INTACT) conference; Alexandria, Egypt p. 10-12.
16. Johnson C, Nour NM (2007) Surgical techniques: defibulation of type III female genital cutting. *J Sex Med* 4(6): 1544-1547.
17. Krause E, Brandner S, Mueller MD, Kuhn A (2011) Out of Eastern Africa: defibulation and sexual function in woman with female genital mutilation. *J Sex Med* 8(5): 1420-1425.
18. Nour NM, Michels KB, Bryant AE (2006) Defibulation to treat female genital cutting: effect on symptoms and sexual function. *Obstet Gynecol* 108(1): 55-60.
19. Charles Runels, Hugh Melnick, Ernest Debourbon, Lisbeth Roy (2014) A Pilot Study of the Effect of Localized Injections of Autologous Platelet Rich Plasma (PRP) for the Treatment of Female Sexual Dysfunction. *J Women's Health Care* 3(4): 169.
20. Alinsod RM (2016) Transcutaneous temperature controlled radiofrequency for orgasmic dysfunction. *Lasers Surg Med*.
21. Johnsdotter S, Essen B (2004) Sexual health among young Somali women in Sweden: living with conflicting culturally determined sexual ideologies. International Network to Analyze, Communicate and Transform the Campaign against Female Genital Cutting, Female Genital Mutilation, Female Circumcision (INTACT) conference; Alexandria, Egypt pp. 10-12.
22. Ouédraogo CM, Madzou S, Touré B, Ouédraogo A, Ouédraogo S, et al. (2013) Practice of reconstructive plastic surgery of the clitoris after genital mutilation in Burkina Faso Report of 94 cases *Ann Chir Plast Esthet* 58(3): 208-215.
23. Catania L, Abdulcadir O, Puppo V, Verde JB, Abdulcadir J (2007) Pleasure and orgasm in women with female genital mutilation/cutting (FGM/C). *J Sex Med* 4(6): 1666-1678.
24. Foldès P, Cuzin B, Andro A (2012) Reconstructive surgery after female genital mutilation: a prospective cohort study. *Lancet* 380(9837): 134-141.
25. Foldes P (2004) Reconstructive plastic surgery of the clitoris after sexual mutilation. *Prog Urol* 14(1): 47-50.
26. Berg RC, Underland V, Odgaard-Jensen J, Fretheim A, Vist GE (2014) Effects of female genital cutting on physical health outcomes: a systematic review and meta-analysis. *BMJ Open* 4(11): e006316.