

Robotic surgical training: cholecystectomy

Abstract

Background: The main advantages of robotics in general surgery may be for advanced minimally invasive procedures. Unlike other specialties, formal fellowship training opportunities for robotic general surgery are few. As a result, most surgeons currently develop robotic skills in practice and robotic cholecystectomy represents the operation of choice for general surgeons to acquire clinical da Vinci experience.

Methods: Before performing advanced robotic procedures, 2 surgeons completed the Intuitive Surgical da Vinci-Xi training course and agreed to work together on all procedures. We performed a retrospective review of our pilot series of robotic cholecystectomies and compared them with contemporaneous laparoscopic controls.

The primary outcome was safety, and the Secondary outcome was learning curve.

Results: There were 30 procedures in the robotic arm and 45 in the laparoscopic group. One complication (port-site hernia) occurred in the laparoscopic group, and only one robotic patient (surgical wound infection) experienced a complication. The mean time required to perform robotic cholecystectomy was significantly long than laparoscopic surgery (68v. 37min, $p < 0.001$) due to the docking of da Vinci system.

The mean time to clear the operating room was significantly longer for robotic procedures (20v. 12min, $p = 0.015$).

Conclusion: Our experience may suggest that robotic cholecystectomy is a way by which general surgeons may gain confidence in performing advanced robotic procedures and it confirms the reliability of this training course.

Keywords: robotic cholecystectomy, laparoscopic, surgery, gallbladder

Volume 2 Issue 4 - 2018

Nicola Tartaglia, Antonio Zita, Alessandra Di Lascia, Fabio Petruzzelli, Alberto Fersini, Antonio Ambrosi

Department of Medical and Surgical Sciences, University of Foggia, Italy

Correspondence: Nicola Tartaglia, Department of Medical and Surgical Sciences, University of Foggia, Italy, Tel +39-320-4394-640, Email nicola.tartaglia@unifg.it

Received: February 14, 2018 | **Published:** June 20, 2018

Abbreviations: LC, laparoscopic cholecystectomy; RC, robotic cholecystectomy; GAD, gallbladder antegrade dissection; CBD, common bile duct; ERCP, endoscopic-retrograde-colangiopancreatography

Introduction

Laparoscopic and robotic surgery represents an advance in minimally invasive surgery. Robotic surgery will likely be used for more difficult laparoscopic procedures where the superior visualization and dexterity will extend the feasibility of the minimally invasive approach especially in those cases that require precise tissue dissection and advanced dissection.^{1,2}

Laparoscopic cholecystectomy (LC) may be used as the first surgical operation with which to begin robot applications because cholelithiasis is, in developed countries, one of most common abdominal diseases, and one of the most commonly performed laparoscopic procedure with a very standardized surgical technique. Therefore, we think that robotic cholecystectomy (RC) may allow surgeons to develop surgical da Vinci experience in a familiar setting.

Our primary objective was to determine the possibility to employ RC as a bridge to more advanced surgical robotic procedures comparing the retrospective review of our pilot series of RC, with contemporaneous laparoscopic group controls. Furthermore, this experience may represent well how our learning curve has evolved even in a small number of patients.

Materials and methods

2090 Laparoscopic Cholecystectomy were performed at our surgical operative unit from 2002 to 2018,; 1490 for gallstones, 600 for acute cholecystitis.

The gallbladder antegrade dissection (GAD), introduced at our department in 2002, has become our surgical laparoscopic procedure of choice.³⁻⁵ To begin robotic operations, 2 general surgeons from the Intuitive Surgical Da Vinci Xi training, with advanced laparoscopic surgical skills prior to robotic training, were enrolled to work together on all robot-assisted procedures. All patients referred to the outpatient general surgery clinic for elective cholecystectomy were include as potential candidates for Da Vinci-assisted surgical approach (Table 1).

Patients with contraindications to laparoscopy were not considered for robotic procedures. We obtained consent for a da Vinci-assisted cholecystectomy. Patients were informed of the innovative nature of the robotic approach with Da Vinci surgical system, used as a way to increase surgical skills and with the intent of moving on to more complex procedures. No proven benefit to performing the surgery with this technology was offered. Safety was the primary outcome of this retrospective study as indicated by complications, transition to laparoscopy and conversion to open surgery.

Our secondary outcome was the surgical robotic learning curve, indicated by duration of surgery; these outcomes, in a non randomized cohort of RC were compared with a cohort of contemporaneous LC controls.

The surgical technique of gallbladder antegrade dissection involve the following steps: incision of the visceral peritoneum from the infundibulum away from Calot’s triangle along the gallbladder bed up to the fundus; the dissection from the fundus up to the infundibulum and the resection of the gallbladder from the gallbladder fossa using cautery.

The gallbladder is left pedunculated by the cystic artery and cystic duct, which can be clipped and divided in turn. This way we have a safe and complete preparation of the cystic duct that may be isolated, identified, clipped, and divided in a easier way and the connections with the common bile duct (CBD) may be seen. The specimen was then placed in an Endocatch bag, removed through the umbilical port, and finally the port sites and skin were closed. LC was performed with the same technique using 4 ports, electrocautery, a 30° laparoscope and others typical used laparoscopic instruments.

We compared the mean duration of values in both groups using the Student t test. A p value of less than 0,05 was considered statistically significant.

Table I Patient’s demographic and pathological data

	Robotic cholecystectomy (RC) n 30	Laparoscopic cholecystectomy (LC) n 45	P Value
Age, y			
Mean (SD)	53 + 14,73	55 + 13,61	
Median (range)	55 (28 - 70)	59 (26 - 72)	0,546
Sex (Male/Female)			n.s.
Comorbidities, n			
Chronic lung disease	4	6	
Coronary artery disease	6	8	
Smokers	6	10	n.s.
Diabetes	2	6	
BMI			
Mean (SD)	24,5 + 3,44	24,7 + 3,55	0,884
Median (range)	24 (19 - 28)	26 (18-28)	
ASA			
I	19	26	
II	9	14	n.s.
III	0	5	
Indications for surgery			
Gallstones	23	32	
Choledocholithiasis	1	2	
Biliary acute pancreatitis	2	6	n.s.
Acute cholecystitis	4	4	
Gallstones in cirrhotics	0	1	

Results

During the last year of utilization of Da Vinci surgical system, 30 patients underwent RC in our surgical unit and were compared with 45 controls who received contemporaneous Laparoscopic

cholecystectomy. The most common indications in the robotic group were uncomplicated gallstones while in laparoscopic group were gallstones, acute cholecystitis and one case of gallstones in a cirrhotic patient (Child A). Three patients with choledocholithiasis underwent endoscopic-retrograde-colangio-pancreatography (ERCP) with sphincterotomy for CBD clearance before cholecystectomy (Table 1). All patients affected by acute cholecystitis were operated within 24hours to 72hours after the admission. There were no serious complications in either group and no case of hemorrhages and biliary duct injuries. In the robotic group one patient presented a surgical wound infection, while in the laparoscopic group one patient develop an incisional hernia at a 12-mm port site that required elective repair surgery. We noticed that, in the robotic group of patients, there weren’t any transitions to laparoscopic approach, and no conversions to open surgery. Figure 1 summarizes our findings regarding the secondary outcome. The total surgical time required for robotic procedures, including the docking phase, was significantly longer than that seen commonly in laparoscopic procedures (68v. 37min, p<0.001). In particular the docking phase, a specific phase of the robotic surgeries, was on average 15minutes. Similarly, the time needed to clean the operating room after the procedure was significantly longer in the robotic group (20v. 12min, p<0.001). An similarly anesthesia time had a longer duration in the robotic group (21v. 17min), though this was not a significant finding (Figure 1).

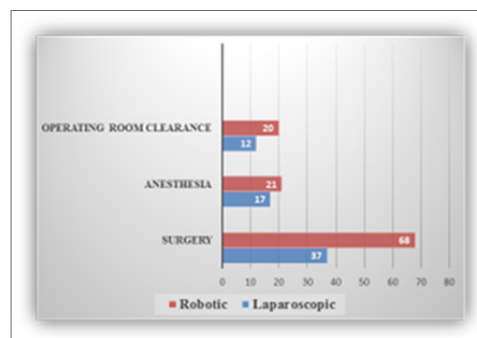


Figure 1 Operative time compared between the two procedures.

Discussion

Our study was focused to evaluate our learning curve with robotic surgery. In our experience Robotic procedures ,at beginning, may require more time than laparoscopic ones .Our total duration of surgery is similar to other centers implementing Da Vinci system (Table 2). We noticed a decreased duration of surgery as our surgical and nursing team becomes more accustomed to da Vinci suggesting that the entire operating room team has a learning curve using the robotic system . Not having access to the patient’s head during da Vinci operations due to the bulk of the robot, it requires more time for anesthesiologists to prepare the patient for surgery. Likewise the nurses are not necessarily familiar with all robotic instruments, and the size of the Da Vinci reduces the work space in the operating theatre, making the work of the staff more difficult. All surgeons prefer to begin with routine procedures like cholecystectomy and fundoplicatio before advancing to more complex ones such as pancreaticoduodenectomy or liver resection.^{6,7} The learning curve to master the robot was of ,at least, 10 procedures or more.⁸ As a result of our experience, we are moving confidently to perform more advanced robotic procedures, including anti-reflux surgery, colon and rectum

operations and intestinal anastomosis, because the robotic surgery will likely be applied to the most complicated abdominal surgical operations. 3D visualization of the surgical field and the dexterity of the Endo wrist, allowing complex minimally invasive tasks, are some of the advantages of the Da Vinci system. We noticed that both of these advantages outweighed the absence of tactile feedback. In fact the dissection of the Calot triangle is made more effective and easier with the improved visualization and dexterity of Da Vinci System; however, we cannot conclude that the robotic system was more effective than standard laparoscopic instruments at this time. The robotic system has some limitations such as the absence of tactile feedback for the surgeon, and the necessity of a second surgeon at the bedside to assist with the procedure exchange the robotic instruments, retract for exposure.⁹⁻¹⁴

Table 2 Mean duration of surgery in published series of da Vinci cholecystectomy

Study	No. of patients	Mean duration of surgery (min)
Our study	30	68
Kim et al. ⁵	10	57
Talamini et al. ⁹	8	167
Hashizume et al. ⁷	6	118
Hanisch et al. ⁸	5	95
Chitwood et al. ⁶	20	62

Conclusion

This experience may show that every new and complex surgical approach can safely be started by carefully applying all the standardized procedures. The robotic cholecystectomy may represent an opportunity for surgeons to develop familiarity with a wide set of procedures that may be applied to more advanced robotic procedures and gain confidence in advanced robotics.

Acknowledgments

None.

Conflict of interest

The author declares that they have no conflict of interest.

References

1. Baek SK, Carmichael JC, Pigazzi A. Robotic surgery: colon and rectum. *Cancer J.* 2013;19(2):140–146.
2. Alasari S, Min BS. Robotic colorectal surgery: a systematic review. *ISRN Surg.* 2012;293894.
3. Tartaglia N, Cianci P, Di Lascia A, et al. Laparoscopic antegrade cholecystectomy: a standard procedure? *Open Med.* 2016;11(1):429–432.
4. Forlano I, Fersini A, Tartaglia N, et al. Biliary papillomatosis. Case report. *Ann Ital Chir.* 2011;82(5):405–408.
5. Neri V, Ambrosi A, Fersini A, et al. Laparoscopic cholecistectomy: evaluation of liver function tests. *Ann Ital Chir.* 2014;85(5):431–437.
6. Giulianotti PC, Coratti A, Angelini M, et al. Robotics in general surgery: personal experience in a large community hospital. *Arch Surg.* 2003;138(7):777–784.
7. Ruurda JP, Draaisma WA, van Hillegersberg R. Robot-assisted endoscopic surgery: a four-year single-center experience. *Dig Surg.* 2005;22(5):313–320.
8. Vidovszky TJ, Smith W, Ghosh J, et al. Robotic cholecystectomy: learning curve, advantages, and limitations. *J Surg Res.* 2006;136(2):172–178.
9. Corcione F, Esposito C, Cucurullo D, et al. Advantages and limits of robot-assisted laparoscopic surgery: preliminary experience. *Surg Endosc.* 2005;19(1):117–119.
10. Kim VB, Chapman WH, Albrecht RJ, et al. Early experience with telemanipulative robot-assisted laparoscopic cholecystectomy using da Vinci. *Surg Laparosc Endosc Percutan Tech.* 2002;12(1):33–40.
11. Chitwood WR, Nifong LW, Chapman WH, et al. Robotic surgical training in an academic institution. *Ann Surg.* 2001;234(4):475–484.
12. Hashizume M, Shimada A, Tomikawa M, et al. Early experiences of endoscopic procedures in general surgery assisted by a computer enhanced surgical system. *Surg Endosc.* 2002;16(8):1187–1191.
13. Hanisch E, Markus B, Gutt C, et al. Robot-assisted laparoscopic cholecystectomy and fundoplication—initial experiences with the da Vinci system. *Chirurg.* 2001;72(3):286–288.
14. Talamini M, Campbell K, Stanfield C. Robotic gastrointestinal surgery: early experience and system description. *J Laparoendosc Adv Surg Tech A.* 2002;12(4):225–232.