

Melanoma of vulva in a Nigerian

Abstract

Internet search for vulva melanoma revealed typical examples from several countries. The descriptions revealed the parameters such as the presentation at late stage among post-menopausal women with associated lichen sclerosus as well as the Caucasians having a 3-fold higher incidence rate than the individuals of African descent. Therefore, a single case found in a Nigerian among a cohort of over 100 pedal melanomas is deemed worthy of documentation.

Keywords: melanoma, vulva, IGBO, developing community

Volume 5 Issue 2 - 2017

Wilson IB Onuigbo

Department of Pathology, Medical Foundation and Clinic, Nigeria

Correspondence: Wilson IB Onuigbo, Department of Pathology, Medical Foundation and Clinic, 8 Nsukka Lane, Enugu 400001, Nigeria, Tel 2348037208680, Email wilson.onuigbo@gmail.com

Received: April 18, 2017 | **Published:** June 01, 2017

Introduction

Internet search for vulva melanoma produced recent publications from Australia,^{1,2} Sweden,^{3,4} USA,⁵ India⁶ and Italy.⁷ The highlights were late presentation in postmenopausal women due to lack of body awareness, false modesty and neglect as well as the Caucasians having a 3-fold higher incidence rate than the individuals of African descent. Therefore, a Nigerian of the Igbo ethnic group⁸ in whom vulvar melanoma occurred is deemed to be reportable.

Case report

IA, a para 1, 55-year-old Igbo woman attended the St. Mary's Hospital, Enugu, Nigeria, with the history of itching of the right vulva associated with swelling and discharge of 2 months duration. Of shorter duration was inguinal swelling. Both areas were biopsied in continuity and sent to the senior author (WIBO) at a Reference Pathology Laboratory situated in Enugu also. The vulva-lymphadenectomy specimen was a 8 cm much distorted mass in which skin was scarcely

identified. On section, black deposits abounded. Microscopy showed epithelial malignancy with much melanin deposition in skin, lymphoid tissue and surrounding fat. Malignant melanoma was diagnosed. Recovery was uneventful.

Discussion

Mucosal melanoma is a rare cancer that is clearly distinct from its cutaneous counterpart. Its literature was reviewed by Seetharmy et al.,⁹ who described the three commonest sites of mucosal melanoma as the head and neck, the female genital tract, and the anorectum. Or, as Houghton et al.,¹⁰ put it, "melanoma in darker races tends to occur on the foot and mucous membranes." Accordingly, our vulva case is a good example of this generalization (Figure 1). In particular, at the age of 55 years, it compares favorably with the older Indian 75-year-old⁶ and the Italian 79-year-old.⁷ In conclusion, it is significant that a historical publication mentioned the age in a case of clitoris melanoma as 79 years.¹¹ Incidentally, this Journal carried an account of it recently.¹² Therefore, this related case deserves to appear in it!

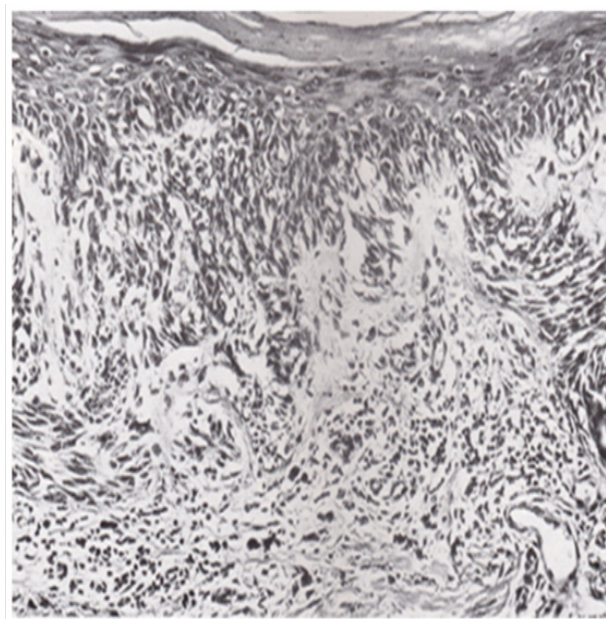


Figure 1 Typical micrograph of melanoma.

Acknowledgements

None.

Conflict of interest

The author declares no conflict of interest.

References

1. Jones ISC, Crandon A, Sanday K. Melanoma of the vulva: A retrospective study of 46 cases from Queensland. *Open J Obstet Gynecol*. 2012;2(2):1–7.
2. Heinzelmann-Schwarz VA, Nixdorf S, Valadan M, et al. A clinicopathological review of 33 patients with vulvar melanoma identifies c-KIT as a prognostic marker. *Intl J Mole Med*. 2014;33(4):784–794.
3. Ragnarsson-Olding BK, Nilsson BR, Kanter-Lewensohn LR, et al. Malignant melanoma of the vulva in a nationwide, 25-year study of 219 Swedish females. *Cancer*. 1999;86(7):1273–1284.
4. Ragnarsson-Olding BK. Primary malignant melanoma of the vulva--an aggressive tumor for modeling the genesis of non-UV light-associated melanomas. *Acta Oncologica*. 2004;43(5):421–435.
5. Alexander A, Harris RM, Grossman D, et al. Vulvar melanoma: diffuse melanosis and metastasis to the placenta. *J Am Acad Dermatol*. 2004;50(2):293–298.
6. Singh S, Singh P, Kaur N. Vulvar malignant melanoma: a rare tumor with worse prognosis. *Intl J Reprod Contracept Obstet Gynecol*. 2013;2(3):494–496.
7. Virgili A, Zampino MR, Corazza M. Primary vulvar melanoma with satellite metastasis: Dermoscopic findings. *Dermatology*. 2004;208(2):145–148.
8. Basden GT. *Niger Ibos*. UK: Frank Cass & Co; 1996.
9. Seetharamu N, Ott PA, Pavlick AC. Mucosal melanomas: A case-based review of the literature. *Oncologist*. 2010;15(7):772–781.
10. Houghton AN, Viola MV. Solar radiation and malignant melanoma of the skin. *J Am Acad Dermatol*. 1981;5(4):477–483.
11. Battle H. Primary melanotic sarcoma of clitoris. *Trans Path Soc Lond*. 1985;46:189.
12. Onuigbo WIB. Primary melanoma of the clitoris: Historical case. *MOJ Womens Health*. 2016;2(5):00044.