

Comparison of efficacy of TVS & hysteroscopy with histopathology of the endometrium in evaluating perimenopausal AUB(O)

Abstract

Introduction: Anovulatory cycles being common in the perimenopausal women, they could present with abnormal uterine bleeding. Evaluation methods may have to be applied meticulously with an idea of not missing the diagnosis and at the same time not to be invasive all the time. Thus this study was conducted to compare the efficacy of TVS and hysteroscopy with histopathology taken as the gold standard.

Aims and Objectives: To determine the best protocol for evaluating perimenopausal AUB(O) with hysteroscopy, TVS and/or endometrial biopsy.

Materials and methods: Perimenopausal Women >40years attending the Gynaec OPD in hospitals attached to Bangalore Medical College and Research institute with AUB(O) (diagnosed by exclusion by history, examination & investigations) were subjected to TVS, followed later by diagnostic hysteroscopy and endometrial biopsy in the same sitting. The results were tabulated and the sensitivity, specificity, positive and negative predictive values of Hysteroscopy and TVS in relation to histopathology were calculated.

Results: Out of the 50patients, HMB was the commonest symptom (46%), and 54% presented within 6months of onset of illness. TVS showed a sensitivity and specificity of 29% and 100% for hyperplastic endometrium, 0% and 100% for carcinoma, and around 70% and 43% for other variants. Hysteroscopy showed a sensitivity and specificity of 68% and 100% for hyperplasia, 100% and 100% for atrophy and carcinoma, but for local pathology like submucous fibroid, polyp and sub septate uterus hysteroscopy was the most sensitive.

Conclusion: TVS is a very useful mode for initial evaluation, and hysteroscopy needs to be the next mode which can decide about the need for biopsy and if necessary biopsy site could be directed by the hysteroscopy findings.

Keywords: hysteroscopy, trans vaginal scan, histopathology, perimenopausal AUB(O)

Volume 4 Issue 6 - 2017

K Srinivas, Sunanda Kulkarni

Department of Obstetrics and Gynecology, Bangalore Medical College and Research Institute, India

Correspondence: K Srinivas, Assistant Professor, Department of Obstetrics and Gynecology, Bangalore Medical College and Research Institute, Fort, K R Road, Bangalore, Karnataka State, India, Tel +919845101621, Email srinivaskjois@gmail.com

Received: January 01, 2017 | **Published:** April 12, 2017

Abbreviations: AUB, abnormal uterine bleeding; O, ovulatory; L, leiomyoma; P, polyp; TVS, transvaginal scan; OPD, out patient department; PPV, positive predictive value; NPV, negative predictive value; D & C, dilatation and curettage; SIS, saline infusion sonography; PID, pelvic inflammatory disease; IUCD, intrauterine contraceptive device; ET, endometrial thickness; OT, operation theater; VDRL, venereal disease research laboratory; HIV, human immunodeficiency virus; HbsAg, hepatitis b surface antigen; HMB, heavy menstrual bleeding

Introduction

Abnormal uterine bleeding (AUB) associated with ovulatory dysfunction (AUB-O) is most common at extremes of reproductive age.¹ AUB is one of the most common complaint with which a patient presents to an OB Gyn practitioner. AUB is defined as 'bleeding that is excessive either in quantity or duration or occurs outside of normal cyclic menstruation' and accounts for a great majority of hysterectomies. AUB(O) poses a great challenge to the diagnosis as most often it becomes a diagnosis of exclusion. A detailed history,

selective laboratory workup, and a thorough pelvic examination along with transvaginal ultrasonography (TVS), the cause of the bleeding is established in about half of the cases.² To establish the aetiology of AUB, the diagnostic modalities available in the armamentarium of a gynaecologist should be meticulously and judiciously used. D & C which was the modality of choice earlier shows a high false negativity in conditions of AUB(L), AUB(P) and any other focal lesions.³ In present day practice, evaluation of a patient with AUB involves TVS, Hysteroscopy and endometrial histopathology.⁴ SIS (saline infusion sonography) may be a good tool for the diagnosis of focal lesions.⁵ Most studies suggest that endometrial sampling be considered for all women over a certain age, usually 45years.⁶ In a perimenopausal woman, the major worry for the treating physician and the client is to have an affirmation about the absence of malignancy. One of the cornerstones in the management of AUB(O), hormone therapy cannot be used in this age group with out ruling out both cancer and pre cancerous conditions. Looking at the endometrium and studying the histopathology would be desirable in these women.²

Following recommendations have been made¹

i. Ultrasonography is mandatory in AUB to evaluate uterus, adnexa and endometrial thickness. SIS can be considered if intracavitary lesion is suspected and hysteroscopy is not available, if available Hysteroscopy is used for the diagnosis and characterization of intrauterine abnormalities.

ii. Endometrial histopathology is recommended in AUB. In women >40 years and in women <40 years who have high risk factors for carcinoma endometrium.

The more accurate the diagnosis of endometrial pathology, the better the chances for alternative treatment and hysterectomies could be avoided. The accuracy or the superiority of the relatively non-invasive methods like TVS, Hysteroscopy and SIS over histopathology have not been clearly established. Thus this study was undertaken to compare the diagnostic efficacy of hysteroscopy and TVS over the histopathology study of the endometrium and to test their agreement. To decide about the best protocol for the evaluation of perimenopausal AUB(O) and to compare the non-invasive mode with the invasive mode to find their sensitivity, specificity, positive and negative predictive values.

Materials and methods

It was a prospective comparative study done to compare the efficacy of Transvaginal Ultrasound and Hysteroscopy in relation to endometrial biopsy and histopathology, which was taken as the gold standard for this study. Women >40 years, not attained menopause and with any pattern of abnormal menstruation with no clinically or USG detectable pathology were included in the study. For obvious reasons, women on Anticoagulants, with Thyroid abnormality, Severe dysmenorrhoea, Unmarried women, women with Chronic PID, women who have been already on hormonal therapy, IUCD users and known cases of malignancy were excluded from the study. The study was conducted at Bowring and Lady Curzon Hospitals attached to Bangalore Medical College and Research Centre after obtaining ethical clearance and fifty women fulfilling the exclusion and inclusion criteria were enrolled for the study. Informed written consent was obtained from them. A detailed history was taken and a thorough clinical examination was done. Complete blood count, bleeding time, clotting time, random Blood Sugar, urine analysis for protein, sugar and microscopy, HIV, HBsAg, VDRL, Blood grouping and Rh typing were done in all the patients. The procedure was planned in the premenstrual phase when the pattern of the cycle was regular, otherwise it was done at any convenient time. They were subjected to Transvaginal scan using 7.5 MHz probe to note down the endometrial thickness and to rule out other uterine and adnexal pathology. Next day all the patients underwent diagnostic hysteroscopy under paracervical block anaesthesia (1% xylocaine 3cc given at 4 o'clock and 8 o'clock position of the cervix) using a 4mm scope with 5mm sheath and 30 degrees angulation. Whenever necessary cervix was dilated with No 5/6 Hegar's dilator. They were kept nil by mouth for at least 6 hours, were given a dose of tetanus toxoid, and a single dose of Cefotaxime 1G IV was given an hour before the procedure after test dose. Normal saline was used as the distension medium. The container was rapped with BP cuff and the flow of saline was made smooth and under good pressure by rising the cuff pressure which was indirectly transmitted to the saline. This achieved a good and sustained distension throughout the procedure. The hysteroscopy findings were documented. This was followed by a blind biopsy of the endometrium

using a routine curette or Novak's curette. Whenever patient had continuous and heavy bleeding, a thorough curettage was done. The endometrium was sent to the pathologist in 10% formalin container. The histopathology reports were available in the next 3-5 days. The pathologist was not aware of the hysteroscopy or TVS findings. The patient was monitored for 3-4 hours and most of them were sent home the same day with instructions to come for follow up in a week.

The demographic details, type of menstrual disturbance, duration of symptoms, parity, examination details, co-morbidities, were documented. The TVS endometrial thickness in all the cases were noted. The hysteroscopy findings were classified as atrophic endometrium, proliferative (dull pink relatively thin), secretory (bright pink uniform), and hyperplastic (fluffy thick obscuring the view), and other findings like submucous fibroid, polyps, local unhealthy areas suggestive of malignancy were noted. Histopathology findings of atrophic, hyperplastic, secretory, proliferative and malignancy of the endometrium were noted. The sensitivity, specificity, positive predictive value and negative predictive values of TVS and hysteroscopy in relation to histopathology were calculated. To study the correlation between the findings Kappa coefficient was calculated and declared as poor, fair, moderate, substantial, almost perfect and perfect depending on the Kappa value. Following these conclusions were drawn.

Results and discussion

Of the 50 women, 90% were in the age group of 40 and 50 years. Youngest being 41, and oldest 54. 46% of them presented with heavy menstrual bleeding, 34% had increased cycle frequency (Past terminology of poly-menorrhoea) and 20% of them had presented with continuous bleeding (Figure 1). 54% of them had presented within 6 months of the onset of problems and only 14% presented after twelve months. The Transvaginal scan assessment showed (Figure 2) that 5 patients showed an endometrial thickness <4mm, 14 patients with ET between 4-8mm, 16 between 8-12mm, 10 of them between 12-16mm and 5 of them >16mm. Diagnostic hysteroscopy (Figure 3) revealed the appearance of proliferative endometrium in 34%, secretory in 8%, Hyperplasia in 38%, atrophic in 4%. One case (2%) of endometrial carcinoma was diagnosed. Focal lesions like submucous fibroid was diagnosed in 8%, Polyp in 4% and a sub-septate uterus was noted in 2% cases. Histopathology reports (Figure 4) showed proliferative endometrium in 12 patients, secretory in 7 patients, atrophic picture in 2 patients and well-differentiated endometrial carcinoma in 1 patient. 25 patients showed simple hyperplasia without atypia, 2 patients had complex hyperplasia with atypia and 1 patient had complex hyperplasia without atypia. A correlation was made between histopathology and transvaginal scan, and also with hysteroscopy findings (Figure 5).

All the atrophic endometrium reported by histopathology had ET <4mm. When the endometrium showed proliferative phase, 25% showed ET >12mm, 16% between 9-12mm and in 49% of them ET <8mm. Secretory endometrium showed thickness of 9-12mm in 71%, >12mm and 5-8mm in 14.25% each. Amongst simple hyperplastic endometrium 36% showed ET >12mm, same number with ET between 9-12mm and 28% had ET between 5-8mm. None of them <4mm. Carcinoma endometrium had a thickness of 7mm. Complex hyperplasias also showed a thickness of >8mm in all the cases. Comparing the hysteroscopy findings with histopathology revealed the following findings. Atrophic endometrium and carcinoma

endometrium were diagnosed by hysteroscopy with good perfection. Hyperplasia was not picked up in 9 cases which were interpreted as proliferative in 5 cases and associated hyperplasia along with focal lesions was missed in 4 cases by hysteroscopy. Secretory endometrium which was not diagnosed in 3 cases by hysteroscopy in fact had focal lesions and histopathology findings failed to pick these for obvious reasons. TVS as a test in comparison with histopathology as a gold standard revealed a sensitivity and specificity of 100% and 68.42% for proliferative endometrium, 100% and 74.42% for secretory, 28.57% and 100% for hyperplastic endometrium, 0% and 100% for carcinoma and 0% and 100% for atrophic endometrium. These were calculated on an assumption that atrophic is <4mm Proliferative is between 4-8mm, secretory 8-12mm and hyperplasias and carcinoma >12mm (Table 1).

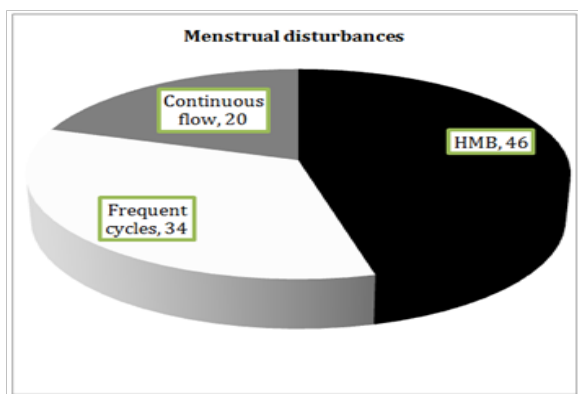


Figure 1 The percentage of different variety of menstrual disturbances.

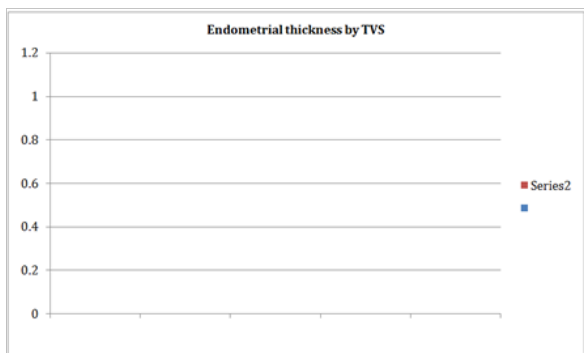


Figure 2 Endometrial thickness measurement by Transvaginal Scan in the subjects.

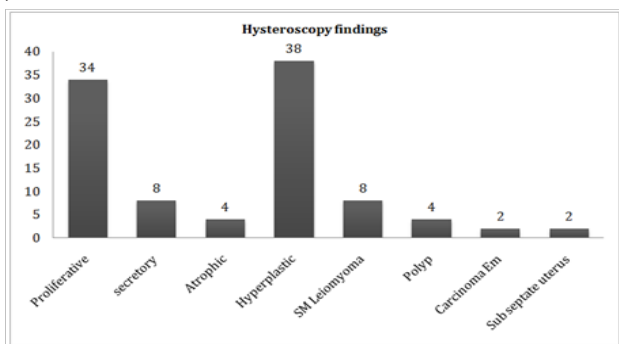


Figure 3 The different findings during diagnostic hysteroscopy and their frequency.

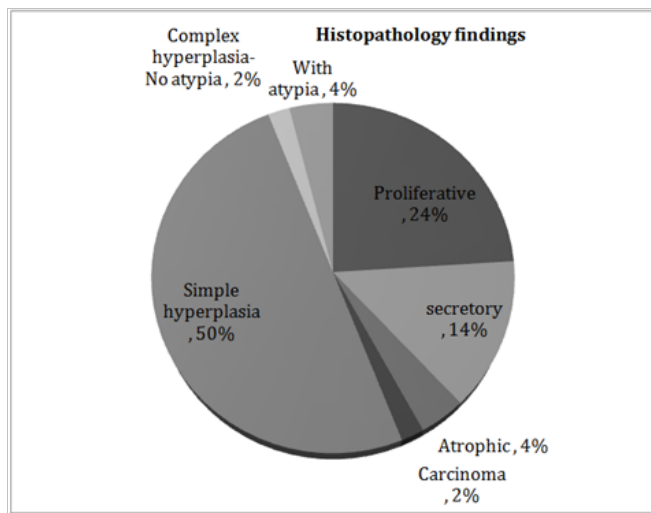


Figure 4 The percentage of different histopathology findings.

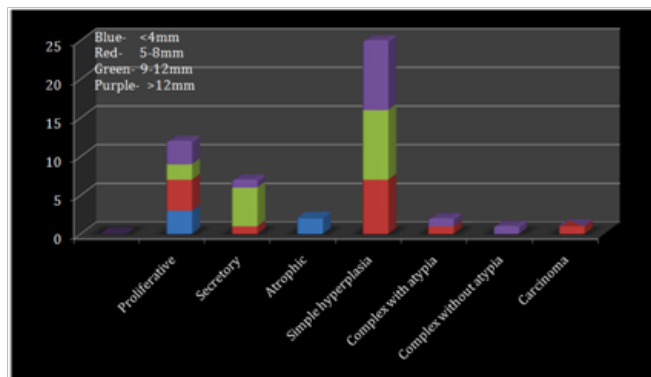


Figure 5 Histopathological findings at different thickness of endometrium.

Diagnostic value of hysteroscopy in comparison to histopathology gave a sensitivity and specificity of 100% and 86.84% for proliferative endometrium, 57.14% and 100% for secretory, 67.86% and 100% for hyperplastic endometrium. For carcinoma and atrophic endometrium both sensitivity and specificity were 100%. For focal lesions like sub mucous fibroid, polyp and sub septate uterus the sensitivity was 0% and specificity was 92%, 96% and 98% respectively (Table 2). Using kappa coefficient an agreement test was done between hysteroscopy and histopathology and again between TVS and histopathology. TVS showed a moderate agreement with histopathology for proliferative and secretory endometrium where as the agreement was fair for hyperplastic endometrium, but was poor for carcinoma, atrophic endometrium and polyp. Hysteroscopy showed a substantial agreement for proloferative, secretory and hyperplastic endometrium, almost perfect agreement for carcinoma and atrophic endometrium, but poor agreement for focal lesions (Histopathology is taken as the gold standard, hence a poor agreement for focal lesions which are picked up only by hysteroscopy) (Tables 3) (Table 4). This study comprising of 50 patients in the perimenopausal age group had maximum number between 40-50 years. The pattern of bleeding study showed that in women >50years the presenting symptom of continuous bleeding could be 8.1 times more common compared to the younger age group. In the present study TVS showed an accuracy of 77% for normal endometrium and 77.5% for abnormal in comparison

with histopathology. For focal lesions TVS showed a 0% sensitivity which is in accordance with the report by Conoscenti et al.,⁷ and others who concluded that TVS is a preferred modality for endometrial thickness but not sensitive enough to rule out pathology. Alcazar et al.,⁸ too have concluded that hysteroscopy has a better sensitivity and specificity compared to TVS. Additional use of saline infusion sono hystero-graphy probably would improve the accuracy of TVS. Abnormalities detected by hysteroscopy by various studies have been shown in Table 5 in comparison to the present study. The accuracy of hysteroscopy has been calculated in comparison with histopathology and in cases where hysterectomy has been done, the specimen histopathology has been considered. Accuracy of hysteroscopy in

the present study has an average of 94%, which proves hysteroscopy to be an excellent tool for endometrial evaluation (Table 6). Focal abnormalities detected in the present study which shows a small number in contrast to other studies is probably due to the fact that the age group considered here is only perimenopausal whereas other studies have included women in reproductive age group, which could explain this. Endometrial carcinoma picked up with a thickness of 7mm is similar to Giusa-Chiferi et al.,¹⁷ study who found carcinoma at 8mm, and concluded that carcinoma may be found with thickness >8mm, but such generalization may not be possible as the study by Deckhardt et al.,¹⁸ malignant endometrium had an endometrial thickness of <5mm.

Table 1 The diagnostic value of TVS in comparison to histopathology

Diagnostic value of TVS in comparison to histopathology						
histopathology of endometrium	Sensitivity	Specificity	PPV	NPV	Accuracy	Kappa
Proliferative	100	68.42	50	100	76	0.51
Secretory	100	74.42	38.89	100	78	0.45
Hyperplastic	28.57	100	100	52.38	60	0.26
Carcinoma	0	100	50	98	98	0
Atrophic	0	100	50	96	96	0

Table 2 The diagnostic value of hysteroscopy in comparison to histopathology

Diagnostic value of hysteroscopy in comparison to histopathology						
histopathology of endometrium	Sensitivity	Specificity	PPV	NPV	Accuracy	Kappa
Proliferative	100	86.84	70.50	100	90	0.76
Secretory	57.14	100	100	98.48	94	0.69
Hyperplastic	67.86	100	100	70.97	82	0.65
Carcinoma	100	100	100	100	100	1
Atrophic	100	100	100	100	100	1
Polyp	0	96	0	100	92	0
Sub Mucous Fibroid	0	92	0	100	92	0
Sub septate uterus	0	98	0	100	98	0

Table 3 Number of cases detected by the three different procedures and their frequency

Pathology	Number of cases detected by the procedures		
	Histopathology	TVS	Hysteroscopy
Proliferative	12(24%)	24(48%)	17(34%)
Secretory	7(14%)	18(36%)	4(8%)
Hyperplastic	28(56%)	8(16%)	19(38%)
Carcinoma	1(2%)	-	1(2%)
Atrophic	2(4%)	-	2(4%)
Polyp	-	-	2(4%)
Sub Mucous Fibroid	-	-	4(8%)
Sub septate uterus	-	-	1(2%)

Table 4 The agreement between the three methods of evaluation arrived at by Kappa co efficient

Pathology	Agreement between tests arrived at by kappa co-efficient	
	TVS and histopathology	Hysteroscopy and histopathology
Proliferative	Moderate	Substantial
Secretory	Moderate	Substantial
Hyperplastic	Fair	Substantial
Carcinoma	Poor	Almost perfect
Atrophic	Poor	Almost perfect
Polyp	Poor	Poor
Sub Mucous Fibroid	Poor	Poor
Sub septate uterus	Poor	Poor

Table 5 The rate of detection of pathology by hysteroscopy in different studies

Hysteroscopy detection rate by various studies		
Study	Year	% Abnormality detected
Loeffler ⁹	1986	59.4
Parulekar et al. ¹⁰	1992	24
Anuradha Panda ¹¹	1995	53.4
Loizzi et al. ¹²	2003	28
Acharya Veena et al. ¹³	2003	76
Present series	2008	58

Table 6 The accuracy of hysteroscopy by different studies

Hysteroscopy accuracy by various studies		
Study	Year	Accuracy in %
Baggish ¹⁴	1979	87.5
Parulekar et al. ¹⁰	1992	92
Anuradha Panda ¹¹	1995	92.5
Sheth et al. ¹⁵	1990	82
Barbot ¹⁶	1980	84
Present series	2008	94

Epstein et al.,¹⁹ concluded that for focal endometrial lesions, Hysteroscopy is the best modality and not D & C. The present study clearly demonstrates the superiority of hysteroscopy over histopathology in the diagnosis of focal lesions. The present study shows no pathology for endometrium <6mm and focal lesions when ET >14mm. This is not the conclusion in many studies. Acharya et al.,¹³ found TB in <6mm, and hyperplasias in 16mm too. This discrepancy probably could be because of the age group in question is different in different studies and the number of patients recruited for the study also could be responsible for this. Most of the studies have not reported any major complications due to hysteroscopy. The present study too reported none except a patient who developed cerebral venous thrombosis. But this was attributed to chronic anaemia

and not to hysteroscopy. Another patient developed abdominal pain post procedure which was probably due to bilateral hydrosalpinx with fimbrial block which was found during hysterectomy. Chi square and fisher exact test and kappa coefficient tests have been used as statistical methods in the present study.

Conclusion

TVS may be the first line of investigation while evaluating the endometrium in a perimenopausal AUB. Endometrial thickness >6mm as per the present study needs further evaluation. Hysteroscopy is the gold standard in the diagnosis of focal pathology like sub mucous fibroid, polyps or anomalies. Histopathology probably is an

indispensable tool especially to rule out premalignant and malignant conditions. Thus all the modalities instead of being competitive to one another, are complimentary to each other.

Limitations of the study

Only perimenopausal women studied and only 50 women have been recruited in the study. Procedure done in the OT-Office hysteroscopy would have been better for the patient

Prospects

Study could be expanded to other age groups and number increased, TVS, office hysteroscopy and Pipelle biopsy could be done in required cases, thus all done in the OPD itself making the evaluation most convenient and cost effective for the patient. Cut offs for considering biopsy may be established. Saline sono hystero-graphy may be evaluated in comparison with hysteroscopy.

Acknowledgements

Authors wish to acknowledge the help rendered by Dr. Savitha C, Dr. Vijayalakshmi Nayak and Dr. Sunanda K M during the study and Mr. Suresh for helping in statistical analysis.

Conflict of interest

The author declares no conflict of interest.

References

1. Practice Bulletin Number 136: Management of abnormal uterine bleeding associated with ovulatory dysfunction. *Obstet Gynecol.* 2013;122(1):176–185.
2. Kotdawala P, Kotdawala S, Nagar N. Evaluation of endometrium in perimenopausal abnormal uterine bleeding. *J Midlife Health.* 2013;4(1):16–21.
3. Word B, Gravlee LC, Wideman GL. The fallacy of simple uterine curettage. *Obstet Gynecol.* 1958;12(6):642–648.
4. Farquhar C, Ekeroma A, Furness S, et al. A systematic review of transvaginal sonography, sonohysterography and hysteroscopy for the investigation of abnormal uterine bleeding in premenopausal women. *Acta Obstet Gynecol Scand.* 2003;82(6):493–504.
5. Goyal BK, Gaur I, Sharma S, et al. Transvaginal sonography versus hysteroscopy in evaluation of abnormal uterine bleeding. *Med J Armed Forces India.* 2015;71(2):120–125.
6. Malcolm GM, Hilary OD, Michael SB, et al. FIGO classification system (PALM-COEIN) for causes of abnormal uterine bleeding in nonpregnant women of reproductive age. *International Journal of Gynecology and Obstetrics.* 2011;113(2011):3–13.
7. Conoscenti G, Meir YJ, Fischer-Tamaro L, et al. Endometrial assessment by transvaginal sonography and histological findings after D & C in women with postmenopausal bleeding. *Ultrasound Obstet Gynecol.* 1995;6(2):108–115.
8. Alcázar JL, Laparte C. Comparative study of transvaginal ultrasonography and hysteroscopy in postmenopausal bleeding. *Gynecol Obstet Invest.* 1996;41(1):47–49.
9. Loffer FD. Hysteroscopy with selective endometrial sampling compared with D&C for abnormal uterine bleeding: the value of a negative hysteroscopic view. *Obstet Gynecol.* 1989;73(1):16–20.
10. Parasnis HB, Parulekar SV. Significance of negative hysteroscopic view in abnormal uterine bleeding. *J Postgrad Med.* 1992;38(2):62–64.
11. Anuradha P, Shashank V, Alka G. Diagnostic hysteroscopy in abnormal uterine bleeding and its histopathological correlation. *J of Obstet Gynecol.* 1999;49:74–76.
12. Loizzi V, Bettocchi S, Vimercati A, et al. Hysteroscopic evaluation of menopausal women with endometrial thickness of 4 mm or more. *J Am Assoc Gynecol Laparosc.* 2018;7(2):191–195.
13. Acharya V, Mehta S, Randan A. Evaluation of DUB by TVS, hysteroscopy and histopathology. *The Journal of Obstetrics and Gynaecology of India.* 2003;53(2):170–177.
14. Baggish MS. Contact hysteroscopy: a new technique to explore the uterine cavity. *Obstet Gynecol.* 1979;54(3):350–354.
15. Sheth SS, Nerulkar NH, Mangeshkar PS. *Journal of Obstet Gynecol India.* 1990;40:451.
16. Barbot J, Parent B, Dubuisson JB. Contact hysteroscopy: Another method of endoscopic examination of the uterine cavity. *Am J of Obst Gyn.* 1980;136(6):721–726.
17. Giusa-Chiferi MG, Gonçalves WJ, Baracat EC, et al. Transvaginal ultrasound, uterine biopsy and hysteroscopy for postmenopausal bleeding. *Int J Gynaecol Obstet.* 1996;55(1):39–44.
18. Deckardt R, Lueken RP, Gallinat A, et al. Comparison of transvaginal ultrasound, hysteroscopy, and dilatation and curettage in the diagnosis of abnormal vaginal bleeding and intrauterine pathology in perimenopausal and postmenopausal women. *J Am Assoc Gynecol Laparosc.* 2002;9(3):277–282.
19. Epstein E, Ramirez A, Skoog L, et al. Dilatation and curettage fails to detect most focal lesions in the uterine cavity in women with postmenopausal bleeding. *Acta Obstet Gynecol Scand.* 2001;80(12):1131–1136.