Case Report

Open Access CrossMark

Synchronous gastrointestinal stromal tumor (GIST) and hepatocellular carcinoma - a case report

Abstract

Background: Gastrointestinal stromal tumors (GIST) are uncommon mesenchymal tumors that arise in the wall of the gastrointestinal tract. The most common site of tumor origin is the stomach, followed by the small intestine. The prevalence of other neoplasms in patients with GISTs is between 14 and 20%, with colorectal and gastric adenocarcinoma being the most common accompanying neoplasms. The purpose of this article is to present a case of synchronous GIST and hepatocellular carcinoma.

Case report: 73 year old male patient who presented with a diagnosis of synchronous gastric GIST and hepatocellular carcinoma.

Conclusions: Patients with high grade GISTs and even patients with low severity histology lesions can develop metastasis, frequently to the liver. This is why it is of utmost importance a correct histological diagnosis of synchronous lesions in order to offer the patient the most adequate treatment.

Keywords: gastrointestinal stromal tumors (GIST), gastric tumor, hepatocellular carcinoma, synchronous tumors

Volume 1 Issue 4 - 2018

Cruz A,[1] Sousa D,[1] Claro M,[1] Gameiro H,[1] Marinho D,[1] Ferreira A,[1] Santos D,[1] Cusati P,[2] Martins J[1]

[1]Department of General Surgery, Local Health Unit of the Alentejo Coast (ULSLA), Portugal
[2]Department of Pathology, Local Health Unit of the Alentejo Coast (ULSLA), Portugal

Correspondence: Ana Cruz, Department of General Surgery, Local Health Unit of the Alentejo Coast (ULSLA), Santiago do Cacém, Portugal, Tel +351 968800414, Email anaisabel.gcruz@gmail.com

Received: June 28, 2018 | **Published:** August 22, 2018

Introduction

Gastrointestinal stromal tumors (GIST) are rare mesenquimal tumors that arise from the wall of the gastrointestinal tract. The most common site of origin is the stomach (60-70% of cases), followed by the small intestine (25-30% of cases).[1] It's distribution is unimodal, affecting predominantly men between 59 and 79 years of age. In over 85% of GIST, c-KIT mutations can be found. It codifies a transmembrane glycoprotein receptor with a tyrosine-kinase component (CD 117) that regulates cell growth and survival.[2] The clinical presentation varies according to tumor size and location and/or the presence of metastatic disease. Therapeutic modalities include surgical resection and selective inhibitors of tyrosine kinase (imatinib).[3] Prognosis of GIST and patient outcome is based on tumor size, mitotic rate and tumor location.[4] Around 50% of GIST metastasize to the liver. Hepatocellular carcinoma typically occurs in cirrhotic livers and it is usually associated to risk factors such as chronic infection due to hepatitis B and C viruses, history of alcohol abuse and other causes of cirrhosis. Around 25% of hepatocellular carcinomas occur in patients without cirrhotic liver, which usually have better prognosis. GIST is reported to occur in association with other secondary neoplasms at rates of 14% to 25%, with colorectal and gastric adenocarcinoma being the most common accompanying neoplasms. The association between GIST and hepatocellular carcinoma is even rarer.[5,6]

Case report

We present a case of a 73 year old male, with previous history of atrial fibrillation, congestive heart failure, type 2 diabetes mellitus, hypertension, obstructive sleep apnea syndrome, chronic obstructive pulmonary disease, chronically medicated with oral anti-diabetics, anti-hypertensives, digoxin and warfarin. The patient was admitted at the Emergency Department following an episode of loss of consciousness. The patient had a history of dark stools during ten days previous to the referred episode and a history of asthenia and weight loss of about 13kg in one year. The lab results revealed a Hemoglobin of 5,6g/dL. The patient was admitted for transfusion and further examinations. The upper endoscopy revealed a sub-mucous lesion of the gastric body (Figure 1). Biopsies showed normal gastric mucosa. Tumor markers were elevated, with a CA 19.9 of 50ng/mL (normal <35) and AFP 7022ng/mL (normal<9). The CT scan revealed heterogeneous hepatomegaly and liver steatosis with gross nodularity mainly on the left lobe, with the biggest node having 80mm in diameter. At the gastric fundus a nodular lesion of 50,9 x 44,5 mm was evident (Figure 2). There were no enlarged lymph nodes. Abdominal MRI confirmed the presence of hepatomegaly with multiple macro nodular lesions between 95 and 104mm in diameter, with important necrotic component, suggestive of metastases. An endoscopic ultrasonography with fine needle aspiration was also performed and revealed a subepithelial gastric lesion suggestive of GIST.

Figure 1 Upper endoscopy showing gastric lesion.

© 2018 Cruz et al. This is an open access article distributed under the terms of the Creative Commons Attribution License, which permits unrestricted use, distribution, and build upon your work non-commercially.

Copyright: ©2018 Cruz et al.

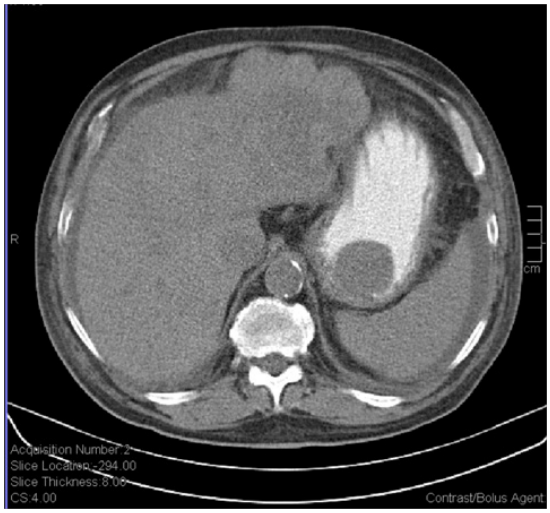

Figure 2 CT scan showing gastric lesion and nodular hepatomegaly.

During patient study, due to frequent episodes of upper digestive haemorrhage with hemodynamic instability, the patient underwent emergent surgery. A laparoscopic atypical gastrectomy and hepatic biopsy of a nodular lesion on segment V were performed. The post-operative period was uneventful and the patient was discharged after 7 days. (Figure3) & (Figure 4) The pathology reported an R0 resection of a neoplasia with fusiform and epitheloid cells, no nuclear pleomorfism, 1 mitosis/50HPF, with Vimentin, CD34 and CD117 positive imunohistochemical markers, Ki67 <1%, negativity for desmin, S100, DOG-1, AE1/AE3 and AML, compatible with a low risk gastrointestinal stromal tumour (NIH classification[8]), in pT2Nx(M0). (Figure5) (Figure 6) & (Figure 7). The pathology report of the hepatic biopsy revealed a primary hepatocellular carcinoma with positivity for Hepar1, CD10 and CK7; Ki 67 of 30% and negativity for AE1/AE3, CK8/18, CDX2, TTF-1, S100 and CK 20. The case was presented in a multidisciplinary meeting and due to unresectable liver disease patient begun systemic therapy with Sorafenib. After 6 months of treatment, due to progression of disease, the treatment was suspended and the patient was referred to paliative care, and was deceased two months later.

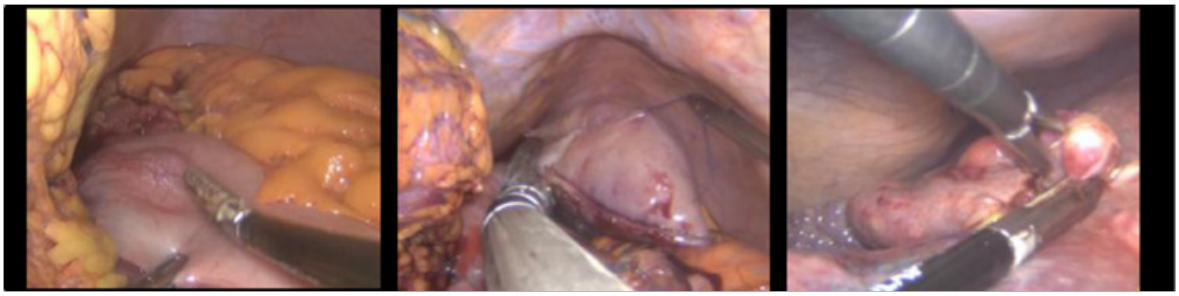

Figure 3 Laparoscopic view: (A) gastric lesion with serosal retraction; (B) atypical gastrectomy; (C) hepatic biopsy of nodule in segment V.

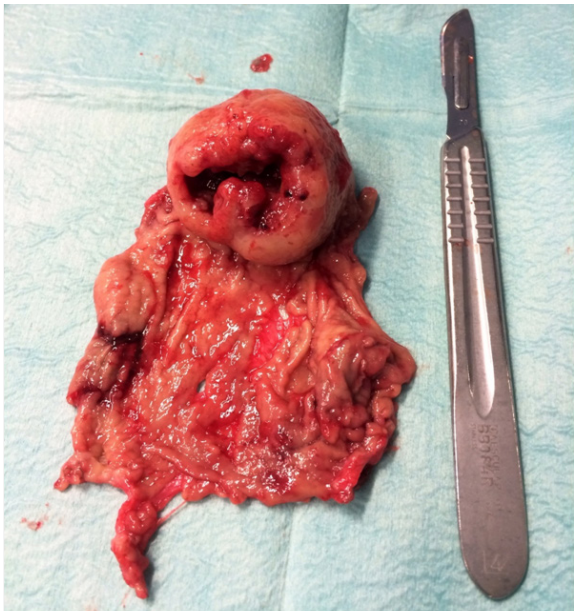

Figure 4 Specimen of atypical gastrectomy.

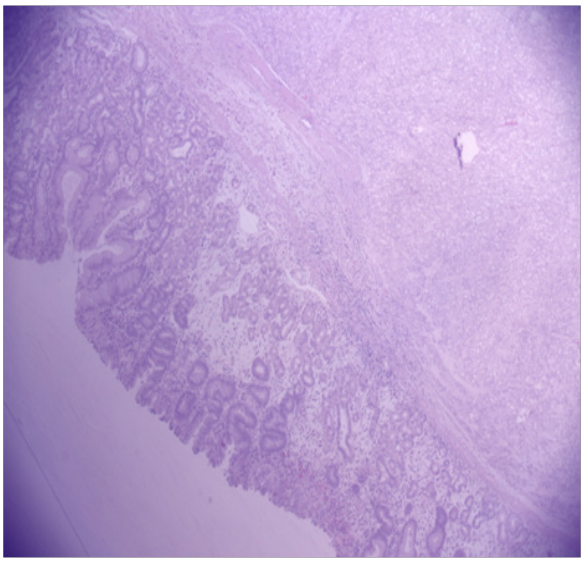

Figure 5 Hematoxylin eosin 5x.

Citation: Cruz A, Sousa D, Claro M, et al. Synchronous gastrointestinal stromal tumor (GIST) and hepatocellular carcinoma - a case report. *MOJ Tumor Res.* 2018;1(4):140–142. DOI: 10.15406/mojtr.2018.01.00032

Copyright: ©2018 Cruz et al.



Figure 6 CD 117 positivity 5x.

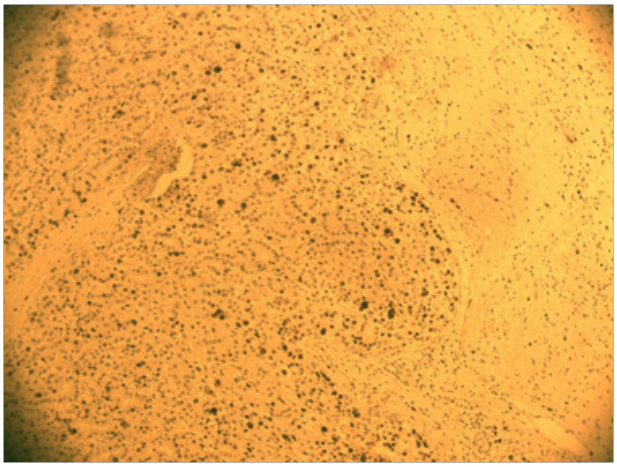

Figure 7 Ki 67< 1% 5x.

Discussion

Patients with high grade GISTs and even patients with low severity histology lesions can develop metastases, frequently to the liver; therefore, it is of utmost importance to obtain a correct histological diagnosis of synchronous lesions in order to offer the patient the most adequate treatment. According do NCCN guidelines, patients with unresectable hepatocellular carcinoma and not a transplant candidate, therapeutic options are: locoregional therapy (ablation, arterially directed therapies and radiation therapy), systemic therapy with Sorafenib or chemotherapy, clinical trial or best supportive care. For selected patients, two randomized phase 3 clinical trials have demonstrated survival benefits with Sorafenib, Llovet J, Ricci S, Mazzaferro V, et al. Sorafenib in advanced hepatocellular carcinoma New Engl J Med 2008;359(4):378-390) and (Cheng A, Kang Y, Chen Z, et al. Efficacy and safety of sorafenib in patients in the Asia Pacific region with advanced hepatocellular carcinoma: a phase III randomized,double-blind, placebo-controlled trial. Lancet Oncol 2009;10:25-34). Prognosis in these patients is usually determined by other malignancy and not significantly influenced by GISTs. Therefore treatment algorithms should be focused on the prognostically relevant malignancy.[7] To our knowledge, synchronous GIST and hepatocellular carcinoma has been reported in only a few case reports.[5,6]

Acknowledgements

None.

Conflict of interest

The author declares there is no conflict of interest.

References

1. Kramer K, Wolf S, Mayer B, et al. Frequence, spectrum and prognostic impact of additional malignancies in patients with gastrointestinal stromal tumors. *Neoplasia (New York, NY)*. 2015;17(1):134–140.
2. Ferreira S, Werutsky G,Toneto M, et al. Synchronous gastrointestinal stromal tumors (GIST) and other primary cancers: case series of a single institution experience. *International Journal of Surgery*. 2010;8(4):314–317.
3. Arnogiannaki N, Martzoukou I, Kountourakis P, et al. Synchronous presentation of GISTs and other primary neoplasms: A single center experience. *In Vivo*. 2010;24(1):109–116.
4. Agaimy A, Wünsch P, Sobin L, et al. Occurrence of other malignancies in patients with gastrointestinal stromal tumors. *Semin Diagn Pathol*. 2006;23(2):120–129.
5. Ferreira e Mora H, Pinto de Sousa J, Devesa V, et al. Gastrointestinal stromal tumor of the stomach and hepatocellular carcinoma: An unusual association. *International Journal of Surgery Case Reports*. 2015;12:75–77.
6. Felekouras E, Athanasios P, Vgenopoulou S, et al, Coexistence of hepatocellular carcinoma (HCC) and c-Kit negative gastrointestinal stromal tumor (GIST): a case report. *South Med J*. 2008;101(9):948–951.
7. Vassos N, Agaimy A, Hohenberger W, et al. Coexistence of gastrointestinal stromal tumours (GIST) and malignant neoplasms of different origin: Prognostic implications. *International Journal of Surgery*. 2014;12(5):371–377.
8. Sousa D, Allen M, Mateus A, et al. EGIST: a Rare Tumor. *J Gastrointest Canc*. 2016;49(2):182–185.

Citation: Cruz A, Sousa D, Claro M, et al. Synchronous gastrointestinal stromal tumor (GIST) and hepatocellular carcinoma - a case report. *MOJ Tumor Res*. 2018;1(4):140–142. DOI: 10.15406/mojtr.2018.01.00032