

# Case report: Infantile non-rhabdomyosarcoma in foot

## Abstract

**Background:** Infantile Non-Rhabdomyosarcoma Soft Tissue Sarcoma (NRSTS) is a very rare entity among all soft tissue sarcomas of pediatric age. So, there is still lacking consensus for treatment protocol, however neoadjuvant chemotherapy modality was ultimately promising in our case.

**Patient history:** 3m.o.NSVD so far healthy girl was diagnosed Malign Mesenchymal Tumor which is a part of NRSTS, after open biopsy, further undergoing successful limb salvage surgery.

**Procedure:** After prospering neo-adjuvant treatment reduced mass was carefully excised within wide excision criterias and with safe surgical borders. Mass enfolded metatarsals then stripped off and fixed back after gama irradiation.

**Conclusion:** Limb salvage surgery is an unquestionable procedure often altering amputation, however saving patient's life is prior to saving his/her limb and functionality.

**Keywords:** pediatric soft tissue sarcoma, non-rhabdomyosarcoma, extracorporeal irradiation, limb salvage

Volume I Issue 3 - 2018

**Cavad Mirzazade, Burçin Keçeci**

Ege University Faculty of Medicine, Orthopaedics and Traumatology, Turkey

**Correspondence:** Cavad Mirzazade, Ege University Faculty of Medicine, Orthopaedics and Traumatology, Turkey, Email dr.cavadmirzazade@yahoo.com

**Received:** May 19, 2018 | **Published:** May 23, 2018

## Introduction

Regardless of localisation on trunk or limb, sarcomas deserve aggressive surgical treatment. Modern treatment methods bring limb salvage procedures forth as an unquestionable option, yet amputation is currently an adequate solution for obtaining wide surgical excision for soft tissue sarcomas of the limb.<sup>1</sup> Neoadjuvant therapies do not conclude dramatically for each patient unfortunately, even though for some cases it could shrink the mass and improve patient's survey.

## Background

3m.o. healthy girl NSVD feels intermittant discomfort over nights, 1 month later parents notice swelling on right foot, consult pediatrician who prescribes symptomatic treatment and with worsening pain refers to an orthopaedist where she was reexamined and consecutive MRI (Figure 1) and biopsies showed mass and diagnosed infantile malign mesenchymal tumor. Treatment plan is considered as non-rhabdomyosarcoma-soft tissue sarcoma (NRSTS) protocol for this age group.

## Differential diagnosis

Soft tissue sarcomas (STS) are mostly present as rhabdomyosarcoma (RMS) for this age group despite infants is rarely diagnosed for sarcomas at all. NRSTS is mainly specified for adolescents and is very rarely seen. Infantile fibrosarcoma, hamangiopericytoma are more oftenly presented entities for infants.<sup>2</sup>

## Diagnosis

Infant requires sedation through diagnostical procedures, such as MRI to reduce artifacts. Needle biopsy (trucut, jamshidi) shouldn't be preferred to avoid failures due to insufficient specimen. Thus, we preferred open biopsy to initiate the prediscussed and assigned treatment in no time.<sup>3,4</sup> Unlike outside hospital trucut results, our diagnosis came out NRSTS.

## Neoadjuvant therapy

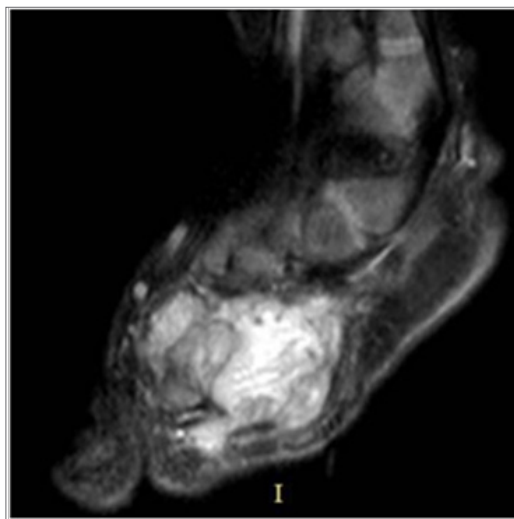
Considering that our case is an infant with tiny limbs, musculoskeletal tumor consensus decided on chemotherapy only since radiotherapy was predicted to seriously harm vascular microstructure and lead to autoamputation. 6 cures were sufficient to acquire significant reduction in mass volume (Figure 2).

## Limb salvage procedure

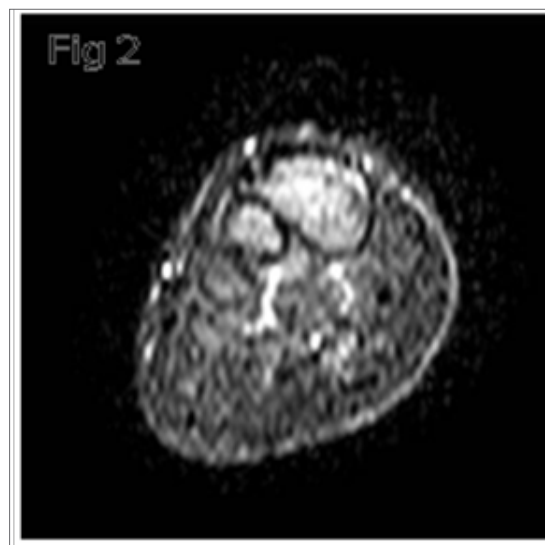
Including 2<sup>nd</sup> 3<sup>rd</sup> metatarsals total mass was excised carefully according to wide excision criterias (Figure 3A). Meanwhile separate table was assigned to prepare metatarsals for extracorporeal irradiation. Tumoral mass was carefully stripped from given metatarsals leaving periosteum on the mass as a natural barrier (Figure 3B) (Figure 3C). Right after bones were triple folded with a steril nylon bag and covered with compressive pad it was then sent to Gama irradiation via 30-40cGy dose. 40minutes later irradiated specimen arrived at the operating room and was unfolded in reverse manner and sank into saline for 15 minutes. Irradiated metatarsals were fixated to original positions with 1.5mm cortical screws (Figure 4). The wound then was sutured with 4.0 vycril (subcutaneously) and 3.0 prolene. Final appearance of the foot seemed pretty anatomical (Figure 5). Short foot splint was applied. 2 weeks later stitches were removed and adjuvant chemotherapy was appointed immediately after. X rays are showing overall good fixation (Figure 6).

## Adjuvant therapy

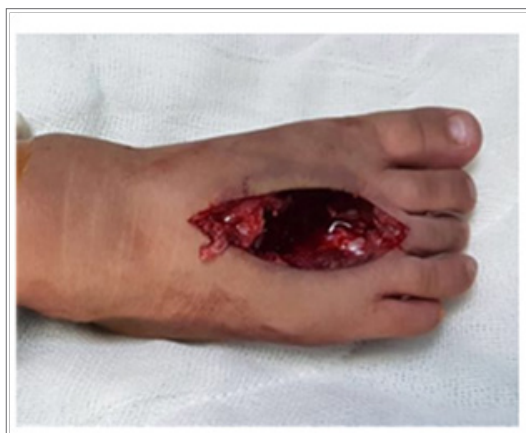Surgical procedure might be insufficient for management of microscopic residuals and micro-metastasis.<sup>5,6</sup> So, each case requires complementary treatment regardless of age. We give a chemotherapy break to the surgery further it keeps going. You may observe MRI sections presenting preserved alignment and slightly the length of metatarsals despite resorption (Figure 7-9) and ultimate appearance of the foot following 1 year of treatment (Figure 10) (Figure 11).<sup>7</sup>



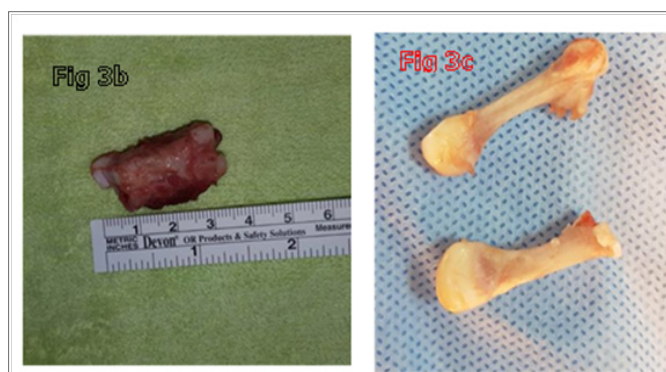
**Figure 1** Sagittal MRI section crossing the diameter of the mass clearly showing its size comparing to foot size. Masses this big could jam metatarsals apart compromising distal neurovascular structures. Contrast MRI, preferably Angio-MRI should be performed.



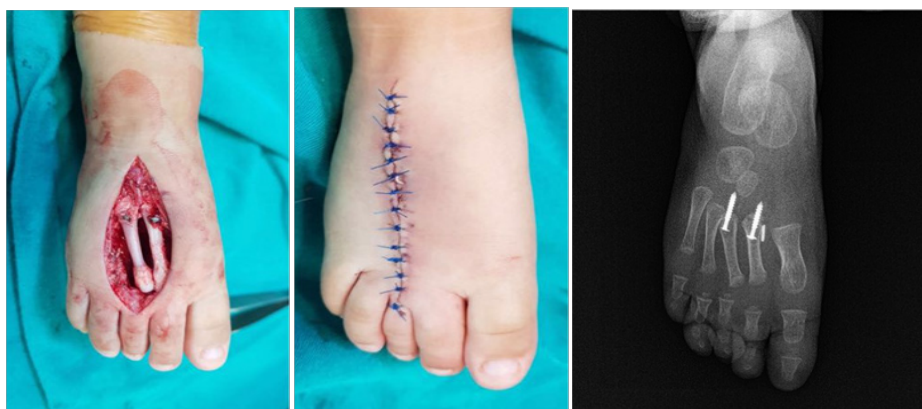**Figure 2** Coronal section of the foot shows significant reduction in mass volume. Contrast uptake decreased due to reduction of vascularity around mass. No jamming and no neurovascular compression left so far.



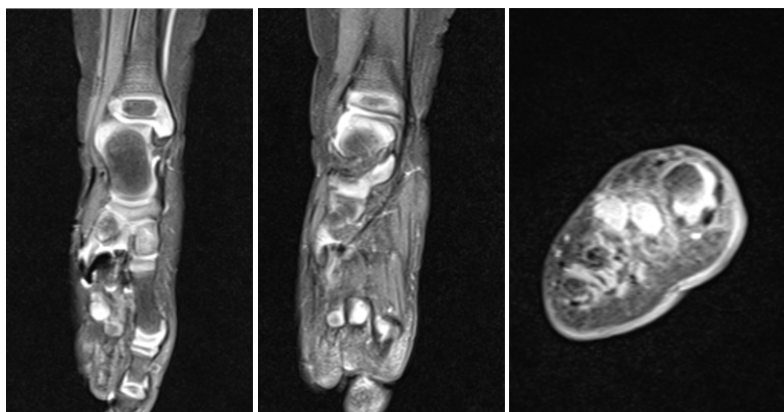
**Figure 3 (A)** Incision was made longitudinally from tarsals to proximal falanges between 2nd, 3rd metatarsals. No plantar intervention was necessary. You may observe the foot after bleeding control with no tourniquet set on. Distal circulation seem normal as seen in the Picture.



**Figure 3 (B & C)** You may observe the totally excised mass and then metatarsals carefully stripped from surrounding soft tissue. Here arises a question whether non-vascularised bones will hold on and articulate as it was before or not.



**Figures 4–6** Irradiated metatarsals were fixated back to anatomical positions via two 1.5mm cortical screws proximally aiming tarsals. Distal fixation wasn't ultimately necessary and there was adequate subcutaneous tissue with sufficient cutaneous closure. Vycril 4.0 for subcutaneous and polypropylen 3.0 cutaneous sutures were used for closure. Metatarsal positioning seems well as you may observe from postoperative X ray.



Figures 7–9 MRI sections are showing still intact articular metatarsal surfaces concerning MTP joint as you may observe at the edge of arrows. Other sections also clearly show some fibrotic skeletal structures still holding alignment on

### Conclusion

STS treatment modalities currently suggest limb salvage procedures for most of cases, except for seldom ones where amputation alters limb salvage, yet our most substantial priority is to save patient, only then extremity and finally functions if possible. Furthermore, limb salvage is a teamwork procedure where every step is essential as the surgery itself.

### Acknowledgement

None.

### Conflict of interest

The author declares there is no conflict of interest.

### References

1. Gurney J, Young JL, Roffers SD, et al. Cancer incidence and survival among children and adolescents: United States SEER Program 1975–1995. *Bethesda (MD): National Cancer Institute; SEER Program*. 1999;99–4649.
2. Loeb DM, Thornton K, Shokek O. Pediatric Soft Tissue Sarcomas. *The Surgical clinics of North America*. 2008;88(3):615–vii.
3. Waxweiler TV, Rusthoven CG, Proper MS, et al. NonRhabdomyosarcoma Soft Tissue Sarcomas in Children: A Surveillance, Epidemiology, and End Results Analysis Validating COG Risk Stratifications. *Int J Radiat Oncol Biol Phys*. 2015;92(2):339–348.
4. Arlachov Y, Ganatra RH. Sedation/anaesthesia in paediatric radiology. *The British Journal of Radiology*. 2012;85(1019):e1018–e1031.
5. Spiro IJ, Rosenberg AE, Springfield D, et al. Combined surgery and radiation therapy for limb preservation in soft tissue sarcoma of the extremity: the Massachusetts General Hospital experience. *Cancer Invest*. 1995;13(1):86–95.
6. Pervaiz N, Colterjohn N, Farrokhhyar F, et al. A systematic meta-analysis of randomized controlled trials of adjuvant chemotherapy for localized resectable soft-tissue sarcoma. *Cancer*. 2008;113(3):573–581.
7. Arlachov Y, Ganatra RH. Sedation/anaesthesia in paediatric radiology. *The British Journal of Radiology*. 2012;85(1019):e1018–e1031.