

An alternative technique using titanium strips for vertical and horizontal bone reconstructions in implant dentistry

Abstract

This paper describes an alternative technique for horizontal and vertical bone reconstructions in cases where the remaining hard tissue is insufficient for the placement of osseointegrated implants. Although numerous surgical techniques have been published for these cases, it is observed that premature membrane exposure is one of the main complications in many of them, often leading to failure of the case. This technique manages to combine the primary objective of a reconstruction technique—maintaining the space occupied by the biomaterial/autogenous bone until its maturation and the formation of new bone—with the advantage of being efficient in preventing premature membrane exposure. Instead of using an extensive titanium mesh, only strips of the same material are used, which are also capable of creating a scaffold for bone remodeling but with a drastic reduction in premature exposure, specifically by allowing greater nutrition of the covering flap positioned passively over the graft.

Keywords: autogenous bone graft, vertical ridge augmentation, titanium mesh, barrier membrane, guided bone regeneration

Volume 14 Issue 2 - 2026

Roberto Machado Cruz,¹ Wilson Martinez Junior²

¹Associate Professor, Department of Dentistry, University of Brasília, Professor of the Postgraduate Program in Implant Dentistry, Brazilian Association of Dentistry, Brazil

²Professor of the Postgraduate Program in Implant Dentistry, Brazilian Association of Dentistry, Brazil

Correspondence: Roberto Machado Cruz, Departamento de Odontologia, Faculdade de Ciências da Saúde, Universidade de Brasília, Campus Asa Norte, Brasília, Brazil

Received: May 29, 2026 | **Published:** June 16, 2026

Abbreviations: GBR, guided bone regeneration

Introduction

Tooth loss is followed by a process of alveolar bone remodeling, which typically compromises rehabilitations with osseointegrated implants due to low bone volume availability in both width and height.¹ Horizontal and vertical augmentation surgeries in guided bone regeneration (GBR) have been considered the best options for obtaining adequate bone support for implant placement. Both surgical techniques are predictable; however, certain precautions must be taken, ranging from incision planning and flap elevation to suturing and preventing premature exposure of the titanium mesh, when utilized.²⁻⁴ In a classic study from 2006, Wang described the four steps to achieve success in these GBR techniques using the acronym PASS (primary closure, angiogenesis, stability, and space creation.⁵ For this reason, while horizontal augmentations have shown high success rates without major complications and with well-established prognoses in the literature, vertical augmentation surgeries, first described in 1998, have shown some trans- and post-surgical complications, notably premature membrane exposures and the consequent increased risk of infection. This fact, in most instances, can lead to lower rates of new bone formation or even total failure of the procedure due to the inability to achieve bone anchorage for the implants.³

This risk of infection can be associated with one of the most significant complications involving the jaws, which is osteomyelitis, caused by the installation of bacterial biofilms in medullary spaces, potentially involving the periosteum, cortical bone, and adjacent soft tissues.¹ In this sense, the importance of considering the safest and most appropriate hard tissue reconstruction technique is reinforced to prevent this colonization of microorganisms (mainly *S. aureus*) in the event of premature exposure of membranes or titanium meshes.

This work presents a variation of the horizontal/vertical augmentation technique aimed at drastically reducing complications resulting from premature exposure of the area to the oral environment.

Through this technique, using the same titanium barriers but in a different way, where fewer contact areas exist between the metal and the graft, allowing advantages such as greater flap nutrition, one of the greatest challenges when using traditional titanium meshes, this technique did not show premature exposure in the described case. The surgical technique requires further investigation for better understanding of their benefits.

Material and methods

This report presents a clinical case utilizing titanium strips to create a scaffold for Guided Bone Regeneration (GBR). The bone defect was located in the anterior maxilla, requiring both horizontal and vertical augmentation—a challenging clinical scenario that demands high surgical proficiency.

Surgical protocol: The anesthetic protocol consisted of regional nerve blocks of the anterior and middle superior alveolar nerves, as well as the nasopalatine and palatine nerves (bilaterally), supplemented by subperiosteal infiltrative anesthesia on the vestibular aspect from teeth 12 to 22. The anesthetic agent used was 4% articaine with 1:100,000 epinephrine. A supracrestal incision was performed with vertical releasing incisions distal to elements 13 and 23 using a #15C scalpel blade, followed by the elevation of a full-thickness mucoperiosteal flap. Bone decortication was then carried out with a multi-blade round bur to stimulate the recipient bone bed and enhance the regional acceleratory phenomenon for repair.

Scaffold construction and stabilization: Following decortication, a titanium mesh (CTi-mem – IM3) was trimmed into strips using Goldman-Fox scissors. These strips, with a thickness of 0.085 mm, are designed to avoid excessive tension, significantly reducing the risk of early exposure. The strip was initially fixed at the apical region near the nasal fossa floor using a 1.5 x 4 mm osteosynthesis screw. Subsequently, a tenting screw with a cover screw was installed to maintain the necessary space for bone growth and further stabilize the titanium strip. A second 1.5 x 4 mm screw was used for palatal

fixation. Achieving absolute stability of the strip is a critical step before proceeding with the grafting.

Biomaterial application and wound closure: The defined area for augmentation was filled with a slow-resorbing bone substitute (Bio-Oss®, Geistlich), which is essential for the long-term success of the scaffold. Overcorrection was performed to compensate for expected volumetric changes during the remodeling process. To protect the graft and prevent connective tissue ingrowth, a resorbable collagen membrane (Bio-Gide®, Geistlich) was placed over the assembly. The mucoperiosteal flap was then repositioned and sutured without tension (tension-free closure) using 4-0 monofilament polyamide sutures.

Outcomes and clinical considerations: The healing period for this technique ranges from 8 to 12 months, depending on the biomaterials used. In this case, the re-entry surgery was performed after 8 months. Clinical observation revealed that the titanium strips effectively guided bone neof ormation without adverse inflammatory responses, owing to the material's high biocompatibility.

Unlike conventional techniques using full-surface titanium meshes or titanium-reinforced ePTFE membranes, this strip technique has shown efficacy in preventing soft tissue exposures, which can compromise tissue formation. The strips were easily removed, revealing a well-vascularized and stable neof ormed bone bed suitable for the placement of osseointegrated implants according to the initial prosthetic planning (Figure 1).

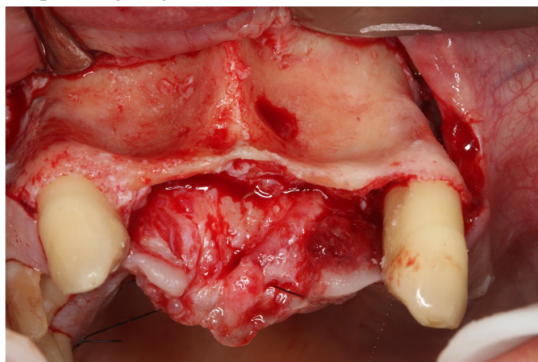


Figure 1 Initial presentation of the bone defect in the anterior maxilla, evidencing the horizontal and vertical volumetric deficiency.

For this case, titanium strips (CTi-mem - IM3) were utilized. These strips, with a thickness of 0.085 mm, do not generate excessive tensile force, which significantly reduces the risk of early exposure. Stabilization of the assembly was achieved using titanium screws (1.5 x 4 mm) and tenting screws, establishing the necessary scaffold to guide bone growth (Figure 2).

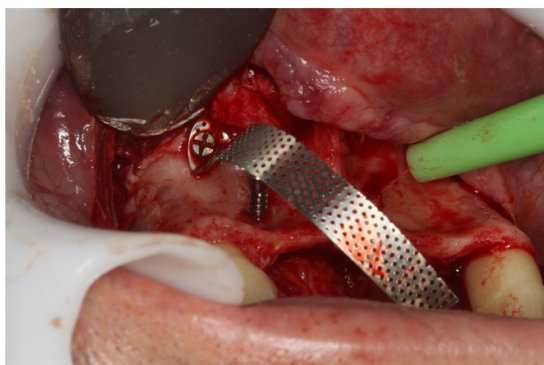


Figure 2 Installation of the first titanium strip and the tenting screw to define the vertical and horizontal limits of the graft.

Two loops were created with the strips to orient bone formation while simultaneously allowing for the maintenance of adequate vascular nutrition in the reconstructed area (Figure 3 & 4).

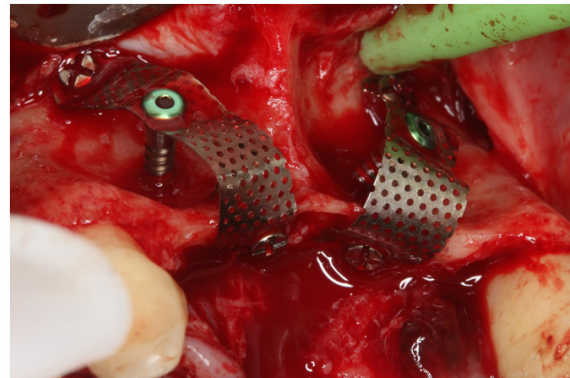
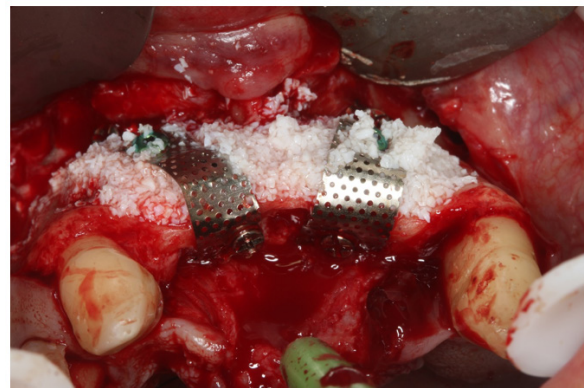

Figure 3 Occlusal view of the two finalized and stabilized titanium loops, creating the scaffold for filling.



The delimited space was filled with biomaterial (Bio-Oss®, Geistlich).

Figure 4 Filling the scaffold with the bone substitute (Bio-Oss), occupying the entire volume delimited by the titanium strips.

As the strip technique does not create a continuous physical barrier, a slow-resorbing collagen membrane (Bio-Gide®, Geistlich) was placed over the assembly. This stage aimed to stabilize the grafted material and protect against connective tissue migration into the graft during the initial weeks of healing (Figure 5).

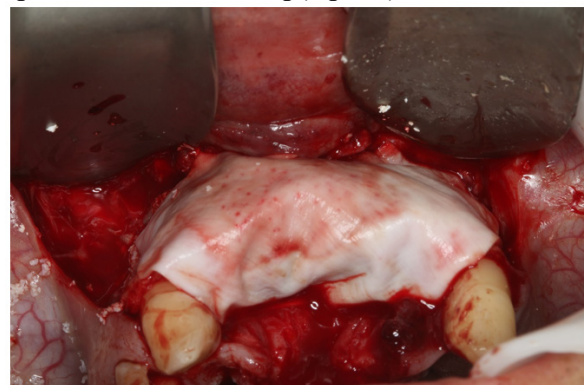

Figure 5 Positioning of the collagen membrane (Bio-Gide) over the graft and strips for stabilization and tissue protection.

Results

The graft maturation period was respected, with an eight-month wait for reintervention. During the second surgical stage, it was

observed that the titanium strips effectively fulfilled their role in guiding bone neoformation (Figure 6).

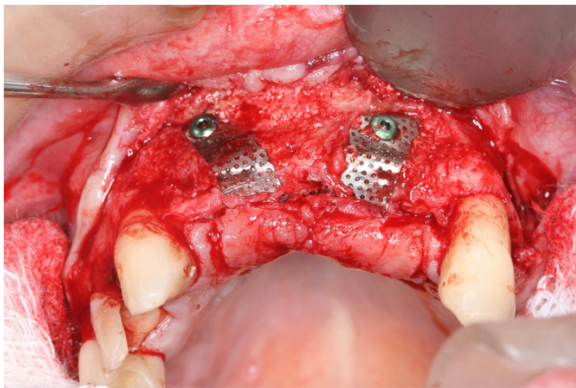


Figure 6 Re-entry after 8 months, demonstrating the maintenance of the grafted volume and the absence of a significant inflammatory response around the strips.

Due to the material's high biocompatibility, no adverse inflammatory responses were observed. The strips were easily removed, revealing a suitable and stable neoformed bone bed for the placement of the planned osseointegrated implants (Figure 7).

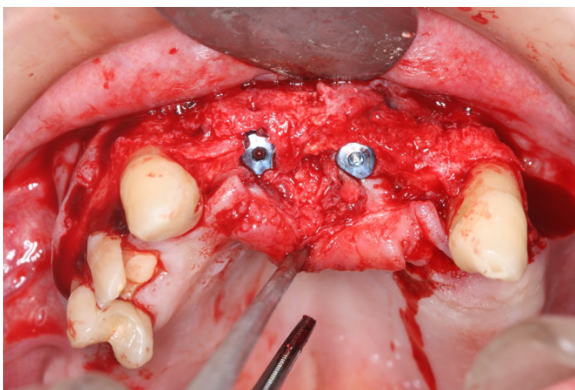


Figure 7 Bone bed after the removal of the titanium strips, showing neoformed and vascularized bone tissue.

Discussion

The use of titanium meshes in horizontal and especially vertical augmentation surgeries has been described in many studies in the literature, primarily evaluating bone gain, success and survival rates of implants, and the percentage of premature exposure.^{2,4,6} In a classic systematic review, it was observed that the average bone gain was 4.3 mm in thickness (horizontal) and 4.1 mm in vertical height.⁷ However, the percentage of exposure was quite prevalent (28%). Nevertheless, the success rate of the installed implants exceeded 95%, which makes the use of titanium meshes still considered a good alternative in these clinical conditions, even with the risk of soft tissue dehiscence and premature exposure.⁷ Some studies highlight the advantage of titanium meshes compared to resorbable membranes due to the lower probability of microbial colonization.⁸

In the present study, one of the greatest advantages of the proposed technique lies in the significant reduction of premature titanium mesh exposures, one of the major complications in vertical augmentation surgeries.^{6,7,9,10} Several authors have also shown concern regarding this complication, advocating, for example, the simultaneous use of resorbable membranes and obtaining good results.¹¹ Other studies

also suggest modifications to titanium meshes, employing customized meshes to decrease the percentage of exposures while reducing surgery time and eliminating the sharp edges of conventional meshes.^{12,13} In the same publication, the authors suggest that certain modifications to conventional meshes can improve the prognosis because, even in cases of exposure, the patient typically did not present clinical symptoms or infections, and the meshes did not need to be removed,¹² as was also observed in the present study, where small exposures may even occur but rarely lead to more serious complications.

As a technique itself, the use of titanium strips does not present anything significantly different from others already described in the literature, neither in the “modus operandi” nor in the biomaterials used. It is possible, as described, to use the same surgical kits used for fixing tenting screws and titanium meshes.^{2,3,6,14} Precisely because of these similarities, the execution of this technique becomes simple and easy for the operator to assimilate, since one of the only differences from traditional techniques is the need to prepare the titanium strips, pre-cut according to the extent of the area and the desired height of the vertical graft. The greater the height desired, the longer the strips; and the larger the extent of the area to be reconstructed, the more strips will be necessary. It is important to mention that, being made of titanium, their biocompatibility and safety of use are not in question. The literature is extensive on this subject, which provides great security in its use.^{4,6,7,12-14}

When evaluating the possible reasons for the decrease in exposures of these grafts, one of the main factors to be highlighted is the maintenance of vascular nutrition of the flap and the diffusion of growth factors, which are fundamental in promoting satisfactory bone regeneration and which, when compromised, become one of the leading causes of failure.^{7,9,15} Undoubtedly, the main idea of this technical modification focused on this challenge: managing to maintain the space for the insertion of biomaterial and/or autogenous bone without losing the primary function of these membranes and/or meshes, which is space maintenance.^{4,6,7,12,13,15,16}

The use of titanium strips enabled this maintenance while simultaneously allowing the preservation of vascularization and the supply of growth factors, especially when associated with the use of additional PRF membranes over the graft area before flap repositioning and suturing.¹⁷ No difference was observed in the quality of the new bone formed when clinically comparing areas protected by titanium strips with areas where only the repositioned flap was present. In both, it was possible to install implants with good insertion torque.

The waiting time for the second stage, where implants were installed, was also not altered and was maintained within the period suggested in the literature, between 6 and 8 months.^{2,3,6} Another very significant point concerns the ease of removing the titanium strips, which was much faster and simpler compared to the reopening of titanium meshes, which often present more difficulty when the meshes become embedded in the newly formed bone, hindering access to screws and the separation of these meshes from the grafted area.

Conclusion

Based on the knowledge of the main techniques described in the literature regarding horizontal and vertical augmentations, and within the limitations of this study, it is possible to conclude that through this technical modification - using titanium strips instead of the traditional titanium meshes described and consolidated in the literature - it was possible to observe a decrease in complications related to premature titanium exposure, common with the use of meshes, while utilizing the same waiting time and without compromising the quality of the

newly formed bone. Future studies should be conducted for a better evaluation of this technique regarding the promising results found in this clinical case.

Acknowledgements

None

Conflicts of interest

The authors declare that there are no conflicts of interest.

References

1. Nary Filho H, Pinto TF, de Freitas CP, et al. Autogenous bone grafts contamination after exposure to the oral cavity. *J Craniofac Surg*. 2014;25(2):412–414.
2. Rocchietta I, Fontana F, Simion M. Clinical outcomes of vertical bone augmentation to enable dental implant placement: a systematic review. *J Clin Periodontol*. 2008;35(suppl 8):203–215.
3. Urban I, Jovanovic S, Lozada J. Vertical ridge augmentation using guided bone regeneration (GBR) in three clinical scenarios prior to implant placement: a retrospective study of 35 patients 12 to 72 months after loading. *Quintessence*. 2009;24(3):502–510.
4. Chen N, Du Y, Guo J, et al. Biologic response to autogenous particulate bone graft and shaped titanium mesh in segmental mandibular defect reconstruction. *Int J Oral Maxillofac Implants*. 2011;26(2):333–340.
5. Wang H, Boyapati L. “PASS” principles for predictable bone regeneration. *Impl Dent*. 2006;15(1):8–17.
6. Esposito M, Grusovin MG, Coulthard P, et al. The efficacy of various bone augmentation procedures for dental implants: a Cochrane systematic review of randomized controlled clinical trials. *Int J Oral Maxillofacial Impl*. 2006;21(5):696–710.
7. Aceves-argemi R, Roca-Millan E, González-Navarro B, et al. Titanium meshes in guided bone regeneration: a systematic review. *Coatings*. 2021;11:316.
8. Schopper CH, Goriwoda W, Moser D. Long-term results after guided bone regeneration with resorbable and microporous titanium membranes. *J Oral Implant*. 2018;44:131–137.
9. Tallarico M, Mattia Ceruso F, Muzzi L, et al. Effect of simultaneous immediate implant placement and guided bone reconstruction with ultra-fine titanium mesh membranes on radiographic and clinical parameters after 18 months of loading. *Materials*. 2019;12(1):1710.
10. Hasegawa H. Comparing the efficacy of a microperforated titanium membrane for guided bone regeneration with an existing mesh retainer in dog mandibles. *Materials*. 2021;14(12):3358.
11. Cucchi A, Vignudelli E, Calamai P, et al. Vertical and horizontal guided bone regeneration (GBR) with resorbable membrane and titanium plate. *Clin Oral Impl Res*. 2019;452.
12. De Santis D, Gelpi F, Verlato G, et al. Digital customized titanium mesh for bone regeneration of vertical, horizontal and combined defects; a case series. *Medicina*. 2021;57(1):60.
13. Songhang Li, Zhao J, Xir Y, et al. Hard tissue stability after guided bone regeneration: a comparison between digital titanium mesh and resorbable membrane. *Int J Oral Science*. 2021;13(1):37.
14. Miyamoto I, Funaki K, Yamauchi K, et al. Alveolar ridge reconstruction with titanium mesh and autogenous particulate bone graft: computed tomography-based evaluations of augmented bone quality and quantity. *Clin Implant Dent and Related Research*. 2012;14(2):304–311.
15. Gutta R, Baker R, Bartolucci AA, et al. Barrier membranes used for ridge augmentation; is there an optimal pore size? *J Oral Maxillofac Surg*. 2009 67(6):1218–1225.
16. Saletta JM, Garcia JJ, Caramês JMM, et al. Quality assessment of systematic reviews on vertical bone regeneration. *Int J Oral Maxillofac Surg*. 2019;48:364–372.
17. Bastami F, Khojasteh A. Use of leukocyte and platelet-rich fibrin for bone regeneration: a systematic review. *Regeneration, Reconstruction & Restoration (Triple R)*. 2016;1(2):47–68.