Research Article

Open Access

Double mesh in special cases of laparoscopic inguinal hernia repair: case series study

Abstract

Recurrence of laparoscopic inguinal hernia repair decreases if the technique is systematized and the recommendations are followed. However, there are special cases in which the usual technique may require modifications to avoid it. The use of two polypropylene meshes has been suggested since the early years of laparoscopic hernia repair with good results. However, for almost two decades, there have been no reports in this regard. The objective of this work, is to describe our technique using double mesh, and report a series of complex cases in which this technique was used to reinforce the inguinal wall with good results comparing it with the techniques described in other series.

Keywords: inguinal hernia, laparoscopy, mesh, double mesh, complex hernia

Volume 11 Issue 3 - 2023

Alejandro Weber-Sánchez,[1] Pablo Weber-Alvarez,[2] Denzil Garteiz Martínez,[3] Adrián Sánchez Leon[4]

[1]Department of surgery. Hospital Angeles Lomas. Huixquilucan Estado de Mexico, Mexico
[2]General Physician. Hospital Angeles Lomas. Huixquilucan Estado de Mexico, Mexico
[3]Department of surgery. Hospital Angeles Lomas. Huixquilucan Estado de Mexico, Mexico
[4]Dipomate of advance laparoscopic course. Hospital Angeles Lomas. Huixquilucan Estado de Mexico, Mexico

Correspondence: Alejandro Weber Sánchez MD, Vialidad de la Barranca s/n Consultorio 410, Valle de las Palmas, Huixquilucan, 52763, Estado de México, México, Tel 52469527, Email awebersanchez@gmail.com

Received: November 12, 2023 | **Published:** December 26, 2023

Introduction

Complications that can occur in patients undergoing laparoscopic inguinal repair are chronic pain and recurrence. The latter, decreases if the technique is systematized and the recommendations are followed.[1,2] However, there are special cases in which the usual technique may require modifications to avoid it. The use of two polypropylene meshes was suggested in some cases since the first years of laparoscopic hernia repair with good results, however, for almost two decades there have been no reports on this matter. The objective of this work is to report a series of complex cases in which double mesh was used to reinforce the inguinal wall.

Materials and methods

All cases were operated using the standard transabdominal preperitoneal technique (TAAP).[3] The criteria for using double mesh was indicated if large size of the hernia defect (> 8cm), indirect, direct or both combined, or widespread weakness of the inguinal wall were found specially in cases of recurrence, except the first case in this series because of the severe weakness of the inguinal wall (Figure 1). The two meshes (Prolene) are 13x15 cm in size and are tailored to adapt the inguinal region.[3] A horizontal slit is made in the first prosthesis halfway along its vertical length. The elements of the spermatic cord are placed through this cut to give support to the mesh, and is fixed with 4 or 5 absorbable staples (Securestrap), two above Cooper's ligament, one medial and one or two lateral to the epigastric vessels (Figure 2). When the epigastric vessels were not completely adhered to the wall, but were detached by the dissection, and could prevent the firm and uniform seating of the mesh, they were sectioned. The second mesh of the same size is placed on top of the previous one, and fixed in the same way with 3 or 4 staples (Figure 3).

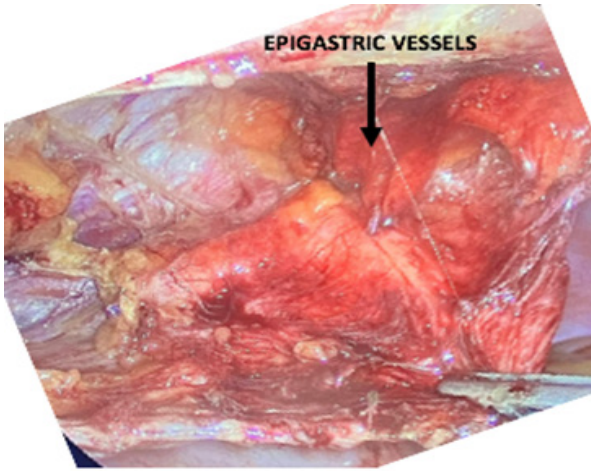

Figure 1 Big hernia defect.

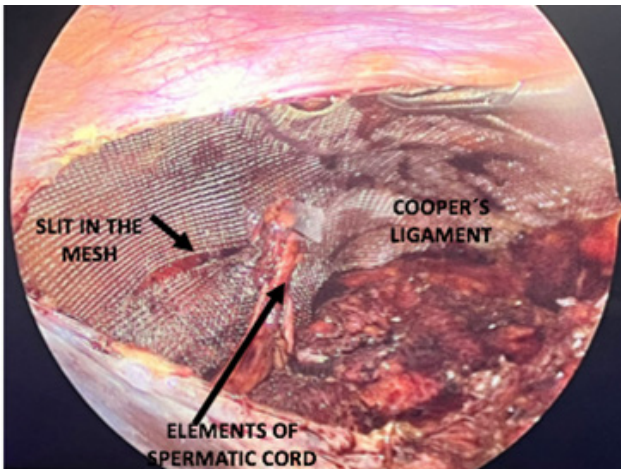

Figure 2 First mesh with a slit.

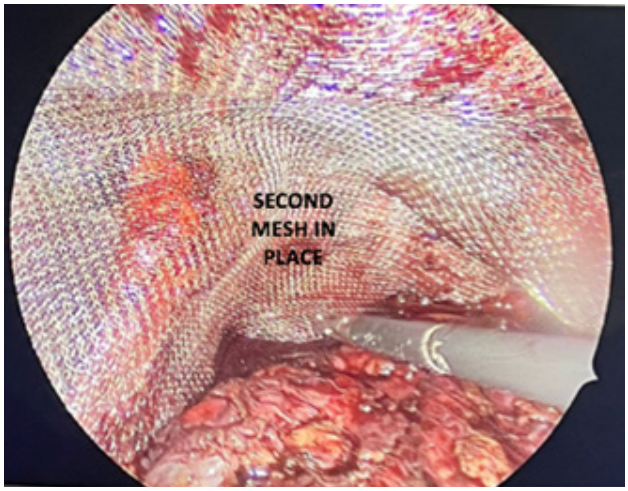

Figure 3 Second mesh in place.

Clinical cases

Case 1

A 54-year-old male with a history of open right inguinal hernia repair. He came with a left inguinal hernia with progressive increase in size and severe pain on exertion. The ultrasound reported bilateral inguinal hernia. The left inguinal hernia was large in size with small intestine incarcerated and right inguinal hernia with omentum content. Due to the size of the defect and the severe weakness of the inguinal wall, a double polypropylene mesh was placed on the left side to reinforce it. The right side was repaired with only one mesh, because the indirect defect was small.

The patient was discharged the same day as surgery. During follow-up, the patient did not report inguinal pain. Follow-up is 12 months without recurrence or postoperative pain.

Case 2

A 46-year-old male with bilateral inguinal hernia repair 3 years previously. He presented with a recurrence of the right inguinal hernia referring severe pain when standing for long periods of time. During surgery, contraction of the mesh from the previous surgery was found with a large hernia defect on both sides of epigastric vessels, and loss of the inguinal wall. Due to the large defect in the wall, it was decided to place double mesh and infiltrate with neurolysis infiltration with 1cm of alcohol to control the chronic pain. Follow-up at 23 months without recurrence or chronic pain.

Case 3

A 73-year-old male with history of open right inguinal hernia repair without mesh 22 years before, and recurrence ten years later, repaired with open technique with mesh. He came due to a recurrence of the right inguinal hernia and was repaired with double mesh, leaving part of the hernial sac due to its large size. At 9-year follow-up he is without recurrence or pain.

Case 4

A 30-year-old male with a history of left orchiectomy due a testicular cancer with placement of a testicular prosthesis. He presented a large and painful left inguinal hernia with inability to perform activities of daily living. Direct, indirect and femoral components were found, with fat content inside that was reduced. Due to the large size of the defect and the absence of the inguinal wall, double polypropylene mesh was placed and infiltration with neurolytic solution was performed due to chronic pain. The chronic pain subsided, and he was able to be discharged the day after the intervention. Currently, he still is undergoing chemotherapy treatment for testicular cancer. At 35-month follow-up he is without recurrence or pain.

Case 5

An 83-year-old male with history of penile prosthesis surgery for erectile dysfunction. He presented with acute right inguinal pain and a bulging mass. Ultrasound and tomography showed herniation of the pelvic reservoir through the right inguinal canal. Laparoscopic TAPP exploration showed a dense fibrous capsule around the reservoir and a widened inguinal orifice through which the tube and bulb protruded plus a weakened inguinal floor. A double mesh was placed, one with a slit around the reservoir tubing and the other to reinforce the rest of the inguinal region. This allowed the reservoir to remain retracted and away from the inguinal canal. No complications were observed, follow-up was uneventful for 14 months and the prosthesis remained functional.

Discussion

Two complications that continue to be feared in the postoperative period of patients undergoing laparoscopic inguinal repair are chronic pain and recurrence. Recurrence decreases if the guidelines are observed and the mini-invasive technique is systematized.[1,2] However, there are cases due to anatomical factors and the particular pathology of each patient that may require modifications to avoid them.

From the first years of laparoscopic hernia repair, some authors such as McKernan, Posta, and others such as Félix and Michas, suggested the use of two polypropylene meshes to cover large defects in the wall of the region in order to avoid recurrences, the latter used double mesh for all their cases after abandoning the plug and patch technique.[4–8]

In the years that followed, other series were published using double mesh with variations of the technique between each one, although the series reported by Jones is not properly a double mesh technique, since it refers to patients with recurrence, in whom he did not remove the mesh from the previous surgery and placed a prosthesis over it.[8]

All series reported good results and none reported recurrences within the follow-up period, all of which were level III evidence (SIGN levels of evidence and grades of recommendation). However, the last of these series was reported almost 20 years ago and since then there have been no new publications on the matter (Table 1).[9]

One reason may be the controversy regarding postoperative chronic pain related to heavy polypropylene meshes (HM), since reports were published suggesting the use of light meshes (LM) to reduce the possibility of chronic postoperative pain.[10,11]

The debate continued since then.[12–15] However, as suggested by the systematic review of hernia repair using HM and LM published by Reinpold, the interpretation of this factor as the origin of postoperative inguinodynia is not clear, due to the variety of prosthetic materials with the diverse characteristics of each one. Although it showed evidence of predictive factors for chronic postoperative pain, particularly severe inguinodynia before surgery or patients with reoperation for recurrent hernia.[16]

Citation: Weber-Sánchez A, Weber-Alvarez P, Martínez DG, et al. Double mesh in special cases of laparoscopic inguinal hernia repair: case series study. *MOJ Surg.* 2023;11(3):166–169. DOI: 10.15406/mojs.2023.11.00247

Table 1 Series reported with use of double mesh

Title of publication	No. cases	Author	Year	Technique	Follow-up	Conclusion
Double-buttress laparoscopic herniorrhaphy	85	Felix EL, et al.[6]	1993	TAAP	6 -18 months	13% seromas, One hernia in the umbilical port, an intestinal obstruction resolved conservatively.
Laparoscopic Inguinal Hernia Repair with Extraperitoneal Double Mesh Technique	42	Posta G[5]	1997	TEP -TAPP	6 – 20 months	Excellent results, without recurrence.
Laparoscopic Inguinal Hernia Repair with Extraperitoneal Double-Mesh Technique	118	Halkic et al.[7]	1999	TEP	22 months	No recurrences. They suggest that the technique provides better safety for the patient.
Laparoscopic Re-Do Repairs of Recurrent Inguinal Hernias Using Double-Mesh Technique	7	Jones M[8]	1998	TAPP	4 years	No chronic pain, no intestinal obstruction.
Endoscopic Extraperitoneal Inguinal Hernia Repair with Double Mesh: Indications, Technique, Complications, and Results	67	Glavan et. al.[9]	2005	TEP	65 months	Excellent results. No recurrences.

Weyhe carried out an experimental study, using 36 rodents divided into 3 groups: control, high-density mesh and low-density mesh. Half of the prostheses were removed after 21 days and the other half after 90 days, examining them using electron microscopy. The specimens from the light mesh group revealed a worse tissue incorporation, with a more marked inflammatory reaction, while the heavy ones showed better biocompatibility with the tissues.[17] Later, Burgmans and collaborators in 2016, extrapolated these results in their TULP-trial work in which included 950 patients, who were followed for two years after the operation. They reported that at one year, the presence of pain was significantly greater in the LM group (2.9%) with a weight of 28g/m2, compared to the HM group (0.7%) with a weight of 95-110g/m2 (p=0.01). Two years later, this difference remained statistically significant. Furthermore, there were four recurrent hernias (0.8%) in the HM group and 13 cases (2.7%) in the LM group (Level of evidence 1+).[18] Currie et al. performed a meta-analysis that included eight randomized clinical trials with a total of 1667 hernias in 1592 patients resolved by TAPP and TEP. They concluded that both light and heavy meshes appear to have similar results in terms of chronic pain and recurrence. (Level of evidence 1+).[19] Li et al. in another meta-analysis, comparing HM and LM, incorporated 16 randomized and 5 comparative studies with 5,389 patients. They found no significant difference in terms of seroma, but reported a lower incidence of chronic postoperative pain [OR = 0.72, 95% CI (0.57, 0.91)] and a higher incidence of recurrences at one year (p = 0.05) [RD = 0.01, 95% CI (0.00, 0.02)], in the LM group, expressing that this complication could arise from its use.[20]

Therefore, there is no conclusive evidence that the use of meshes with a higher polypropylene content causes chronic postoperative pain. From these studies it could be inferred that the use of double mesh, which implies a higher polypropylene content, would not be a causal factor determining chronic pain, as can be seen from the series published on the matter and from the cases in this report. On the other hand, it seems from the comparative reports between LM and HM, that a less firm prosthetic reinforcement such as that of the light prosthesis could be a cause of recurrence in some cases.[21]

To avoid recurrence, the guidelines are consistent in recommending that the dissection of the region must be complete, that all orifices that may be the origin of hernias be examined, and that the size of the mesh need to be sufficient to cover all possible herniation sites.[22] However, there are cases in which the large size of the hernial orifice, the presence of multiple concomitant hernias on the same site, weakened consistency of the wall of the inguinal region or factors that make recurrence likely, may require greater protection than common repairs. Therefore, we consider that in some special cases such as those reported here, the use of double mesh could be advantageous to avoid recurrence.

The general principles of the laparoscopic technique must be meticulously followed to avoid complications. Some advices with the use of double mesh in these cases can help avoid them. If the patient has severe preoperative inguinal pain, infiltration with neurolytic solution once the area has been dissected can help avoid chronic pain.[23,24]

A horizontal slit is made in the first prosthesis and it is placed, leaving the elements of the spermatic cord through this cut so that it is supported. The elements of the cord should not be pressed, nor should the ends of the mesh leaving the slit be crossed or closed over them.[25] Particularly in recurrent hernias when the epigastric vessels can prevent the firm and uniform seating of the mesh, it is advisable to section them. To achieve the goal of greater inguinal floor support, both prostheses must be of sufficient size to cover all possible herniation sites. The technique reported in this series is similar to that published by Felix and Michas, since the two meshes are 13x15 cm in size. But they described that the first mesh was positioned to close the indirect defect stapled, and the second larger mesh was placed over the first piece to close the direct defect. Posta instead, used a larger piece of mesh (12.5x7.5 cm) first, using a large number of staples, and smaller mesh (12.5X5 cm) to cover the first unit. Halkic et al, used a small piece of mesh 4X11cm to cover both inguinal rings, and a 11X15cm to cover the first one. As stated before, Jones did not use a double mesh technique, he refers that in patients with recurrence, he did not remove the mesh from the previous surgery and placed a prosthesis over it.[8] Finally, Galvan et al described the same technique used by Kalkic.

It seems to us, that the benefit of the double mesh technique consists of strengthening the entire area with the two prostheses of the same big size 13X15cm. We fix the first mesh with absorbable staples, and on top of it, and we place the second one, also of the same size to achieve sufficient support with both prostheses. Fixing this second mesh with staples with three or four staples. The advantage of use two meshes could be diminished if one of them is smaller.

The laparoscopic inguinal hernia repair technique with double mesh is aimed to avoid recurrences in special cases, such as

recurrent hernias with weakened inguinal wall which requires greater reinforcement than conventional cases. This technique seemingly is not related to major complications, especially chronic postoperative pain. This series is very small, like those reported years ago, therefore comparative comparative studies are required to support the hypothesis that double mesh technique prevent recurrences in complex cases.

Conclusion

The use of double mesh for the repair of inguinal hernia may be an alternative in some cases in which the inguinal wall is weak and recurrence is likely. The results of this and other reported series using double mesh do not seem to be associated with chronic postoperative pain or other complications.

Acknowledgments

Dr. Alejandro Weber: Conception of the investigation, Main author, Principal reviewer. General supervisor. Main surgeon.

Pablo Weber, Denzil Garteiz and Adrián Sánchez Leon: Investigators and reviewers.

Conflicts of interest

The authors declare that they don't have conflicts of interest.

References

1. Claus C, Furtado M, Malcher F, et al. Ten golden rules for a safe MIS inguinal hernia repair using a new anatomical concept as a guide. *Surg Endosc*. 2020;34(4):1458–1464.
2. Furtado M, Claus CMP, Cavazzola LT, et al. Systemization of laparoscopic inguinal hernia repair (TAPP) based on a new anatomical concept: inverted y and five triangles. *Arq Bras Cir Dig*. 2019;32(1):e1426.
3. García-Ruiz A., Weber-Sánchez A. Laparoscopic transabdominal preperitoneal inguinal hernia repair. In: Jones DB, editor. *Hernia surgery.* Philadelphia, PA: Lippincott Williams & Wilkins. 2013;161–172.
4. McKernan JB, Laws HL. Laparoscopic repair of inguinal hernias using a totally extraperitoneal prosthetic approach. *Surg Endosc.* 1993;7(1):26–28.
5. Posta CG. Laparoscopic inguinal hernia repair with extraperitoneal double mesh technique. *J Laparoendosc Adv Surg Tech A.* 1997;7(1):19–27.
6. Felix EL, Michas C. Double-buttress laparoscopic herniorrhaphy. *J Laparoendosc Surg.* 1993;3(1):1–7.
7. Halkic N, Ksontini R, Corpataux JM, et al. Laparoscopic inguinal hernia repair with extraperitoneal double-mesh technique. *J Laparoendosc Adv Surg Tech A*. 1999;9(6):491–494.
8. Jones MW. Laparoscopic re-do repairs of recurrent inguinal hernias using double-mesh technique. *JSLS.* 1998;2(2):175–176.
9. Glavan E, Mijic A, Bekavac-Beslin M, et.al. Endoscopic extraperitoneal inguinal hernia repair with double mesh: indications, technique, complications, and results. *J Laparoendosc Adv Surg Tech A.* 2005;15(6):586–590.
10. Cobb WS, Peindl RM, Zerey M, et al. Mesh terminology 101. *Hernia.* 2009;13(1):1–6.
11. Poobalan AS, Bruce J, Cairns W et al. A review of chronic pain after inguinal herniorrhaphy. *Clin J Pain.* 2003;19(1):48–54.
12. Agarwal BB, Agarwal KA, Mahajan KC. Prospective double-blind randomized controlled study comparing heavy- and lightweight polypropylene mesh in totally extraperitoneal repair of inguinal hernia: early results. *Surg Endosc.* 2009;23(2):242–247.
13. Agarwal BB, Agarwal KA, Sahu T et.al. Traditional polypropylene and lightweight meshes in totally extraperitoneal inguinal herniorrhaphy. *Int J Surg.* 2010;8(1):44–447.
14. Uzzaman MM, Ratnasingham K, Ashraf N. Meta-analysis of randomized controlled trials comparing lightweight and heavyweight mesh for Lichtenstein inguinal hernia repair. *Hernia*. 2012;16(5):505–518.
15. Bona S, Rosati R, Opocher E et al. Supermesh study group. Pain and quality of life after inguinal hernia surgery: a multicenter randomized controlled trial comparing lightweight vs heavyweight mesh (Supermesh Study). *Updates Surg*. 2018;70(1):77–83.
16. Reinpold W. Risk factors of chronic pain after inguinal hernia repair: a systematic review. *Innov Surg Sci*. 2017;2(2):61–68.
17. Weyhe D, Schmitz I, Belyaev O, et.al. Experimental comparison of monofile light and heavy polypropylene meshes: less weight does not mean less biological response. *World J Surg.* 2006;30(8):1586–1591.
18. Burgmans JP, Voorbrood CE, Simmermacher RK, et.al. Long-term results of a randomized double-blinded prospective trial of a lightweight (ultrapro) versus a heavyweight mesh (Prolene) in laparoscopic total extraperitoneal inguinal hernia repair (TULP-trial). *Ann Surg.* 2016;263(5):862–866.
19. Currie A, Andrew H, Tonsi A, et.al. Lightweight versus heavyweight mesh in laparoscopic inguinal hernia repair: a meta-analysis. *Surg Endosc.* 2012;26(8):2126–2133.
20. Li J, Ji Z, Cheng T. Lightweight versus heavyweight in inguinal hernia repair: a meta-analysis. *Hernia.* 2012;16:529–539.
21. Pisanu A, Podda M, Saba A, et al. Meta-analysis and review of prospective randomized trials comparing laparoscopic and Lichtenstein techniques in recurrent inguinal hernia repair. *Hernia.* 2015;19(3):355–366.
22. Daes J, Felix E. Critical View of the Myopectineal Orifice. Ann Surg. 2017;266:e1–e2.
23. Weber-Sánchez A. Weber-Álvarez P. Treatment of preoperative inguinodynia with neurolytic infiltration during inguinal laparoscopic tapp hernioplasty: preliminary report. *Prac Clin Invest.* 2019;1(1):1–8.
24. Fuller AM, Bharde S, Sikandar S. The mechanisms and management of persistent postsurgical pain. *Front Pain Res (Lausanne)*. 2023;4:1154597.
25. Weber-Sánchez A, García-Barrionuevo A, Vázquez-Frias JA, et al. Laparoscopic management of spermatic cord entrapment after laparoscopic inguinal herniorrhaphy. *Surg Laparosc Endosc Percutan Tech.* 1999;9(4):296–299.