

Tuberous breast in adolescent: a case report

Abstract

The tuberous breast is a rare pathology that affects mainly young women and is characterized by deformities that strike the breasts, such as an enlarged areola, less breast tissue, flaccidity and a close base in the fold of the breast. In the case report, it is a 14-year-old female patient with tuberous breasts and emotional disorders such as aggression, introspection and low self-esteem as a result of the psychological influence of breast changes. After medical exam, a surgical procedure and psychological treatment were indicated, this would improve the appearance of the breasts and should soften the emotional problems of this teenager. The rare quantity of tuberous breast cases, the therapeutic difficulty, as well as the importance of this disease in the physical and emotional development, could prove the importance of this study.

Keywords: breast tuberous, adolescence, breast deformity, asymmetry, women

Volume 4 Issue 5 - 2017

Lucas Leimig Telles Parente,¹ Gabriel Pereira Bernardo,¹ Rodrigo Emmanuel Leimig Telles Parente,¹ Talita Souza Santana,¹ Maria Valéria Leimig Telles,² Maria Thalyne Silva Araújo,³ Bruno da Rocha Alves Lira,¹ Leonardo Nunes Ferreira,¹ Aléxia Bezerra de Mendonça,⁴ Glaura Fernandes Teixeira de Alcântara,⁵ Fernando Gomes Figueredo,⁶ André Luis Sant'ana,⁷ Hermes Melo Teixeira Batista⁷

¹Academy of Medicine at the School of Medicine Estácio de Juazeiro do Norte - FMJ, Brazil

²Medical Residency in Pediatrics - Instituto de Medicina Integral Professor Fernando Figueira, Brazil

³Academic Medicine at the Faculty of Medicine of the Federal University of Cariri, Brazil

⁴Academic of Medicine of the University Potiguar, Brazil

⁵Graduated in Medicine at Estácio Medical School in Juazeiro do Norte, Brazil

⁶Graduated in Biomedicine at the University Center Doutor Leão Sampaio, Brazil

⁷Faculty of Medicine Estacio, Juazeiro do Norte, Brazil

Correspondence: Hermes Melo Teixeira Batista, Faculty of Medicine Estacio, Juazeiro do Norte, Rua Evangelista Sampaio, 1300, Barbalha/Ce, Brazil, Email hermesmelo@oi.com.br

Received: March 24, 2017 | **Published:** July 31, 2017

Introduction

The tuberous breast is a rare condition that affects young women and could be under diagnosed and undergoes the absence of clinical correlation in cases of breast asymmetry.¹ The tuberous sinus was first described by Rees and Aston² and is a rare anomaly of breast shape according to the age of breast development. It presents as characteristics, an enlarged areola, less breast tissue, flaccidity and a narrow base in the fold of the breast.^{2,3} The left breast is usually more tuberous and lower than the right one, with no differences in the areola or nipple.³

Grolleau et al.⁴ described 3 types of tuberous breast:

1. Type I - characterized by hypoplasia of the medial inferior quadrant;
2. Type II - both lower quadrants are hypoplastic;
3. Type III - is characterized by severe constriction, with minimal breast base and apparent deficiency of all quadrants of the breast.^{1,4}

However, this classification is very subjective, but the Northwood index is more objective, which is based exclusively on the hernia ion of the mammary parenchyma through the areola as a fundamental point in the development of the tuberous breast. It is calculated by the relation between the measure of parenchymal protrusion through

the areola (distance from the tip of the papilla to the base of the areola measured in centimeters) and the areolar diameter measured in centimeters. The index greater than 0.4 defines a tuberous breast, which severity could be classified in mild (0.4 to 0.5), moderate (0.51 to 0.6) or severe (0.61 To 0.7).^{1,5} The early manifestation of signs of this mammary pathology could be observed since before puberty, when hormonal factors stimulate the gland and the mammary growth, due to the anterior projection of the areola-nipple complex and the peripheral expansion of the base of the breasts.^{3,6} The breast represents an important symbol of woman's femininity and its deformity result in several psychological problems that, together with the sociocultural influences, motivate surgical interventions to improve its aesthetics.⁷⁻⁹ In this report, it is described the rare case of a 14-year-old woman with tuberous breast and emotional changes as a result from these breast alterations.

Case report

D.C.S., a 14-year-old female patient from Juazeiro do Norte, in State of Ceará, was taken by her mother to the adolescent ambulatory at Maria Amélia Bezerra Children's Hospital. This hospital supports the Estácio de Sá College of Medicine, located in the same city. The teenager's mother reported changes in the appearance of adolescent breasts Figure 1, which occurred two years ago, and behavioral disorders, such as aggression and introspection, attributed

to this fact. Her mother also expressed intense desire to correct the alterations so that she could have a satisfactory anatomical and psychological development. Physical examination: shy expression, uncommunicative, but collaborative patient; hypotrophic mammary parenchyma bilaterally; breasts with enlarged areolas and the right breast was lower, showing asymmetry of both breasts; the right breast was larger than the left; finally, a constrictive ring was present at the base of the breasts (Figure 2). A two-time surgical correction was proposed for this case. At the first moment, the areolar symmetrization was performed by resection of an excess skin ring, followed by detachment of skin covering the breast, and accommodation of the herniated contents within this detached area, aiming to achieve improvement in the breast contour and a decrease in possibility of relapse. At the second time, after the expected parenchymal development, a silicone implant with adequate volume and planar size to be determined according to glandular growth would be placed.

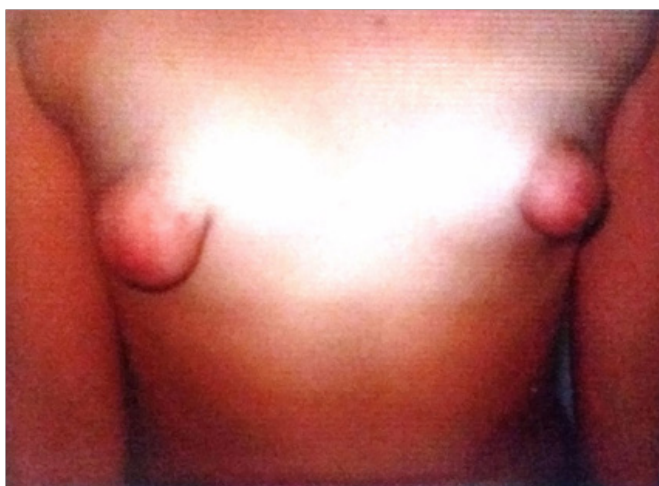


Figure 1 Tuberous breasts of the patient in anteroposterior view.

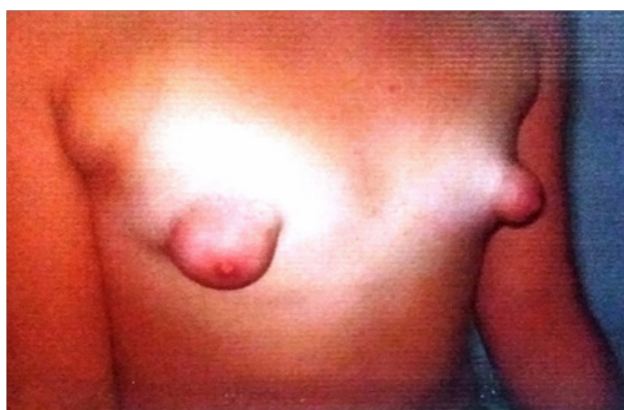


Figure 2 Oblique view of the patient's breasts.

Discussion

The tuberous breast is a deformity found mainly in young women^{10,11} and may be unilateral or bilateral, symmetrical or not and may still cause important psychic suffering. There are many theories about the etiology of this disease, however no one is convincing.^{4,6,12-14}

One of the hypotheses described is that adhesions of the superficial fascia of the dermis and deep planes of the musculature do not let the peripheral expansion of the breast, mainly in lower quadrants. There is also the possibility of a genetic factor, due to the known presence of familial cases, and it is the only risk factor identified until now.¹⁵ Although some studies announce that the prevalence of tuberous breasts among all breast malformations is 10%, the true prevalence is unknown and possibly difficult to verify, considering that most women have mild degrees of deformity and they are not informed of this condition. Usually, they are attended by pediatricians, gynecologists and general practitioners who do not satisfactorily understand that rare pathology.^{11,15-17} Breasts have a large importance in building the body image of women. The treatment of the tuberous breast is a real challenge for the surgeon, who should try to correct the shape of the breast and achieve an ideal volume of symmetry.^{15,18} The choice of surgical technique is based on the desires expressed by the patient and should be indicated according to the morph type of the breast. Surgical treatment is different depending on the degree of breast malformation and volume, and should be chosen from a complete clinical examination, because a poor initial clinical analysis can lead to diagnostic errors and inadequate therapeutic indication.¹⁵ There are a wide variety of techniques described in the literature for the treatment of tuberous breast, which include enlargement with tissue expansion or not, reduction of the nipple-areola complex and many other varieties of glanduloplasty techniques.^{9,19-22} It is very difficult to correct several forms of tuberous breasts with only one technique or intervention and, most of the time, being necessary the use of multiple interventions, always informing the patient the possibility of several procedures to achieve the best possible final result. The several known methods could be associated to treat the more complex forms of tuberous breast, and the deformation analysis will guide each step towards choosing the best technique.¹⁵ The present case reported demonstrates the influence that the tuberous breast has on the emotional state of the patients, due to the aesthetic and cultural importance of the breast to the female sex. Besides being a physical change of difficult surgical correction, it needs a detailed clinical evaluation for the correct therapeutic choice.

Acknowledgements

None.

Conflict of interest

The author declares no conflict of interest.

References

1. Neto MPS, Colombo LRC, Silva DP, et al. Tratamento de mamas tuberosas com incisões combinadas. *Rev Bras Cir Plást.* 2012;27(3):421-427.
2. Rees TD, Aston SJ. The tuberous breast. *Clin Plast Surg.* 1976;3(2):339-347.
3. Dessy LA, Mazzocchi M, Corrias F, et al. Correction of tuberous breast with small volume asymmetry by using a new adjustable implant. *European Review for Medical and Pharmacological Sciences.* 2013;17(7):977-983.
4. Grolleau JL, Lanfrey E, Lavigne B, et al. Breast base anomalies: treatment strategy for tuberous breasts, minor deformities, and asymmetry. *Plast Reconstr Surg.* 1999;104(7):2040-2048.
5. Pacifico M, Kang V. The tuberous breast revisited. *J Plast Reconstr Aesthet Surg.* 2007;60(5):455-464.

6. Heimburg D, Exner K, Krufft S, et al. The tuberous breast deformity: classification and treatment. *Br J Plast Surg*. 1996;49(6):339–345.
7. Jones DP. Cultural views of the female breast. *ABNF Journal*. 2004;5(1):15–21.
8. Thompson JK, Tantleff S. Female and male ratings of upper torso: actual, ideal and stereotypical conceptions. *J Soc Behav Pers*. 1992;7:345–354.
9. Chan W, Mathur B, Slade-Sharman D, et al. Developmental breast asymmetry. *The Breast Journal*. 2011;17(4):391–398.
10. Klinger M, Caviggioli F, Villani F, et al. Gynecomastia and tuberous breast: assessment and surgical approach. *Aesth Plast Surg*. 2009;33(5):786–787.
11. Klinger M, Caviggioli F, Giannasi S, et al. The prevalence of tuberous/constricted breast deformity in population and in breast augmentation and reduction mammoplasty patients. *Aesth Plast Surg*. 2016;40(4):492–496.
12. Heimburg VD. Refined version of the tuberous breast classification. *Plast Reconstr Surg*. 2000;105(6):2269–2270.
13. Serra-Renom JM, Muñoz-Olmo J, Serra-Mestre JM. Treatment of grade 3 tuberous breasts with puckett's technique (modified) and fat grafting to correct the constricting ring. *Aesth Plast Surg*. 2011;35(5):773–781.
14. Meara J, Kolker A, Bartlett G, et al. Tuberous breast deformity: principles and practice. *Ann Plast Surg*. 2000;45(6):607–611.
15. Ellart J, Chaput B, Grolleau JL. Seins tubéreux. *Annales de chirurgie plastique esthétique*. 2006;61:640–651.
16. Barone R, Pavone P, Trifiletti RR, et al. Tuberous breast deformity in an adolescent girl with Hurler-Scheie syndrome. *European Journal of Pediatrics*. 2000;159:936–937.
17. Servaes M, Mahaudens P, Sinna R, et al. Avantages de la voie hémiaaréolaire supérieure pour la correction par implants des seins tubéreux de type II et III. *Ann Chir Plast Esthet*. 2011;56(4):342–350.
18. Ellart J, François C, Calibre C, et al. Breast asymmetry of the teenager and the young adult. Stability of the result in time. About 144 patients. *Ann Chir Plast Esthet*. 2016;61(5):665–679.
19. Hueston J. Surgical correction of breast asymmetry. *Aust NZJ Surg*. 1968;38:112–116.
20. Rees T. Mammary asymmetry. *Clin Plast Surg*. 1975;2:371–374.
21. Grant D. Treatment of asymmetry of the breast. *S Med J*. 1971;64:1097–1105.
22. Saxe B. Reconstruction of unequal or absent breasts. *S Med J*. 1977;51:919–923.