

# Anesthetic approach to giant ovary cyst in the adolescent

## Abstract

Over cysts rarely reach giant sizes. Depending upon the size of the cyst, some difficulties and complications may be encountered in anesthesia induction and management. The aim of the present case report was to draw attention to hemodynamic alterations and respiratory stress which may develop in patients in operations on giant masses in the abdominal area.

**Keywords:** giant over cyst, anesthesia, adolescent

Volume 2 Issue 3 - 2015

Ozkan Onal,<sup>1</sup> Irem Gumus,<sup>1</sup> Tamer Sekmenli,<sup>2</sup> Emine Aslanlar,<sup>2</sup> Jale Bengi Celik<sup>1</sup>

<sup>1</sup>Department of Anesthesiology and Reanimation, Selcuk University, Turkey

<sup>2</sup>Department of Pediatric Surgery, Selcuk University, Turkey

**Correspondence:** Ozkan Onal, Department of Anesthesiology and Reanimation, Selcuk University Faculty of Medicine, Konya, Turkey, Tel +905059052252, Email drozkanonal@selcuk.edu.tr

**Received:** March 30, 2015 | **Published:** May 06, 2015

**Abbreviations:** ECG, electrocardiogram; SpO<sub>2</sub>, oxygen saturation

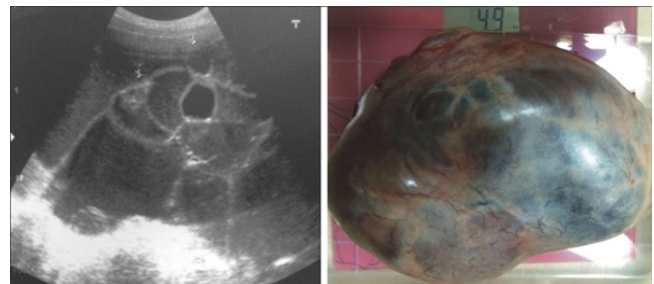
## Introduction

Genital neoplasia developing most commonly in the adolescent and the children are ovary tumors.<sup>1</sup> Majority of ovarian cysts developing in childhood are cystic and usually benign.<sup>2,3</sup> These cysts do not usually have any presenting findings and rarely reach giant sizes. Abdominal mass and pain are most common symptoms.<sup>4</sup> Masses reaching large size may lead to some difficulties in anesthesia management. Difficulty in intubation, and complications associated with cardiovascular and respiratory systems, which may threaten life, may develop. Large ovary masses may exert pressure on large vessels and adjacent organs, leading to pathology and acid formation. After giant tumor is removed, rapid fall in thorax pressure and expansion again may cause lung edema. Aspiration of fluid during excision of giant mass may give rise to severe hypotension or vena cava inferior syndrome.<sup>5,6</sup>

## Case

A 15year old female patient referred to pediatric surgery outpatient clinic with the complaints of abdominal bloating and abdominal pain. Routine tests, abdominal ultrasonography, and CT revealed a cystic mass extending from pelvic area to xiphoid at the size of 20x30cm, thought to be mesenteric and ovarian origin. The patient underwent operation and was monitored with electrocardiogram (ECG), oxygen saturation (SpO<sub>2</sub>), end tidal capnography and non-invasive blood pressure and peripheric vessel cannulation was carried out with 22G catheter. Following adequate preoxygenation, in anesthesia induction, 2mg/kg propofol, 2mcg/kg fentanyl, (Talinat, Vem, Istanbul) 0.6mg/kg rocuronium (Esmeron, Schering-Plough, Istanbul) were administered. Patient was intubated with inner diameter 7.0 no tube and was ventilated at low pressure in case giant mass exert pressure on large vessels. In order to prevent hypotension which may develop following mass excision, 10ml/kg fluid resuscitation was performed. Urine output and blood loss was monitored. A mass at the weight of 4900g mass was removed during operation. (Figure 1) Patient was

hemodynamically stable during operation and was extubated without any problems.



**Figure 1** Images of the giant ovarian cyst.

## Discussion

Respiratory and circulatory management is especially difficult in giant ovary masses. Mass leads to pathology by exerting pressure on large vessels and adjacent organs. It has risks of difficult intubation, aspiration due to mass pressure and risk of massive bleeding. With the expansion in lungs following excision of the mass, pulmonary edema may develop. Due to these risks, preoperative preparation is necessary in order to prevent the negative impact of tumor mass on circulatory and respiratory system.<sup>7,8</sup> Large abdominal tumors may lead to impairment of respiratory functions by leading diaphragm to rise and chest cavity to be narrowed. Following the administration of muscular relaxant, compliance between lung and diaphragm is impaired, making respiratory management even more difficult. High airway pressure may also lead to lung injury.<sup>9</sup> Excision of giant masses may lead to bleeding and hypotension, electrolyte disturbances as well as morbidity and other serious problems. Pressure on vessels and positive pressure ventilation may lead venous return to decrease. In association with the suppression of sympathetic activity by general anesthesia, symptomatic inferior vena cava syndrome and hypoxemia may develop.<sup>10</sup>

Supine hypotensive syndrome has been reported in pregnant women and those with giant abdominal masses related to changing

pressure in inferior vena cava. In all cases, there are various findings helping to explain pathological condition. Namely, peripheral edema, dyspnea, orthopnea, decreased exercise tolerance, abdominal distension, hypotension, oligourea and increased jugular pressure. This syndrome may sometimes be compensated by suitable intravascular volume and hemostatic mechanisms via sympathetic system when these compensation mechanisms are impaired, the symptoms of decreased venous return become more marked.<sup>11-12</sup>

With this compensation mechanism, a balance is produced between blood pressure, cardiac output, and peripheral vasoconstriction. Sympathic blockade by central neuroaxial blocks may lead to severe hypotension. Therefore, spinal and epidural anesthesia should be avoided since they may render this protective mechanism inefficient. However, few cases have been reported in which epidural anesthesia has been employed for cyst decompression without causing circulatory depression and pulmonary edema.

Due to these conditions which may develop, each case should be carefully evaluated by anesthesia department in preoperative period and anesthesia method that will be used should be determined and postoperative intensive care conditions should be prepared according to the condition of the patient. Blood and blood products should be reserved due to probability of bleeding and coagulation disorder. ECG, SpO<sub>2</sub>, BP, urine output, and bleeding should be continuously monitored. If necessary, central catheterization, arterial cannulation, and blood gas monitorization should be carried out. In postoperative period, frequent hemogram and electrolyte evaluations are recommended.

## Conclusion

Giant ovary cyst excision may lead to life threatening problems due to serious respiratory, cardiovascular and circulatory disorders. Therefore, hemodynamic monitorization, ventilator monitorization and fluid balance management should be properly carried out.

## Acknowledgements

None.

## Conflict of interest

The author declares no conflict of interest.

## References

1. Cartault A, Caula-Legriel S, Baunin C, et al. Ovarian masses in adolescent girls. *Endocr Dev*. 2012;22:194–207.
2. Hayes-Jordan A. Surgical management of the incidentally identified ovarian mass. *Semin Pediatr Surg*. 2005;14(2):106–110.
3. Başaklar AC. *Urological disorders of children*. 1st ed. Ankara, Palme, Turkey; 2006. p. 2041–2059.
4. Pomeranz AJ, Sabnis S. Misdiagnoses of ovarian masses in children and adolescents. *Pediatr Emerg Care*. 2004;20(3):172–174.
5. Tagge DU, Baron PL. Giant adrenal cyst: management and review of the literature. *Am Surg*. 1997;63:744–746.
6. Soslow RA. Histologic subtypes of ovarian carcinoma: an overview. *Int J Gynecol Pathol*. 2008;27(2):161–174.
7. Nishiyama T, Hanaoka K. Same day drainage and removal of a giant ovarian cyst. *Can J Anaesth*. 1997;44(10):1087–1090.
8. Kotera A, Kouzuma S, Miyazaki N, et al. Anesthetic management of a patient with an ultra huge ovarian tumor. *Masui*. 2009;58(7):907–909.
9. Shinohara H, Ishii H, Kakuama M, et al. Morbidly obese patient with a huge ovarian tumor who was intubated while awake using airway scope in lateral decubitus position. *Masui*. 2010;59(5):625–628.
10. Aydin AA, Özdemir S, Pakay K, et al. Giant ovarian masses, gynecologic, anesthetic and pathologic assessment; analysis of four cases. *SETB*. 2013;47(1):35–40.
11. Haspels AA, Zuidema PJ. A giant ovarian cyst in a Javanese woman. *Br Med J (Clin Res Ed)*. 1982;284(6326):1410.
12. Morrison P, Morgan G. Removal of a giant ovarian cyst. Anaesthetic and intensive care management. *Anaesthesia*. 1987;42(9):965–974.