Case report

Open Access CrossMark

Combined Ortho-surgical approach based on Ilizarov external fixator during management of a severely injured leg (Gustilo type III B fracture tibia): a case report

Abstract

We present the case of a patient who suffered an open fracture of tibial shaft (Gustilo type III fracture tibia). He was a 68 years old male sustained a trauma over right leg following motor vehicle accident (MVA) and was presented at our hospital within 3 hours of injury. Initially through debridement and surgical toileting were done and bone was stabilized by uniaxial External Fixator (Ex-Fix). On 2nd and 5th post operative day (POD) further debridement was performed. On 12th POD posterior tibial artery (right) perforator based fascio-cutaneous flap was done under epidural anaesthesia and rest of the wound covered by partial thickness skin grafting (PTSG). After 7 weeks of trauma and flap covering surgery the Ilizarov osteosynthetic device was applied. Outcome was excellent according to ASAMI criterion. It may be concluded that Ilizarov osteosynthesis device with soft tissue coverage is a unique and definitive technique in the management of complex tibial fracture.

Volume 13 Issue 5 - 2021

Chowdhury Foyzur Rob,[1] Md. Abdul Gani Ahsan,[2] Dr. Col. Saiful,[3] Md. Gulam Mustofa,[4] Dr Akhlas Bhuiyan,[5] Tanvir Ahmed,[5] Habibur Rahman Chowdhury,[5] Sahel Ahmed Khan[5]

[1]Senior Consultant, Department of Orthopaedics, Al-Haramin Hospital Pvt. Ltd., Sylhet, Bangladesh
[2]Professor & Head, Department of Orthopaedics, Bangabandhu Sheikh Mujib Medical College, Faridpur. Bangladesh
[3]Assistant Professor, Department of Orthopaedics, President Abdul Hamid Medical College, Kisoregonj, Bangladesh
[4]Student of MS in Orthopaedics Course, Sylhet MAG Osmani Medical College, Bangladesh
[5]Senior Medical Officer, Department of Orthopaedics, Al-Haramain Hospital Pvt. Ltd., Bangladesh

Correspondence: Dr. Chowdhury Foyzur Rob, Senior Consultant, Department of Orthopedics, Al-Haramine Hospital, Sylhet, Tel +8801715-250800; Email foyzurrob@gmil.com

Received: October 01, 2021 | **Published:** October 14, 2021

Introduction

Accident with high energy truama is significantly increasing in last few decades. Long bones are mainly affected in such high energy trauma and causes open fracture. Tibial fractures are the most common long bone fractures, with around 25% being open fractures.[1]

The management of open tibial fractures is complex due to the relative lack of soft tissue coverage and blood supply of the tibial shaft.[2] The prognosis depends on the amount of initial bone displacement, comminution and associated soft tissue injury. Advanced bone reconstruction with soft tissue coverage is usually required to achieve bone and soft tissue healing.[3] The rate of complications associated with open tibial fractures is high. Infection, non-union and limb loss are the major causes of morbidity in such open tibial fractures.[4] Therefore the management of these fractures requires a multidisciplinary approach in order to achieve quick healing and early ambulation for the patient.

Several surgical methods can be used in open tibial fractures. Open reduction and internal fixation [ORIF] with plates and screws achieves stability, allows joint mobilization but does not allow early weight bearing.[5] Minimally invasive percutaneous plate osteosynthesis [MIPPO], shows high rate of healing and low rate of soft-tissue complications. Close reduction and intramedullary nailing saves extra osseous blood supply, does not disturb fracture hematoma and maintains soft tissue envelope, allows early weight bearing,[6] but it compromises the intramedullary blood supply and in open fractures increases the risk of infection.[7] Open fracture initially has to be stabilized by external fixators (uniaxial) and wound coverage. These may minimize the risk of infection.

Since the introduction of the Ilizarov method, these fixators have gained the widespread use,[8] and has revolutionized the management of open comminuted diaphyseal tibial fractures which are more susceptible to the infection. It allows early mobilization of the extremity and more union rates. It has other advantages which include wound management and deformity correction and limb lengthening. The tensioned wire circular fixator has proved valuable in the treatment of tibial fractures.[9]

We evaluated the result of a case treated with Ilizarov external fixator for type IIIB open tibial fractures. We analysed the clinical effectiveness and functional recovery of Ilizarov external fixation in this patient.

Case report

A 68 years old male sustained a trauma over right leg following Motor Vehicle Accident (MVA). He was brought to emergency department of a private hospital within 3 hours of injury. Ensuring ABC protocol of accidental injury, the patient was found open fracture Gustilo type III of right leg bone. Immediate pressure bandage with a back slab, wide bore, intravenus (IV) access, blood sampling, the patient was sent to emergency operation theater after informing Ortho Surgeon, Emergency anaestheisa with intensive care unit (ICU) was kept ready. All the procedures were completed within 6 hours of injury.

Under general anaesthesia with two units of whole blood in hand, the wound was opened. Through debridement and surgical toileting were done. On per-operative examination there were hugely

comminuted de-touched periostiual bone fragment with extensive soft tissue loss. Radiologically it was a severely comminuted fracture with one small fragment of bone loss and displacement (Figure 1).

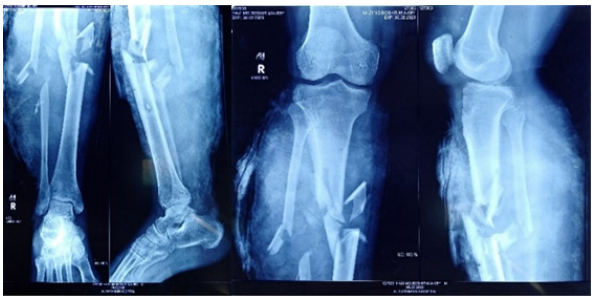

Figure 1 Preoperative radiograph GIII open fracture tibia-fibula.

Bone was stabilized by uniaxial External Fixator (Ex-Fix) (Figure 2). Keeping in mind that 2nd look debridement and flap coverage has to be done later. The distal vascularity was checked after fixation (temporary Ex-Fix). The dorsalis pedis and posterior tibial vessel were intact. Neurological status was almost normal except some sensory loss over the proximal part of dorsum of foot. Postoperative recovery was uneventful and dressing was changed when it was socked. On 2nd post-operative day (POD) the wound was exposed under epidural anasesthesia and the secondary debridement was done keeping the neurovascular tissue with coverage by flash of muscle till partially viable.

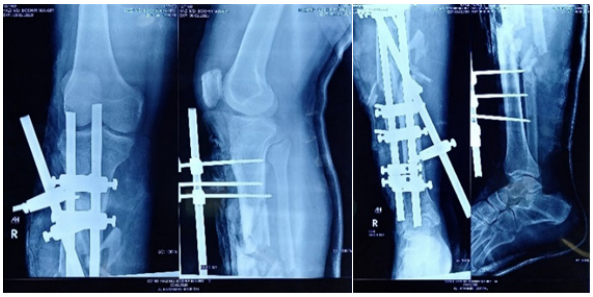

Figure 2 Inital stabilization by uniaxial external fixator.

On 5th POD tissue debridement was done again and definitive planning for flap coverage by a Orthopaedic Flap Surgeon. On 12th POD posterior tibial artery (right) perforator based fascio-cutaneous flap was done under epidural anaesthesia and rest of the wound covered by partial thickness skin grafting (PTSG) (Figure 3).

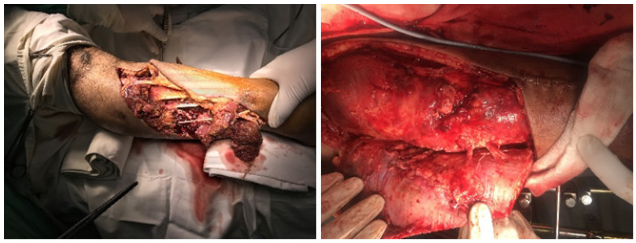

Figure 3 Wound coverage by fascio-cutaneous flap.

After 7 weeks of trauma and flap covering surgery the Ilizarov osteosynthetic device was applied as a definitive management. A four ring Ilizarov was set with one separate olive extractor for loss fragment to turn it to place (Figure 4). The patient walked with full weight bearing on both feet without any support on very 1st post operative day of Ilizarov ring fixation.

Figure 4 Stabilzation of bone by Ilizarov external fixator.

During these procedures and the course of time condition of the patient was uneventful with (1) general physical condition, (2) minimal co-morbidities, (3) 5 units of whole blood transfusion, (4) 21 days of antibiotic therapy with culture and sensitivity (C/S) including tetanus prophylaxis, (5) regular physiotherapy, (6) 10 times dressing change and length of hospital stay was 32 days.

During the evaluation of the outcome the ASAMI criterion was used to evaluate the final results. An excellent result was defined as fracture union with full knee extension and more than 125° flexion, ankle range of motion >75% of normal, limb length discrepancy <2.5 cm, no angulation >7° in any plane, no rotation >7° and absence of infection. According to ASAMI criterion the functional outcome was excellent *(Figure-5)*.

Figure 5 Final follow up.

Discussion

Gustilo Anderson IIIB open lower limb fractures are high-energy injuries that are characterized by extensive and serious injury to soft tissue and serious contamination of the wounds. It is associated with high risk of complication and delayed recovery. Repeated radical debridement of soft tissues and devitalised bony structures become necessary to prevent such complications but results in large skin and bone defects. These defects and associated injuries of other organs complicate treatment regimens, requiring bony stabilisation and reconstruction of soft tissues and bony structures.[1,10]

Macnab and De Haas[11] and Holden,[12] reported that the prevention of infection in open tibial fracture depends on several factors. Severely injured limbs that had extensive soft-tissue injury loss with periosteal stripping, bone exposure and massive contamination increased the risk of infection. We believe that no infection in our case is associated with the adequacy of the debridement, skeletal stabilization by Ilizarov method and the subsequent obliteration of the dead space by a healthy, well-vascularized and conforming muscle flap.

Immediate soft tissue coverage keeping the Ex-Fix in situ is a primary need for the minimizing the complication and early recovery of an open type-III-B fracture tibia. Immediate skin cover

of the exposed fracture site is undoubtedly an advantage, confirming currently published data.[13–15] We used free flap in our cases because free flaps are more reliable and engendered a simple postoperative course of the fracture management. We also use flap covings in early phase of our case. Early covering is advocated by several authors,[1,3,4,12,15] emergency covering combined with bone stabilisation as a single procedure is still rarely performed. Small and Mollan,[15] while using early covering, continue to support the external fixator technique.

Excellent functional outcome has seen in our patient on Ilizarov external fixator during management of a severely injured leg (Gustilo type III B fracture tibia). Foster et al.[16] perform clinical study on 40 cases of complex tibial shaft fractures treated by the Ilizarov method with progressing to satisfactory union. Several others authors also use Ilizarov method in treating segmental tibia fractures and have shown consistently high rates of primary union of at least 90%, with very low rates of complication. The series described by Oztürkmen et al.[17]demonstrated that 91.7% of cases healed without further intervention, Tinlkeridis et al.[18] reported 90.9% and Giotakis et al.[19] 90% progressing to satisfactory union. Wani et al.[20] used the Ilizarov circular external fixator to treat 60 cases of Gustilo II, Gustilo IIIA and Gustilo IIIB open tibial fractures and achieved satisfactory results.

The Ilizarov circular external fixator has been used mostly as a salvage procedure in open tibial fractures for the complications arising from other treatment methods.[21] Recently, it has been used as the primary management in open fractures in many centres throughout the world, especially Russia and Western Europe.[20] The Ilizarov circular external fixator combines the attributes of a solid fixation and early weight bearing with adequate management of the wounds while at the same time addressing the bone loss.

Conclusion

It may be concluded that Ilizarov osteosynthesis device is a unique and definitive procedure in the management of complex tibial fracture. During the course of management the other basic principles should be carried out properly including involvement of other discipline like plastic surgery. Ilizarov method ensures early weight bearing mobilization and safe bone union by improving vascularity.

Acknowledgments

None.

Conflicts of interest

The authors declare no conflicts of interest.

References

1. Court-Brown CM, McBirnie J. The epidemiology of tibial fractures. J Bone Joint Surg Br. 1995;77(3):417–421.
2. Tornetta P, Bergman M, Watnik N, et al. Treatment of grade-IIIb open tibial fractures. A prospective randomized comparison of external fixation and non-reamed locked nailing. *J Bone Joint Surg Br.* 1994;76(1):13–19.
3. Hutchinson AJP, Frampton AE, Bhattacharya R. Operative fixation for complex tibial fractures. Ann R *Coll Surg Engl*. 2012;94:34–38.
4. Gustilo RB, Anderson JT. Prevention of infection in the treatment of one thousand and twenty-five open fractures of long bones: retrospective and prospective analyses. *J Bone Joint Surg Am.* 1976;58:453–458.
5. Mukherjee S, Arambam MS, Waikhom S, et al. Interlocking Nailing Versus Plating in Tibial Shaft Fractures in Adults: A Comparative Study. *J Clin Diagn Res*. 2017;11(4):RC08–RC13.
6. Foote CJ, Guyatt GH, Bhsc KNV, et al. Which Surgical Treatment for Open Tibial Shaft Fractures Results in the Fewest Reoperations? A Network Meta-analysis. *Clin Orthop Relat Res.* 2015;473(7):2179–2192.
7. Bhandari M, Guyatt G, Tornetta P, et al; for Study to Prospectively Evaluate Reamed Intramedullary Nails in Patients with Tibial Fractures Investigators. Randomized trial of reamed and unreamed intramedullary nailing of tibial shaft fractures. *J Bone Joint Surg Am*. 2008;90(12):2567–2578.
8. Bilal D, Sami S, Erdem Ö, et al. New application technique of circular fixator for the treatment of open tibial fractures: circular fixator-hinge technique. *Ulus Travma Acil Cerr Derg. 2013*;19(6):543–547.
9. Vyas T, Shah H, Shah A, et al. Retrospective study of open tibial diaphyseal fractures, type IIIA and IIIB by Ilizarov method. *Int J Orthop* Sci. 2017;3(2):507–512.
10. Chan KM, Leung YK, Cheng JC, et al. The management of type III open tibial fractures. Injury 1984;16(3):157–165.
11. Macnab I, De Haas WG. The role of periosteal blood supply in the healing of fractures of the tibia. Clin Orthop Relat Res 1974;105:27–33.
12. Holden CE. The role of blood supply to soft tissue in the healing of diaphyseal fractures. An experimental study. *J Bone Joint Surg Am*. 1972;54(5):993–1000.
13. Byrd HS, Cierny G 3rd, Tebbetts JB. The management of open tibial fractures with associated soft-tissue loss: external pin fixation with early flap coverage. Plast Reconstr Surg. 1981;68(1):73–82.
14. Byrd HS, Spicer TE, Cierny G 3rd. Management of open tibial fractures. Plast Reconstr Surg 1985;76(5):719–730.
15. Small JO, Mollan RAB. Management of the soft tissues in open tibial fractures. *Br J Plast Surg*. 1992;45(8):571–577.
16. Foster PAL, Barton SB, Jones SCE, et al. The treatment of complex tibial shaft fractures by the Ilizarov method. *J Bone Joint Surg Br.* 2012;94-B:1678–1683.
17. Oztürkmen Y, Karamehmetoğlu M, Karadeniz H, et al. Acute treatment of segmental tibial fractures with the Ilizarov method. *Injury.* 2009;40(3):321–326.
18. Tilkeridis K, Owen AJ, Royston SL, et al. The Ilizarov method for the treatment of segmental tibial fractures. Injury Extra 2009;40:228.
19. Giotakis N, Panchani SK, Narayan B, et al. Segmental fractures of the tibia treated by circular external fixation. *J Bone Joint Surg Br.* 2010;92(5):687–692.
20. Wani N, Baba A, Kangoo K, et al. Role of early ilizarov ring fixator in the definitive management of type II, IIIA and IIIB open tibial shaft fractures. *Int Orthop*. 2011;35:915–923.
21. Lalit M, Manish C, Jashan V, et al. The Ilizarov method in infected non-union of fractures. *Injury.* 2000;31(7):509–517.