Research Article
Open Access
CrossMark

A prospective observational study: The role of ultrasonography in detecting various long bone fractures. An in depth study of a military hospital

Abstract

This study aims at assessing of the ultrasound in various bone fracture. This research aims at establishing safe and effective clinical standards to be adopted in the clinical circumstances. The researcher took two groups of sample where both of them faced bone fractures of long bones but one group underwent ultrasound and the other group of sample underwent the x-ray. Both the set of detections were evaluated in terms of time, specificity and efficiency.

Each of the of 100 participants all confirmed patients of long bones fractures on CT went through X-ray and Ultra sonography where the result is shown in the table below where the results states that US showed 95% sensitivity (sensitivity: positively diagnose a patient who has pathology) for high-grade injuries and US was shown to have 66.6% specificity (specificity: not falsely diagnosing a healthy patient)

Keywords: healthy patient, negative consequences, fracture healing, musculoskeletal ultrasound, pain medicine, rheumatology, podiatry

Volume 11 Issue 6 - 2019

Shehzad Khan,[1] Bakhti Rokhan,[2] Shah Abbas,[3] Asma Shehzad,[4] Sanyya Hadi[4]

[1]Consultant Radiologist, Saidu Teaching Hospital, Pakistan
[2]Associate Professor Radiology, Saidu Teaching hospital, Pakistan
[3]Laparoscopic Surgeon, Senior Registrar Saidu Teaching Hospital, Pakistan
[4]Department of Radiology, Saidu Teaching hospital, Pakistan

Correspondence: Shehzad Khan, Department of Radiology, STH College colony, Saidu Sharif Swat, Dr. Nasreen Clinic, Swat KPK, Pakistan, Tel +923339474003, Email shehzadkan@gmail.com

Received: September 26, 2019 | **Published:** November 08, 2019

Introduction

Background

Machado[1] defines bone as a specialized yet complex group of connective tissues that has a certain level of elasticity even in the large mineralized components concentration in the extra cellular space. A response is generated immediately after a fracture occurs that is based on a molecular signal cascading the bone induction that is called as the fracture healing. The process includes several stages of process of repair based on a spatial and temporal sequence that can further result in complications for instances the delayed unions, non-unions and infections. These complications have further negative consequences involved in treatments for the patients and subsequently the burden of high cost. According to Machado[1] more recent computed tomography besides the traditional x-ray is today proposed for the evaluation such as the ultra sound technique to assess ad monitor the fracture. In addition to that several studies today such as that of Rubin et al.[2] Schortinghuis et al.[3] Parvizi & Vegari[4] Tajali et al.[5] have expressed that the low-intensity pulsed ultrasound (LIPUS)devices has the ability to improve the repair the bones of the patients that has shin bone fractures. The studies have shown gradual healing since the injury by using the device that emits the low-intensity pulsed ultrasound. The study conducted by Schofer et al.[6] states that LIPUS enhances the healing process in the fresh fractures and has also concluded that the LIPUS assist in promoting the healing in older fractures with delayed fracture healing.

According to Papalada et al.[7] the overuse injuries in particular the bone stress injuries are in majority misdiagnosed. The study further states that using MRI (magnetic resonance imagining) is effective but it is costly whereas the ultrasound is a tool that is less costly and noninvasive for stress fracture preliminary diagnosis. The study was based on a ten year experiment where 1313 patients were assessed including the track and field athletes facing bone stress injuries. The study compared the MRI with ultrasound and concluded that ultrasound is more sensitive for the bone stress injuries diagnosis as compared to the MRI and therefore recommended the use of ultrasound in the assessment of the bone injuries. Moreover the study suggested that the therapist along with the athletic trainers can easily perform ultrasound in case the stress fracture is clinically suspected that will assist in early identification of the bone fracture.

According to Blankstein[8] ultrasonography when managed by an expert is a versatile diagnostic tool that has been used to evaluate breasts, fetuses, neonatal brains, hearts, glands, blood vessels and abdomen and pelvis organs. The field of Musculoskeletal Ultrasound with soft tissues and joints of the musculoskeletal system are recently under study due to the growing concern in the field of the sports medicine, anaesthesiology, physiatrists, rheumatology, podiatry, and pain medicine.

According to few studies ultrasound are concluded a tool that cannot evaluate the soft tissue of the bone as the waves of the ultrasound cannot pass though bones at the frequency range that is required in the imaging diagnosis. The bone tissue interface inherits a high acoustic impedance causes the waves of ultrasound to be powerfully reflected from the surface bones. Therefore these studies conclude that due to the lack of the signals potential to penetrate deal to the bone soft tissue it can only see darkness beyond the cortical surface that is called as the acoustic shadowing. These acoustic shadows do to give any information's.

However studies such as that of Sinha et al.[9] stated that radiography has been the most commonly use imaging modality in order to detect the bone fracture especially in the trauma patients that are brought in

the emergency department. The study defines that the biggest issue at that time is the wait as the radiograph takes several hours in high patient flow in facilities. Sinha et al.[9] clearly states that

"Non-life-threatening skeletal injuries are often kept waiting for hours for treatment because radiographic examination is delayed. Bedside ultrasound has the potential to be a quick, noninvasive alternative for identifying bone fractures in the ED setting"

Furthermore Sinha et al.[9] concluded that the ultrasound is the legitimate tool for fracture diagnosis and it can be used as the alternate to the radio graphs in particular circumstances. The study concluded benefits such as the shorter wait time for the identification of fractures in facilities that are overcrowded and the patient does not have to go under radiation.

From the discussion above the radiography has been concluded to be the standard tool for diagnosing the fractures. However there is a possibility that ultrasound are much faster a cost effective especially in emergency departments (Figure 1 & 2). The above discussion also shows the numerous amounts of studies conducted in defining the ultrasound feasibility in fracture diagnosis such as in the study by Moritz et al.[10] which fails to compare the specificity and sensitivity with the radiological imaging. The highly specialized examiners were the only one to clinically use of these methods. However this study aims at comparing the x- ray imaging modality with that of the ultrasound in various bone fracture. This research aims at establishing safe and effective clinical standards to be adopted in the clinical circumstances.

The discussion above states that ultrasound has two main aspects one as the diagnosis and other as a therapy. This research aims at providing the field's overview where the chapters will give out information about the phenomenon and connection between the ultrasound waves and bones. Thus the objectives of the study can be discussed as below.

Figure 1 A 35yr soldier who had a blast injury, showing multiple metallic foreign bodies in soft tissues. The arrow head pointing towards a doubtful area of cortical disruption in proximal metadiaphysis.

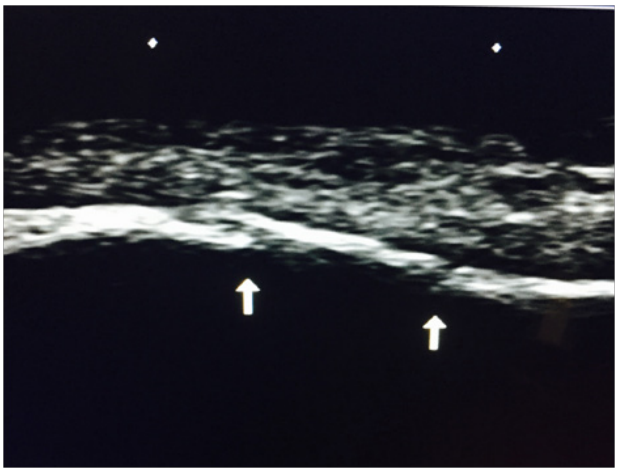

Figure 2 The same patient was gone through a detailed ultrasound showing multiple fractures with overlying small hematomas.

Objectives

a. To compare the ultrasound imaging modality with x-rays while diagnosing fractures of long bones.

b. To identify the role of ultrasound in diagnosing fractured bones.

c. Compare and contrast ultrasound imaging modality with x-rays cost and specificity.

d. To establish safe and effective clinical standards to be adopted in the clinical circumstances

The above discussion has lead in creation of hypothesis that is

H1: the ultrasound diagnosed fracture is cost effective

H2: the ultrasound diagnosed fracture reduces wait time of radiograph which takes several hours in high patient flow in facilities

Research methods

The aim of this section is to explain the method to conduct the research in detail. The researcher took two groups of sample where both of them faced bone fractures of long bones but one group underwent ultrasound and the other group of sample underwent the x-ray. Both the set of detections were evaluated in terms of time, specificity and efficiency.

Study design

The study is conducted in the emergency department of the Combine Military Hospital Peshawar in two months period from May 2016 to June 2016. The investigators in this study composed of five physicians of emergency and one belonging to surgery resident. The emergency physicians had performed the FAST examination during their practice but none of the investigator was ultra-sonographer. The standardized formal training was taken by the investigators in the femoral and humeral fracture detections that used toshiba aplio portable ultrasound device (toshiba aplio) that had a head of 5 MHz transducer. The training were given through a twenty minute presentation showing the techniques for scanning particular to the detection of fracture that was followed by practice of forty minutes session on a normal live model.

Settings

The study is conducted on the patients that have been taken from the database of the CMH Peshawar from the month May 2016 to June 2016. Within this time period 100 patients were confirmed to have bone fractures through the evaluation of CT. These set of 100 patients had fracture identified which are selected to undergo the x-ray and ultrasound tests. The ultrasound will include sac technique of the femur or humerus in the process. The transducer was used and placed on lateral thigh for the examination of femur that had a probe transverse to the thigh's longitudinal axis that revealed femoral cortex clear cross sectional view for the urgent and quick orientation. In addition to that to obtain a normally smooth femoral shaft view the transducer was placed rotated to a longitudinal position. In addition to that the transducer was slightly angled to get the femoral neck and scan was taken till the midpoint of the inguinal ligament that gave the view of femoral neck, pelvic acetabulum and head. After the specification of the eligibility the patients were checked through level of fracture from high, medium or low through the CT scan.

Participants

The study population is based on the convenience sample that provided informed consent and met the inclusion criteria. The inclusion criteria is based on the fact that the patients are all above 18 and older and are able to understand the consent for this research and have a confirmed Computerized Tomography along with X-Ray evaluation. The patients that were evaluated through the x-rays that were eligible consisted of the emergency patients that even ordered for trauma of humerus, hip, shoulder or femur.

Variables

In order to compare these evaluations with ultrasound and x-ray the high level suspicion was observed as a positive examination and a medium/ low clinical suspicion is observed as the negative examination. However the examination is considered positive if in cortical bone there is a clear disruption is seen that is presented as a step off in the cortical line. The results are recorded from the clinical examination and the subsequent ultrasound evaluation with no information about the radiography result of the patient. The CT was first performed where in all of the observation the diagnosis by radiologist was made. It is predicted that x-ray and ultrasound will miss out some of the fracture identification during the process which will be further studied and compared.

The data set once undergo the x-ray and ultrasound will be evaluated on the base of time consumption, specificity and sensitivity of both the tools along with the cost it takes to use ultrasound or x-ray for the fracture identification

Data sources

The observation and patients with identified fractures are taken from the database of the CMH Peshawar.

Biasness

In order to ensure that there is no biasness in the study the data result is assessed on the guide-lines of 14-Item Quality Assessment of Diagnostic Accuracy Studies (QUADAS2) tool.[11] The assessment was performed that consisted of the (i) acceptable reference tests (ii) accounting for indeterminate results (iii) avoiding differential verification biasness (iv) disease progression biasness (v) incorporation biasness and verification bias (vi) blind index test interpretation (vii) blind interpretation of reference test (ix) explained withdrawal (x) relevant clinical data available, and (xi) representative spectrum.

Study size

Twelve famous studies based on ultrasound role has included a small sample size in their study such as Hendrich et al.[12]; Engin et al.[13]; Rainer et al.[14]; Jin et al.[15]; Traub et al.[16]; Wootton-Gorges et al.[17]; Weinberg et al.[18]; You et al.[19]; Szucs-Farkas et al.[20]; Yazkan et al.[21]; Błasińska et al.[22] and Chardoli et al.[23] had a small sample size where the study was also retrospective based on a convenience sample. Therefore this research is based on a small size with only 100 observations.

Quantitative variables

MSExcel was used to quantify the data where the data was differentiated on the basis of the type of the fracture such as rib fractures, clavicle fractures, radial fractures, ulna fractures, femur fractures, fibulae fracture, humerus and tibia fracture.

Results

This chapter discusses the results of the research and explains and the statistics of the observation.

Participants

The number of participants is 100 that are all confirmed patients of long bones fractures on CT. Each of the participants undergoes the x-ray and the ultrasound evaluation.

Main results

Each of the of 100 participants all confirmed patients of long bones fractures on CT went through X-ray and Ultra sonography where the result is shown in the table below where the results states that US showed 95% sensitivity (sensitivity: positively diagnose a patient who has pathology) for high-grade injuries and US was shown to have 66.6% specificity (specificity: not falsely diagnosing a healthy patient) (Table 1).

Table 1 Main result

X-Ray result	Ultrasound result
The number of patients confirmed for long bones fractures by x-ray were 86 out of 100	The number of patients confirmed of long bones fractures by ultrasound was 90
X-ray missed 14 patients where a. 10 had small hair fractures b. b. 4 had occult stress fractures	Ultrasound missed 10 patients which consisted of those patients who had fractures epiphyseal end of bone
Time taken to get result of X-ray was 15 to 20 minutes	Time taken to get result of ultrasound was 10 minutes

Discussion

Key results

The main objective of this study was:

1. To identify the role of ultrasound in diagnosing fractured bones
2. Compare and contrast ultrasound imaging modality with x-rays cost and specificity
3. To establish safe and effective clinical standards to be adopted in the clinical circumstances

The above objectives have been successfully achieved by this study. The first objective that is the ultrasound imaging modality with x-rays while diagnosing fractured bones is compared where the results shows that ultrasound (US) showed 95% sensitivity (sensitivity: positively diagnose a patient who has pathology) for high-grade injuries and US was shown to have 66.6% specificity (specificity: not falsely diagnosing a healthy patient). The second objective to identify the role of ultrasound in diagnosing fractured bones is highlighted as the study shows that ultrasound is not only better in sensitivity and specificity but it takes lesser time in producing result as compared to that of the x-rays. The improvement of hand-held ultrasound frameworks may therefore empower a method for all the more rapidly recognizing clinically huge cracks, through faster picture acquisition and concurrent understanding at the bedside. Further-more, the little size of these frameworks empowers their utilization in locations where conventional radiography and experienced physicians are not accessible. To be consolidated into the initial assessment of the injury quiet, the picture created by these frameworks must be interpretable by the insignificantly trained operator, and the precision of the translation must be com-story to the finishes of the underlying physical examinations performed by a clinician. The third objective of comparing ultrasound imaging modality with x-rays cost and specificity is also achieved where US cost is relatively low and specificity is 66.6%.

The fourth objective is achieved by explaining the safe and effective clinical standards to be adopted in the clinical circumstances such as the standardized formal training was taken by the investigators in the femoral and humeral fracture detections that used toshiba aplio 180 portable ultrasound device (toshiba aplio) that had a head of 5 MHz transducer. The training were given through a twenty minute presentation showing the techniques for scanning particular to the detection of fracture that was followed by practice of forty minutes session on a normal live model.

Limitation

The study has shown that ultrasound has a limited detection of fractures especially near the articular surface due to irregular surface and complex anatomy of joints. Moreover this study is limited to only long bone detection of fracture and doesn't include the small bones and joints. In addition to that the sample only consisted of male participants and there were no female involved. The study don't tell us about the details of fractures.

Interpretation

This study aims at comparing the x- ray imaging modality with that of the ultrasound in various long bone fracture. This research aims at establishing safe and effective clinical standards to be adopted in the clinical circumstances. This research aims at providing the field's overview where the chapters will give out information about the phenomenon and connection between the ultrasound waves and bones. The results of this study is similar to that of the Blankstein[8] who stated that ultrasonography when managed by an expert is a versatile diagnostic tool that has been used to evaluate breasts, fetuses, neonatal brains, hearts, glands, blood vessels and abdomen and pelvis organs. The field of Musculoskeletal Ultrasound with soft tissues and joints of the musculoskeletal system are recently under study due to the growing concern in the field of the sports medicine, anesthesiology, physiatrists, rheumatology, podiatry, and pain medicine.

The study concludes that plain radiograph is a good investigation in diagnosing and assessing large fracture in joints, long and small bones but when it comes to detecting occult and stress of long bones in a Military tertiary care hospital, Ultrasound is also a good modality in diagnosing fractures and can also detect small hematomas overlying the fractures, which otherwise is difficult to observe in radiographs. Ultrasound is recommended in such trauma setups due to its sensitivity, swiftness, cost effectiveness and no radiations.

Acknowledgments

None.

Conflicts of interest

The authors declare there is no conflict of interest.

References

1. Machado CB. *Ultrasound in bone fractures: from assessment to therapy*. USA: Nova Science Publishers; 2013:279.
2. Rubin C, Bolander M, Ryaby JP, et al. The use of low-intensity ultrasound to accelerate the healing of fractures. *J Bone Joint Surg Am*. 2001;83(2):259–259.
3. Schortinghuis J, Stegenga B, Raghoebar GM, et al. Ultrasound stimulation of maxillofacial bone healing. *Crit Rev Oral Biol Med*. 2013;14(1):63–74.
4. Parvizi J, Vegari D. Pulsed low-intensity ultrasound for fracture healing. *Foot Ankle Clin*. 2005;10(4):595–608.
5. Tajali SB, Houghton P, MacDermid JC, et al. Effects of low-intensity pulsed ultrasound therapy on fracture healing: a systematic review and meta-analysis. *Am J Phys Med Rehabil*. 2012;91(4):349–367.
6. Schofer MD, Block JE, Aigner J, et al. Improved healing response in delayed unions of the tibia with low-intensity pulsed ultrasound: results of a randomized sham-controlled trial. *BMC Musculoskeletal disord*. 2010;11(1):229.
7. Papalada A, Malliaropoulos N, Tsitas K, et al. Ultrasound as a primary evaluation tool of bone stress injuries in elite track and field athletes. *Am J Sports Med*. 2012;40(4):915–919.
8. Blankstein A. Ultrasound in the diagnosis of clinical orthopedics: The orthopedic stethoscope. *World J Orthop*. 2011;2(2):13–24.
9. Sinha TP, Bhoi S, Kumar S, et al. Diagnostic accuracy of bedside emergency ultrasound screening for fractures in pediatric trauma patients. *J Emerg Trauma Shock*. 2011;4(4):443–445.
10. Moritz JD, Berthold LD, Soenksen SF, et al. Ultrasound in diagnosis of fractures in children: unnecessary harassment or useful addition to X-ray? *Ultraschall Med*. 2008;29(3):267–274.
11. Whiting PF, Rutjes AW, Westwood ME, et al. QUADAS-2: a revised tool for the quality assessment of diagnostic accuracy studies. *Ann Intern Med*. 2011;155(8):529–536.

12. Hendrich C, Finkewitz U, Berner W. Diagnostic value of ultrasonography and conventional radiography for the assessment of sternal fractures. *Injury*. 1995;26(9):601–604.

13. Engin G, Yekeler E, Güloğlu R, et al. US versus conventional radiography in the diagnosis of sternal fractures. *Acta Radiol*. 2000;41(3):296–299.

14. Rainer TH, Griffith JF, Lam E, et al. Comparison of thoracic ultrasound, clinical acumen, and radiography in patients with minor chest injury. *J Trauma*. 2004;56(6):1211–1213.

15. Jin W, Yang DM, Kim HC, et al. Diagnostic values of sonography for assessment of sternal fractures compared with conventional radiography and bone scans. *J Ultrasound Med*. 2006;25(10):1263–1268.

16. Traub M, Stevenson M, McEvoy S, et al. The use of chest computed tomography versus chest X-ray in patients with major blunt trauma. *Injury*. 2007;38(1):43–47.

17. Wootton-Gorges SL, Stein-Wexler R, Walton JW, et al. Comparison of computed tomography and chest radiography in the detection of rib fractures in abused infants. *Child Abuse Negl*. 2008;32(6):659–663.

18. Weinberg ER, Tunik MG, Tsung JW. Accuracy of clinician-performed point-of-care ultrasound for the diagnosis of fractures in children and young adults. *Injury*. 2010;41(8):862–868.

19. You JS, Chung YE, Kim D, et al. Role of sonography in the emergency room to diagnose sternal fractures. *J Clin Ultrasound*. 2010;38(3):135–137.

20. Szucs-Farkas Z, Lautenschlager K, Flach PM, et al. Bone images from dual-energy subtraction chest radiography in the detection of rib fractures. *Eur J Radiol*. 2011;79(2):e28–e32.

21. Yazkan R, Ergene G, Tulay CM, et al. Comparison of chest computed tomography and chest x-ray in the diagnosis of rib fractures in patients with blunt chest trauma. *Journal of Academic Emergency Medicine*. 2012;11(3):171.

22. Błasińska-Przerwa K, Pacho R, Bestry I. The application of MDCT in the diagnosis of chest trauma. *Pneumonol Alergol Pol*. 2013;81(6):518–526.

23. Chardoli M, Hasan-Ghaliaee T, Akbari H, et al. Accuracy of chest radiography versus chest computed tomography in hemodynamically stable patients with blunt chest trauma. *Chin J Traumatol*. 2013;16(6):351–354.

Citation: Khan S, Rokhan B, Abbas S, et al. A prospective observational study: The role of ultrasonography in detecting various long bone fractures. An in depth study of a military hospital. *MOJ Orthop Rheumatol.* 2019;11(6):195–199. DOI: 10.15406/mojor.2019.11.00500