Case Report

Open Access CrossMark

The Role of Ilizarov Angiogenesis in Accelerated Healing of Painful Multidrug Resistant Madura Foot Ulcer (A Rare Case Report)

Abstract

Madura foot ulcer is not a common condition. It disturbs the daily activitis of the patient. Pain swelling with multiple nodules with discharging sinus with discoloration (blackening) of the affected area since 2006.

Keywords: Madura foot ulcer, Ilizarov

Volume 11 Issue 2 - 2019

Md. Mofakhkharul Bari,[1] Md. Shahidul Islam,[2] Md. Mahfuzer Rahman,[3] Mbah Emmanuel Obinna[4]

[1]Prof. Ph.D, Chief Consultant, Bari-Ilizarov Orthopaedic Centre, Visiting and Honored Prof., Russian Ilizarov Scientific Centre, Bangladesh
[2]Prof. MD; FCPS, Bari-Ilizarov Orthopaedic Centre, Bangladesh
[3]Ortho- Consultant, Bari-Ilizarov Orthopaedic Centre, Bangladesh
[4]Doing Fellowship on Ilizarov Technique in Bari- Ilizarov Orthopaedic Centre (From Nigeria), Bangladesh

Correspondence: Bari MM, Chief Consultant Bari-Ilizarov Orthopaedic Centre, 1/1, Suvastu Shirazi Square, La.lmatia, Dhaka-1207, Bangladesh, Tel +8801819211595, Email bari.ilizarov31@gmail.com

Received: March 21, 2019 | **Published:** March 27, 2019

Chief complaint

Pain and swelling with discharge from left footwhich is worsening in intensity over the past 6 months. History of Present Illness: Patient with history of NIDDM (since 5 years). HTN (10 years), dyslipidemia (10 years), Eumycotic Mycetoma (10 years), had trial of empirical anti tubercular drugs, anti fungal **(Voriconazole),** IV penicillin, sip biopsy left foot, ultrasound currently complains of worsening of pain, swelling multiple nodules with di schargi ngsi nus anteri orto medial malleolus (discharge is serosanguineous, blood stained mixed with white grains), with discoloration (blackening) of the effected area. Symptoms have worsened since November 2017.

Patient was in his usual state of health until 11 years ago (2006) when he noticed swelling and pain of the left posterior foot. Subsequently in a few months multiple subcutaneous nodules were serosanguineous. Occasionally, white grain was noticed with discharge. Patient was treated initiallyin Bangladesh with empirical antitubercular drug (Isoniazide, Rifampicin, Ithambutol, Pyrizinamide), which was continued for 24 months with no improvement. Two biopsies of the effected area were done in 2007 and 2008 in India which were inconclusive.Patient also had MRIs, however soft copies of results are not available. In India patient had a trail of IV penicillin (4,000,000 units) 6 hourly for 2 months, with no improvement in 2008. Subsequently, it spread from posterior to mid foot (left).

In January 2010, repeat biopsy in Bangkok, Thailand concluded the diagnosis of Eumycotic Mycetoma and subsequently Voriconazole 200 mg twice daily was prescribed which he continued for the next 7 days, with complete resolution of symptoms; but he confirmed the drug. However in March, 2017, symptoms reoccurred while he was on Voriconazole. Patient went to Mycetoma Research Centre (MRC) Khartoum, Sudan. Repeat MRI & USG of left foot was done again, which revealed 2 masses, one mass *deep* to planter aspect and another one medial aspect of mid foot. Surgical exploration and biopsy of mass was done on 09/17/2017 and both masses were removed including over lying involved skin. Then skin grafting was done, below medial malleolus. Sample was sent to Erasmus Medical Centre, Rtterdain, Netherland. Fungus was isolated and still awaiting susceptibility test results (attaching email from Netherland for your review). As per physicians recommendation in Sudan, Voriconazole was stopped and Itraconazole, 200 mg BID was initiated from 11/30/2017 with no improvement in symptoms.

Allergies

No known drug allergies.

Family history

Father and mother both have diabetes, hypetension and dyslipidemi*a* Fellow West African College of Surgeon (FWACS).

Physical examination of the foot

On physical examination of the foot, there are visible multiple subcutaneous nodules with discharging sinus anterior to medial malleolus. These nodules are visiblein 3 cm by 3 cm area. Swelling and tenderness of the foot with discoloration (blackening) of the effected area on palpation, area is attached to the nodules. Range of motion of ankle joint is restricted in all areas including flexion, extension, abduction and adduction.

Current diagnosis

Madura foot with other eo ‘no rbodities NIDDM

HTN

Dyslipidemia

Current medications

Gliclizide 80 mg. once daily Linagliptin 5 mg, once daily Amlodipine 5 mg once daily Losartan Potassium 50 mg once daily

Itraconazole, 200 mg BM since Nov, 2017

Procedures

The surgical procedure was performed at the anteomedial part of lower tibia6 cm long and 2 cm wide. The Ilizarov device consists of 2 rings and 2 olive wires lined to the medial plate. Osteotomy done above and below the olive wires meticulously.[1–3] The tibia section has been moved approximately 1 mm/days for 10 days and again compressed for another 10 days. The clinical status improved within a few weeks. Cure of trophic ulcers and no more excruciating pain.[4–7]

Results

i. No discharging fluid from the ulcer.

ii. Ulcer is healed.

iii. Severe excruciating pain is relieved.

Before Treatment

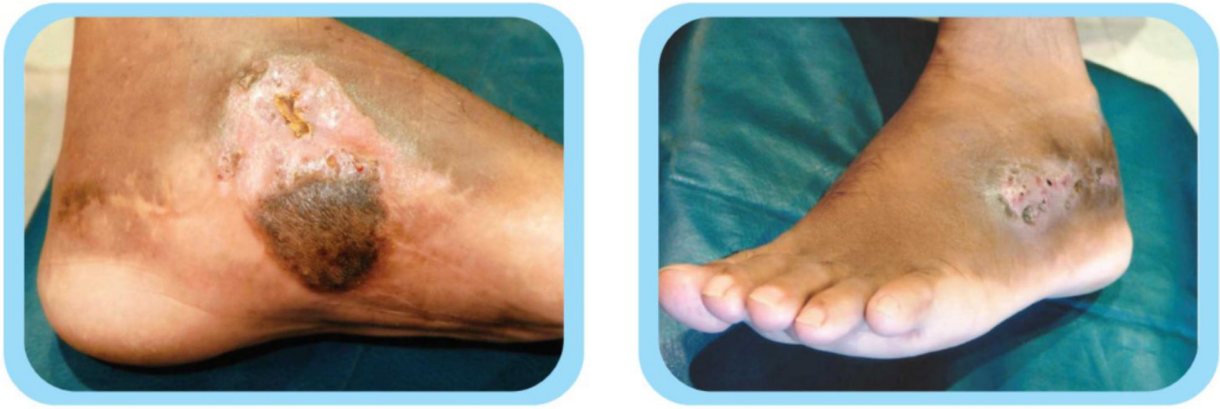

1. Non-healing ulcer.

During Treatment

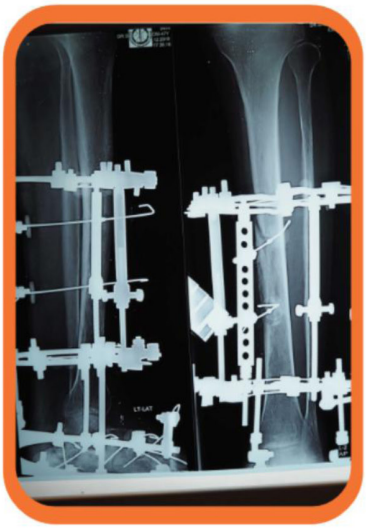

2. During treatment with Ilizarov apparatus

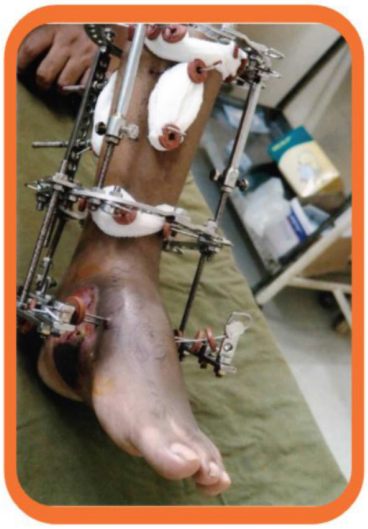

3a. View of medial side with Ilizarov apparatus

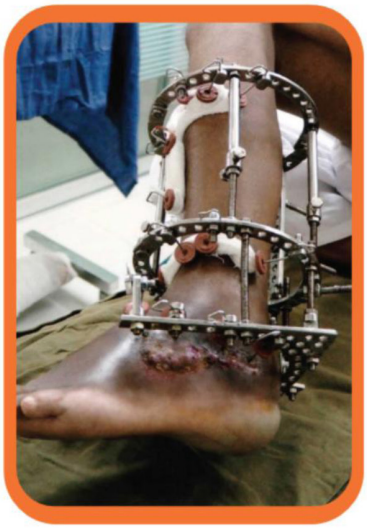

3b. View of lateral side with Ilizarov apparatus

Citation: Bari MM, Islam MS, Rahman MM, et al. The Role of Ilizarov Angiogenesis in Accelerated Healing of Painful Multidrug Resistant Madura Foot Ulcer (A Rare Case Report). *MOJ Orthop Rheumatol.* 2019;11(2):85–87. DOI: 10.15406/mojor.2019.11.00477

After Treatment

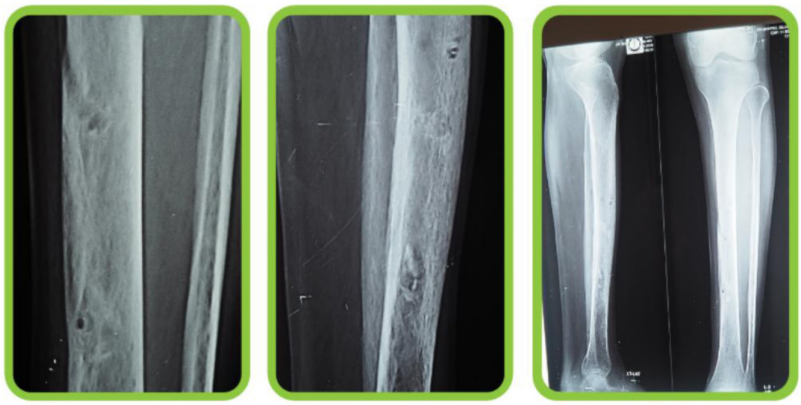

4. After removal of Ilizarov apparatus

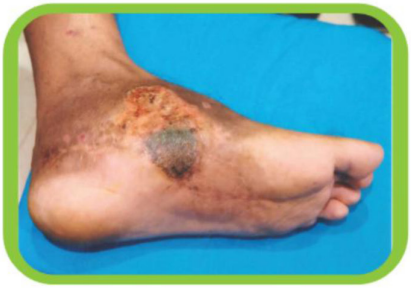

5a

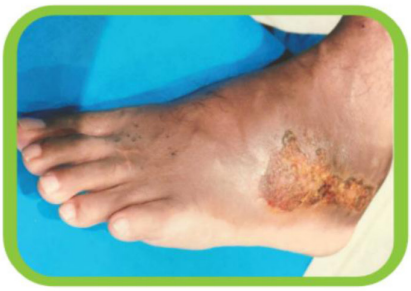

5b

Conclusion

Ilizarov compression distraction device for modura foot ulcer was done with vertical corticotomy of the distal medial tibia. Ilizarov was removed after 12 weeks, Application of this noble device will bring angeogenesis within the reach of all deserving patients.[8,9]

References

1. Ilizarov GA. Transosseous Osteosynthesis theoretical and clinical aspects of the regeneration and growth of tissue. Springer-Verlag Berlin Heidelberg. Germany. 1992; Pp. 800.
2. Bari MM. A color atlas of limb lengthening, surgical reconstruction and deformity correction by Ilizarov technique. 2013;368–375.
3. Ilizarov GA. The principles of the Ilizarov Method. *Bull Hosp Jt Dis Orthop Inst.*1988;48(1):1–11.
4. Ilizarov GA, Frankel GH. The Ilizarov External Fixator. A Physiologic Method of Orthopaedic Reconstruction and Skeletal Correction. *Orthop Rev.* 1988;17(11):1142–1154.
5. Ilizarov GA. The Tension-Stress Effect on the Genesis and Growth of Tissue: Part II. The Influence of the Rate and Frequency of Distraction. *Clin Orthop Relat Res.* 1989;239:263–285.
6. Ilizarov GA. Experimental Studies of Bone Elongation. In: Coombs R, et al. (Eds.), External Fixation and Functional Bracing, Ortho text, London, UK, 1989.
7. Ilizarov GA. Clinical Application of the Tension-Stress Effect for Limb Lengthening. *Clin Orthop Relat Res.* 1990;250:8–26.
8. Movshovich A. Orthopaedic surgery. Moscow, 1983.
9. Paley D. Problems, Obstacles and complications of Limb Lengthening by the Ilizarov Technique. *Clin Orthop Relat Res.* 1990;250:81–104.

Citation: Bari MM, Islam MS, Rahman MM, et al. The Role of Ilizarov Angiogenesis in Accelerated Healing of Painful Multidrug Resistant Madura Foot Ulcer (A Rare Case Report). *MOJ Orthop Rheumatol.* 2019;11(2):85–87. DOI: 10.15406/mojor.2019.11.00477