

Posterior arch defects of the atlas - a report of two cases and literature review

Abstract

Developmental abnormalities of the atlas are rare, but benign abnormalities, firstly reported in 1937 by Plaut, Lawrence and Anderson. The authors report two cases of patients with these defects. The first patient had complaints of neck pain and the second consisted on an incidental finding after a traumatic incident. Both patients were treated conservatively with success.

Little evidence is available on this pathology and is mostly provided by case reports and guidelines for the treatment still lack, making this a challenging entity to diagnose and treat.

Keywords: C1 agenesis, Spine

Volume 9 Issue 4 - 2017

Rita Grazina,¹ Filipe Santos,¹ Renato Andrade,² José Marinhos,^{1,2} Rolando Freitas,¹ Rui Rocha,^{1,2} João Espregueira-Mendes,² Rui Lemos¹

¹Centro Hospitalar Vila Nova de Gaia/Espinho, Portugal

²Espregueira-Mendes Sports Centre, Portugal

Correspondence: Rita Grazina, Centro Hospitalar Vila Nova de Gaia/Espinho, Vila Nova de Gaia, Portugal; Email rita.grazina@gmail.com

Received: October 02, 2017 | **Published:** December 08, 2017

Introduction

Developmental abnormalities of the atlas were first report in 1937 by Plaut, Lawrence and Anderson.¹

These are rare but benign abnormalities found in about 4% of the population. Most of the times, they are incidental findings after cervical trauma and produce no symptoms.

Case 1

An otherwise healthy 33-year-old male was sent to our Orthopaedic Department due to sporadic neck pain after an initial effort.

The patient denied irradiation of the pain and the neurological exam was completely normal. A neck radiograph was obtained, showing a defect in the posterior arch of the atlas (Figure 1). This defect was posteriorly evaluated with a CT-scan and better documented as a segmental aplasia of both hemiarches (Figure 2). Providing the lack of neurological symptoms, the patient was treated conservatively.

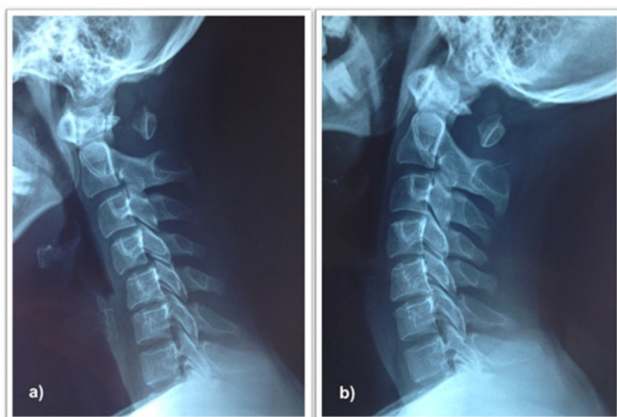


Figure 1 Dynamic radiographs of the cervical spine, showing a defect in the posterior arch of the atlas.

Case 2

A 29-year-old female was brought to our Emergency Department

after a car accident that resulted in right-sided neck pain. The patient presented no neurological deficits.

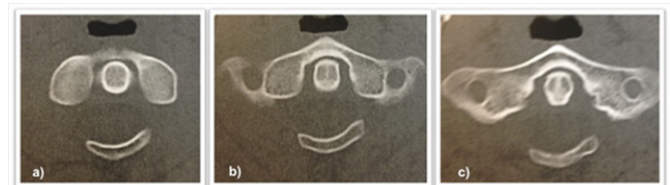

Figure 2 CT-scan (axial) showing a segmental aplasia of both hemiarches of the atlas.

The lateral neck radiograph showed a thin posterior arch of the atlas. Due to the high intensity of the trauma, a CT-scan was obtained revealing a posterior arch defect of C1 in its right portion (Figure 3).

The patient was also treated conservatively.

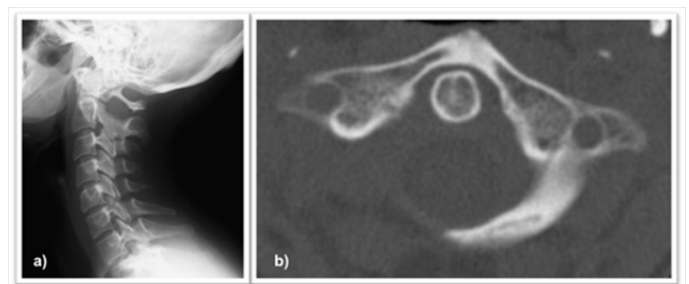


Figure 3 a) Lateral radiograph of the cervical spine revealing a thin posterior arch of the atlas; b) CT-scan (axial) showing a posterior arch defect of the atlas in its right portion.

Discussion

Embryology and pathophysiology

The first cervical vertebra commonly ossifies from three different centers: one for the anterior arch and two for the lateral masses. Around age 3-5 the lateral masses fuse in the midline to form the posterior arch. Between ages 5-9 the anterior center fuses with the remaining vertebra.²

The exact mechanism for the development of these abnormalities is not completely understood.³ Nevertheless, defects in the posterior arch are accepted to be mainly due to failure in chondrogenesis rather than a defect in ossification. This is supported by the findings of connective tissue bridging the defect in autopsies and intraoperative observations.^{1,2}

Posterior arch defects may be associated with several disorders, such as Arnold Chiari malformation, gonadal dysgenesis and a variety of syndromes like Down or Turner.³

Other spine abnormalities have also been described to coexist with posterior arch defects: anterior arch clefts, atlantoaxial instability, cervical myelopathy or downward projections of the foramen magnum.^{3,4}

Classification and epidemiology

The most widely used classification is that of Currarino, who proposed both a clinical and an anatomical classification.^{2,5}

The anatomical classification, modified by Von Torks and Gehle, divide C1 defects in five types:^{2,5}

- I. Type A: the two posterior hemiarches fail to fuse in the midline, creating a gap or fissure.
- II. Type B: the defect is unilateral, presenting as a unilateral cleft or total absence of one of the hemiarches.
- III. Type C: the defect is bilateral, creating a bilateral cleft with persistence of the dorsal part of the arch.
- IV. Type D: there is absence of both hemiarches, with a patent posterior tubercle.
- V. Type E: complete absence of the posterior arch.

The clinical classification divides patients in 5 groups based on clinical presentation.^{5,6}

- I. Group 1: the defect is an incidental finding, as the anomaly is completely asymptomatic.
- II. Group 2: the patients present with neck pain or stiffness after neck or head trauma.
- III. Group 3: the patients present with neurological symptoms after neck or head trauma.
- IV. Group 4: the patients spontaneously present with neurological symptoms for a considerable time before diagnosis.
- V. Group 5: the patients present with chronic complaints about the neck.

Both cadaveric and imagological studies have been conducted reporting estimated incidences of posterior arch anomalies between 0.69 and 4%. About 90% of these are type A defects with the remaining groups being held responsible for about 0.69% of the cases.^{1,2,7}

Clinical presentation

Most of the times posterior arch defects are incidental findings in radiographs obtained mainly after cervical or head trauma. According to the literature most patients are completely asymptomatic and if not for the traumatic episode the condition would have gone completely undiagnosed.⁸ Stability is unlikely to be affected by these defects as, anatomically; atlanto-axial stability is known to be maintained by the alar, apical and transverse ligaments whose attachments are not affected by posterior arch defects.⁹

Nevertheless, types C and D held the potential to cause symptoms as the posterior fragment may move anteriorly upon neck extension thus causing compressive symptomatology.⁹ This was first documented by Sharma et al in their study using dynamic radiographs.^{1,10} These two types may indeed cause transient quadriparesis, a positive Lhermitte sign, chronic neck pain or headache.⁷

According to Dominic Thompson⁹ another entity called true hypoplastic posterior arch which is not considered in Currarino classification might be held responsible for the development of neurological symptoms due to the diminution of the ring diameter.

Imaging

As previously stated, posterior arch defects are usually incidental findings in cervical radiographs obtained for another reason. Usually, lateral radiographs show bilateral defects whether unilateral ones are better identified on oblique incidences. Dynamic radiographs may play a role in exclusion of instability.¹¹

In the context of trauma, these defects might be misdiagnosed as fractures. Typically, posterior arch defects have smooth margins and an intact cortex and there is lack of soft tissue swelling. Conversely, fractures are associated with swelling and have sharp margins. Additionally, lateral displacement of the margins is a common finding in axial compression fractures. Due to its capacity to better analyze these characteristics, CT scan plays an important role in differential diagnosis.¹²

According to the literature, MRI is a dispensable exam, unless neurological symptoms are present. In this case, it should be done as increased T2 signal in the spinal cord might be a finding.¹¹

In type E defects the presence of a posterior ligament between C1 and C2 provides stability, so it might be of importance to confirm its presence using MRI.^{2,5}

Treatment

Most of the existent literature on this matter is based on clinical reports, so conclusions are taken from Class III evidence.⁹

Conservative treatment is the most commonly advocated treatment provided there is no neurological deficit or chronic symptomatology. For those asymptomatic patients with type C or D defects, it seems wise to preclude contact sports as neurological injury might occur. Some authors even consider surgery to prevent cumulative damage to the spinal cord.^{3,10}

All the other asymptomatic patients might not actually need activity modification or even follow-up.⁹

Although there are no clear recommendations, it is legit to conclude from literature that the treatment of patients with neurological symptoms must be surgical. As it happens mainly in patients with type C and D defects, surgery includes excision of the posterior tubercle and, in case of atlantoaxial instability, posterior C1-C2 fusion.¹¹

When dealing with symptomatic patients without neurological deficit the excision of the posterior arch remnant seems effective, providing there is no instability. If instability is present, stabilization must thus be performed.⁹

Concerning case 1, the patient's defect can be classified as a Type C and he fits in Group 2 according to the clinical classification. Once no instability was found, conservative treatment was instituted with full resolution of the symptoms. However, a posterior fusion would also have been a legit treatment possibility considering the hypothesis

of cumulative damage to the spinal cord, which we believe unlikely in this case due to the lack of evidence of instability.

The patient was advised to avoid contact sports as new traumatic episodes might cause the symptoms to return or even neurological damage. Regarding case 2, the defect can be classified as a Type B and also fits Group 2 on the clinical classification. The patient was treated conservatively and no specific advice was given as this corresponds to a stable defect.

Conclusion

Posterior arch defects are most of the times benign, but the few cases most susceptible to neurological symptom development should be identified in order to correctly advise the patient to modify his or her activity or even perform surgery when indicated.

Little evidence is available and guidelines for the treatment still lack, making this a challenging entity to diagnose and treat.

Conflicts of interest

The authors deny any conflict of interest.

Acknowledgements

None.

References

1. Elmalky MM, Elsayed S, Arealis G, et al. Congenital C1 arch deficiency: Grand Round presentation. *Eur Spine J*. 2013;22(6):1223–1226.
2. Mehta UK, Geetha KN, Gaikward M, et al. Posterior arch anomalies of Atlas and its clinical significance. *Int J Med Sci*. 2014;2(4):361–366.
3. Sabuncuoglu H, Ozdogan S, Karadag D, et al. Congenital hypoplasia of the posterior arch of the atlas: case report and extensive review of the literature. *Turk Neurosurg*. 2011;21(1):97–103.
4. Torriani M, Lourenço JLG. Agenesis of the posterior arch of the atlas. *Rev Hosp Clin Fac Med S Paulo*. 2002;57(2):73–76.
5. Currarino G, Rollins N, Diehl JT. Congenital defects of the posterior arch of the atlas: a report of seven cases including an affected mother and son. *Am J Neuroradiol*. 1994;15(2):249–254.
6. Ozdolap S, Sarikaya S, Balbaloglu O, et al. Congenital defects of posterior arch of the atlas: a case report. *Neuroanatomy*. 2007;6:72–74.
7. Kwon JK, Kim MS, Lee GJ. The Incidence and Clinical Implications of Congenital Defects of Atlantal Arch. *J Korean Neurosurg Soc*. 200;46(6):522–527.
8. Razo MAF, Messina AFR, Castilla GFL, et al. Aplasia congénita del arco anterior y posterior del atlas. *Rev Esp Méd Quir*. 2013;18:350–353.
9. Thompson DNP. Expert's Comment concerning Grand Rounds Case entitled Congenital C1 arch deficiency: Grand Round Presentation. *Eur Spine J*. 2013;22(6):1227–1229.
10. Sharma A, Gaikwad SB, Deol PS, et al. Partial aplasia of the posterior arch of the atlas with an isolated posterior arch remnant: findings in three cases. *Am J Neuroradiol*. 2000;21(6):1167–1171.
11. Panagopoulos A, Zouboulis P, Athanaselis E, et al. Aplasia of the posterior arc of the atlas with persistent posterior tubercle: a case report. *Eur Spine J*. 2005;14(2):205–207.
12. Dorne HL, Just N, Lander PH. CT Recognition of Anomalies of the Posterior Arch of the Atlas Vertebra: Differentiation from Fracture. *AJNR*. 1986;7(1):176–177.