

# Reversed shoulder arthroplasty in a patient with fixed anterior glenohumeral dislocation

## Abstract

An anterior glenohumeral dislocation is a serious condition which can lead to soft tissue damage and substantial defects of the humeral head and glenoid. Little is known about the results of shoulder arthroplasty for the treatment of fixed glenohumeral dislocation. We present a case of an fixed anterior glenohumeral dislocation that developed with no associated trauma in a humeral head with an ongoing avascular necrosis in 75 years old patient with Parkinson disease. The patient had severe pain and a pseudo paralysis of the right arm. Radiology revealed a bone loss of the posterior head. The patient was submitted to a reversed shoulder arthroplasty and at 1 year follow up is happy with no pain; the subjective outcome scores substantially increased and had fair gains in arm mobility with no evidence of instabilities or other complications. We believe, based on the literature, and on recent advances in the implants and surgical technique, that shoulder reverse arthroplasty will probably achieve better results than unconstrained shoulder implants in treating fixed anterior dislocations in geriatric patients.

**Keywords:** Reversed shoulder arthroplasty, Fixed glenohumeral dislocation, Avascular necrosis, Parkinson disease

Volume 6 Issue 7 - 2016

Tiago P Marques,<sup>1</sup> Miguel B Moita,<sup>1</sup> Jaime Babulal,<sup>1</sup> Pedro M Branco,<sup>1</sup> Rita R Santos,<sup>1</sup> Jorge H Costa,<sup>2</sup> Carlos M Dias<sup>1</sup>

<sup>1</sup>Department of Orthopedic Surgery, Hospital Santarem, Portugal

<sup>2</sup>Department of Orthopedic Surgery, Hospital Sao Jose, Portugal

**Correspondence:** Tiago Paiva Marques MD, Knee and Shoulder Surgery, Hospital Santarem, Portugal  
Email tiagopaivamarques@gmail.com

**Received:** December 27, 2015 | **Published:** December 28, 2016

## Abbreviations

ROM: Range of Motion, VAS: Visual Analogue Scale, ASES: Society of American Shoulder And Elbow Surgeons, SSV: Subjective Shoulder Value, CT: Computed Tomography

## Introduction

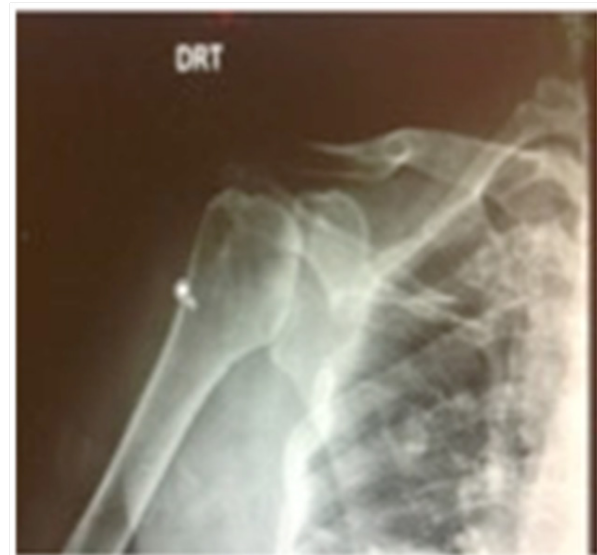An anterior glenohumeral dislocation is a serious condition which can lead to soft tissue damage and substantial defects of the humeral head and glenoid. Disturbance of shoulder joint congruency and soft tissue balancing can lead to poor function and severe impairment in these patients.<sup>1</sup> Little is known about the results of shoulder arthroplasty for the treatment of fixed glenohumeral dislocation. The main reports are from small case series and with use of hemiarthroplasty and total shoulder replacement. The results of arthroplasty in this patient population have more complications and problems than in arthritis patients. Pain is usually controlled after surgery but the functional results are limited. We describe a case of a fixed anterior glenohumeral dislocation treated with a reversed shoulder arthroplasty.<sup>2-4</sup>

## Case presentation

A 75-year-old female patient presented with a chronic right shoulder pain for the last two years, with diminished ROM, intense pain during day and night and with activities. She had progressive limitations in her activities of daily life. The symptoms were progressive in the last 2 years. On clinical examination she had global shoulder tenderness, intense pain and a pseudoparalysis of the right arm. The pain was evaluated with VAS score, and ASES and SSV scores were also applied. The patient scored 9 points in VAS score, 5 points in ASES score and 0% in SSV score. The comorbidities of the patient were: hypertension, atrial fibrillation and Parkinson disease. She was under medication and medical surveillance.

Right shoulder radiographic evaluation demonstrated an avascular necrosis of the humeral head. It was ordered a CT scan and next appointment scheduled to discuss the surgical plan.

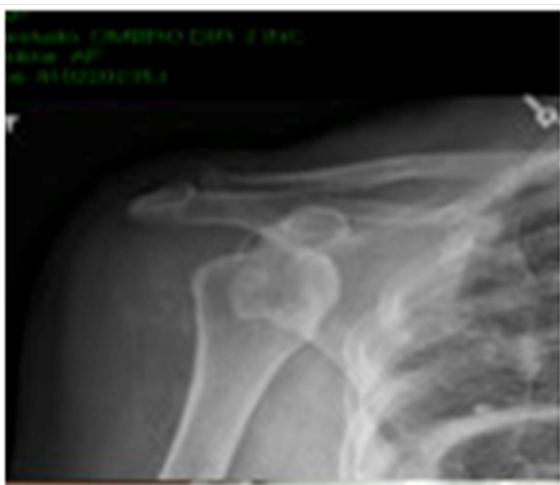The patient returned 1 month later, with new complaints. Numbness in the right forearm and hand with no specific nerve territory identified and with agravated pain in passive mobilisation of the arm. Denied any form of trauma or decompensation of the medical pathologies. New X-ray were made and revealed an anterior glenohumeral dislocation with an important bone loss defect in the posterior area of the humeral head. Evaluation of the CT scan confirmed those findings and revealed an intact glenoid rim.



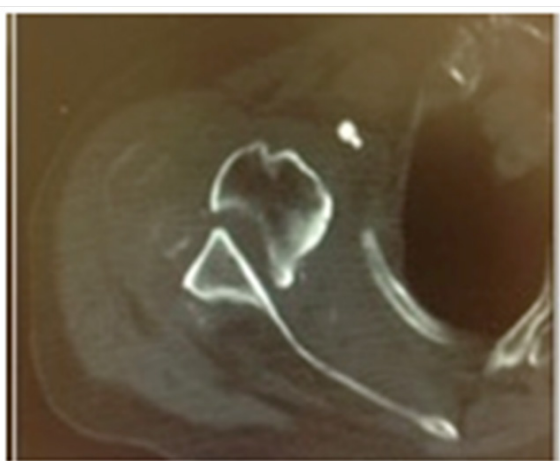
**Figure 1** Right shoulder AP X-Ray demonstrating cephalic avascular necrosis.

In this context of a 75-years-old Parkinson disease patient under control, with a fixed anterior glenohumeral dislocation, avascular necrosis of the humeral head and posterior bone loss, we planned to do a shoulder reversed arthroplasty to obtain pain control, joint stability and functional gains. Deltopectoral approach was used, intra operatively was evident a rupture of the supraspinatus and anterior portion of the infraspinatus. A cylinder of autologous cancellous

bone graft, harvested from the humeral head, was placed between the reamed glenoid surface and baseplate. This was accomplished with specific instrumentation of the implant, Tornier Aqualis II Bio RSA. The humeral stem was cemented and no specific alteration of the version of the humeral stem was made to prevent possible anterior instability, since with trial instrumentation the ROM was good and no instability was recorded. The patient is now 1-year post operative, she is happy and very satisfied with the surgical outcome, almost with no pain and she is able to do some activities of daily life. On clinical examination ROM is improved with 80° of forward flexion and abduction, internal rotation to gluteus and 15° of external rotation. No signs of instability. The scores improvement was notorious, VAS 3 points, ASES 58 points and SSV 60%.



**Figure 2** Right shoulder AP X-Ray demonstrating fixed anterior glenohumeral dislocation.



**Figure 3** Right shoulder CT scan axial view, demonstrating glenohumeral anterior fixed dislocation and posterior bone loss of the humeral head.

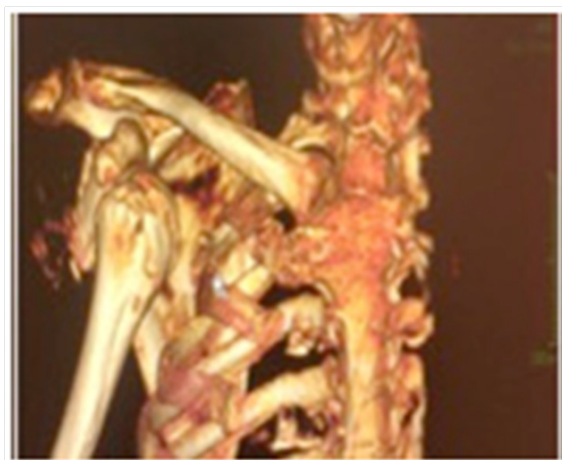
Radiologically there was an apparently resorption of the glenoid graft but the glenosphere is stable and no scapular notching is observed.

### Discussion

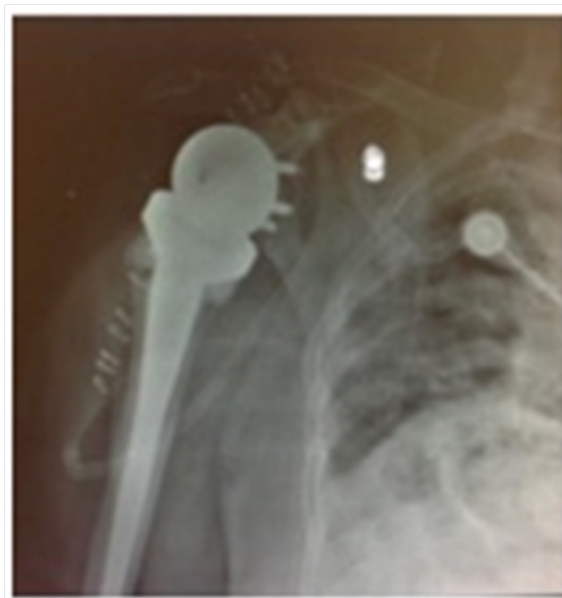Dislocation of the humeral head in this age can lead to cuff ruptures and posterior head bone loss. This mechanical defect can contribute to permanent dislocation.<sup>1,5-7</sup>

In our case we managed to obtain a good pain control, VAS score diminished from 9 points to 3 points, fair functional results with 80°

of forward flexion and abduction, internal rotation to gluteus and 15° of external rotation. The ASES score improved 53 points to a total of 58 points and SSV score improved from 0% to 60%. The results in pain control and patient satisfaction are very good. Functional results are good but are less good than results of reversed shoulder arthroplasty in arthritis patients.<sup>8</sup> No instability problems were noted at 1 year follow up. One common complication in reversed arthroplasty is instability, but being a constrained implant, has less instability problems than hemi or total shoulder arthroplasty. No scapular notching or progressive radiolucent lines were identified in x-ray, but the glenoid graft had signs of resorption, without evidence of instability of the glenosphere. Boileau et al. reported the use of this bony lateralization reversed shoulder arthroplasty. In their series of 42 patients with 2 years follow up the humeral graft incorporated completely in 98% of cases (41 of 42) and partially in one. At a mean of 28 months postoperatively, no graft resorption, glenoid loosening, or postoperative instability was observed.<sup>9</sup>



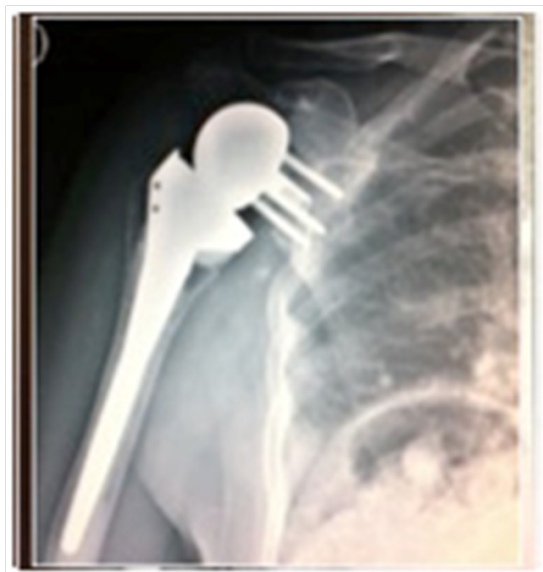**Figure 4** Right shoulder CT scan 3D reconstruction, demonstrating glenohumeral anterior fixed dislocation.



**Figure 5** Postoperative right shoulder AP X-ray.

Our graft probably resorbed because of two main reasons. First from the low quality cancellous bone harvested from the necrotic head did not have the sufficient “biology boost” to consolidation and second because of the bone metabolism abnormalities that are consequence

of Parkinson disease, and interfere with bone osteoblastic activity, and negatively influenced the consolidation of the graft.<sup>10</sup>



**Figure 6** One-year follow up right shoulder AP X-ray, demonstrating evidence of a resorbed glenoid graft.



**Figure 7** One-year follow up, 85° active forward flexion and internal rotation to gluteus.

Reports using arthroplasty to treat fixed shoulder dislocations are in the literature, but mostly a hemiarthroplasty or a total shoulder arthroplasty is used. In 2006 Matsoukis et al. reported their series of 11 patients with fixed anterior glenohumeral dislocation treated with hemiarthroplasty or total shoulder arthroplasty. They had a mean follow up of 48 months and identified 7 complications in five shoulders. Four cases of recurrent anterior dislocation were identified and in two of these cases glenoid loosening occurred. Bone graft migration was described in one case. In another case removal of a screw was performed, and in one case removal of a glenoid component was performed in a revision surgery. The authors report an age and gender adjusted Constant score of 60% 48 months after operation with a mean active shoulder abduction of 90° and a mean active external rotation of 26°. Raiss et al.<sup>4</sup> used a humeral head resurfacing to treat 10 patients with fixed anterior glenohumeral dislocations. In one case a re-rupture of the subscapularis tendon occurred after redislocation two weeks after arthroplasty and in another case an erosion of the glenoid cartilage was associated with severe pain leading to revision with total shoulder arthroplasty. The mean Constant score improved

from 20 points preoperatively to 61 points postoperatively and the difference was statistically significant. Significant differences between pre to postoperative were also found for pain relief, shoulder flexion and abduction and external rotation. Eight patients were satisfied or very satisfied with the procedure. They believe that rotator cuff reconstruction, namely the subscapularis, is crucial to avoid redislocation and gain good clinical results in their series.<sup>1</sup>

Shoulder arthroplasty in patients with Parkinson disease presents substantial challenges. However, very little information exists about the outcome of shoulder arthroplasty in this patient population. Even less is the data about the results of reversed arthroplasty in this subset of patients. Kryzak et al.<sup>10</sup> reported following 43 TSAs in patients with PD over a mean of 8 years. Eight of these TSAs underwent revision arthroplasty; 3 of the 8 were revised within 1 year of the index repair because of instability. Overall, 20 of the 43 patients (47%) reported unsatisfactory results, though pain was significantly reduced, from a preoperative mean of 4.6 to a postoperative mean of 1.8.<sup>11</sup> Earlier, Koch and colleagues followed 13 TSA cases in patients with PD over a mean of 5.3 years. Although pain relief was significant, functional results were poor. Only 6 patients reported satisfactory or better results, and 3 cases required revision surgery (2 for symptomatic subluxation, 1 for glenoid loosening).<sup>12</sup>

Our case had numerous risk factors, fixed anterior dislocation in a progressive cephalic avascular necrosis in a Parkinson disease patient. So the main concern was about possible instability with prosthesis dislocation and an expected poor functional result. The literature alerts for that, but the analysis are made with the use of hemi or total shoulder arthroplasty, that are unconstraint implants that theoretical favor instability if the soft tissues are not of quality or ruptured, for example the subscapularis.<sup>2,4,13</sup> The reversed shoulder arthroplasty does not rely in the cuff, because the new center of rotation obtained, tensions the deltoid muscle and increases its lever arm, remaining the working horse of reversed shoulder arthroplasty mobility. Nonetheless a disrupted subscapularis can be a risk factor for dislocation.<sup>14</sup> Another concern is the glenoid wear with the hemiarthroplasty, and the glenoid loosening, with total shoulder arthroplasty. If there is instability in the shoulder from a ruptured or nonfunctional cuff, the forces acting in the humeral head implant will be eccentric, resulting in the “rocking horse glenoid” phenomenon that his one of the main causes on glenoid loosening in total shoulder arthroplasty.<sup>15</sup>

In an attempt to maximize our results we choose to do a reversed shoulder arthroplasty in this patient, achieving good outcome avoiding complications. We believe, based on the literature and on recent advances in the implants and surgical technique, that shoulder reverse arthroplasty will probably achieve better results than unconstrained shoulder implants in treating fixed anterior dislocations in geriatric patients. More extensive research is needed to establish the role of reversed shoulder arthroplasty, for treatment of fixed anterior glenohumeral dislocations.

## Acknowledgments

None.

## Conflicts of interest

None.

## References

1. Raiss P, Aldinger PR, Kasten P et al. Humeral head resurfacing for fixed anterior glenohumeral dislocation. *International Orthopaedics (SICOT)*. 2009;33(2):451–456.

2. Pritchett JW, Clark JM Prosthetic replacement for chronic unreduced dislocations of the shoulder. *Clin Orthop Relat Res.* 1987;216:89–93.
3. Rowe CR, Zarins B Chronic unreduced dislocations of the shoulder. *J Bone Joint Surg Am.* 1982;64(4):494–505.
4. Matsoukis J, Tabib W, Guiffault P et al. Primary unconstrained shoulder arthroplasty in patients with a fixed anterior glenohumeral dislocation. *J Bone Joint Surg Am.* 2006;88(3):547–552.
5. Hovelius L, Augustini BG, Fredin H et al. Primary anterior dislocation of the shoulder in young patients. A ten-year prospective study. *J Bone Joint Surg Am.* 1996;78(11):1677–1684.
6. Rowe CR, Zarins B, Ciullo JV Recurrent anterior dislocation of the shoulder after surgical repair. Apparent causes of failure and treatment. *J Bone Joint Surg Am.* 1984;66(2):159–168.
7. Widjaja AB, Tran A, Bailey M, Proper S Correlation between Bankart and Hill–Sachs lesions in anterior shoulder dislocation. *ANZ J Surg.* 2006;76(6):436–438.
8. Boileau P, Watkinson D, Hatzidakis AM et al. Neer Award 2005: the Grammont reverse shoulder prosthesis: results in cuff tear arthritis, fracture sequelae, and revision arthroplasty. *J Shoulder Elbow Surg.* 2006;15(5):527–540.
9. Boileau P, Moineau G, Roussanne Y et al. Bony Increased–offset Reversed Shoulder Arthroplasty Minimizing Scapular Impingement While Maximizing Glenoid Fixation. *Clin Orthop Relat Res.* 2011;469(9):2558–2567.
10. Dunn J, Byrne AN, Higgins LD Reverse Total Shoulder Arthroplasty in Patients With Parkinson Disease: A Case Series and Review of the Literature. *Am J Orthop.* 2011;40(12):625–629.
11. Kryzak TJ, Sperling JW, Schleck CD et al. Total shoulder arthroplasty in patients with Parkinson’s disease. *J Shoulder Elbow Surg.* 2009;18(1):96–99.
12. Koch LD, Cofield RH, Ahlskog JE Total shoulder arthroplasty in patients with Parkinson’s disease. *J Shoulder Elbow Surg.* 1997;6(1):24–28.
13. Giannotti S, Bottai V, Dell’Osso G et al. Stemless humeral component in reverse shoulder prosthesis in patient with Parkinson’s disease: a case report. *Clin Cases Miner Bone Metab.* 2015;12(1):56–59.
14. Gallo RA1, Gamradt SC, Mattern CJ et al. Instability after reverse total shoulder replacement. *J Shoulder Elbow Surg.* 2011;20(4):584–590.
15. Schrupf M, Maak T, Hammoud S et al. The glenoid in total shoulder arthroplasty. *Curr Rev Musculoskelet Med.* 2011;4:191–199.