

Ultrasound Guided Regional Anesthesia: Ultrasound Guided Axillary Nerve Block versus Ultrasound Guided Infraclavicular Nerve Block: A Comparison Study for the Lower Third of the Upper Limb Surgery (Initial Study)

Background

Axillary and Infraclavicular nerve block may be used for many types of elbow, forearm and hand surgery.

This study has a purpose to compare efficiency of these two blocks according to different levels of upper extremity surgery including influences of many different technical and logistic parameters.

Materials & Methods

The patients were chosen randomly and allocated to receive loco regional anesthesia (Performing ultrasound axillary (USAB) or Infra clavicular (USICB) block for upper extremity surgery). The Two techniques were allowed. In plane approach was used.

Integration and exclusion criteria's had been set up and were roughly respected. We use a Toshiba Ultra Sound machine with linear array at 7 MHz.

Bupivacaine 0.5 % was the most commonly selected anesthetic solution. The first 21 patients are used to show an initial

comparison between the two blocks using ultrasound technique and figuring only 4 variable parameters: (Block success, surgery level, incidents, time of proceeding) (Figures 1&2).

Proceeding

Volume 6 Issue 3 - 2016

Chebbah H^{1*}, Boudahdir A¹ and M Matouk²

¹Service Anesthésie, Etablissement Publique Hospitalier (EPH) Ain Defla, Algeria

²Département Anesthésie, Réanimation CHU, Algeria

*Corresponding author: Chebbah H, EPH Ain Defla, Algeria, Tel: +213661776772; Email: imprezional@hotmail.fr

Received: August 18, 2016 | Published: November 09, 2016

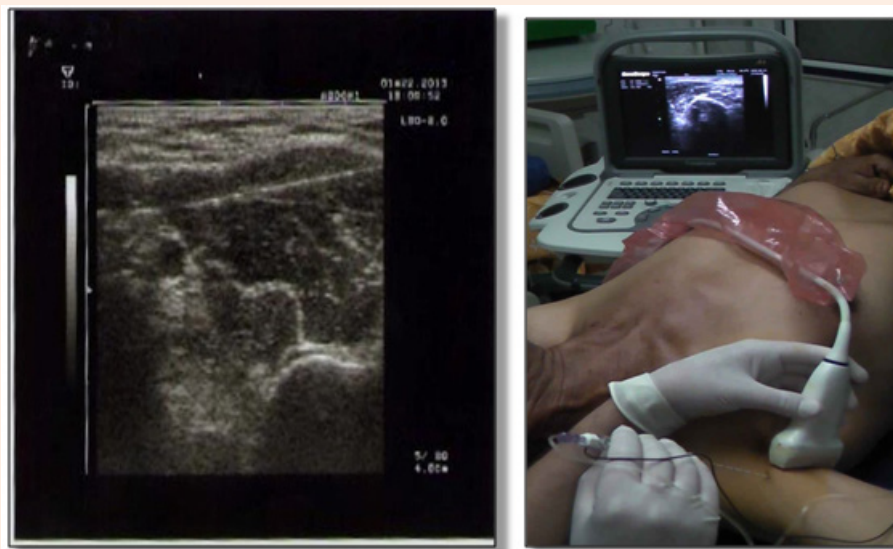


Figure 1: Axillary Nerve Block.

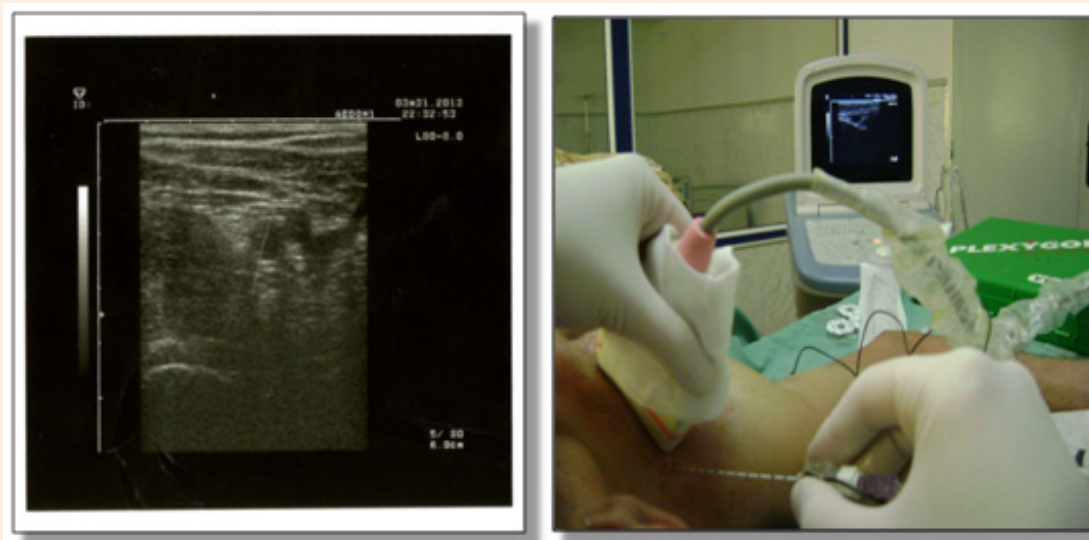


Figure 2: Infra Clavicular Nerve Block.

Results

Over the 21 patients, 13 received USAB and 8 were underUSICB. Neurostimulating was needed with 4 patients. Success rate of the USAB was 87% and 77% for theUSICB. (p value: 0.6350). The distribution of the patients depending of the level of the surgery; the hand (57%) forearm (28.5 %) and arm (14.5%). The median time of proceeding was 20 min for USAB against 24 min forUSICB (p value 0.2755). The injection resistance has been encountered only once even in the USAB and theUSICB, (p value 1). Paresthesia and pain during block process were seen 6 and 7 times in the USAB while the score was 3 and 5 times for theUSICB (p value 1) (Figure 3 & Table 1).

Table 1: Proceeding Time (minutes).

Block	Moyenne	Effectif (n)	Ecart Type	Minimum	Maximum	Variance
Axillary	20.18	11	10.362	9	45	107.364
Infra Clavicular	24.38	8	8.634	15	40	74.554
Total	21.95	19	9.652	9	45	93.164

Conclusion

Initial results seem to show that there's no significant difference between the two ultrasound blocks in term of success rate. Also for incidents such as paresthesia, pain and injection resistance, where it seems that the two blocks are similar in risks. This example gives a good correlation with the literature. Time of proceeding seems to be too similar for the two blocks despite of the needle characteristics or level of surgery. Detailed analysis seems to indicate primarily that the USAB is too much suitable for

the hand rather than the forearm or the elbow surgery, and on the other side theUSICB is more suitable for forearm surgery but no more for the hand one. These results stay preliminary and should be completed and updated till the end of the work.

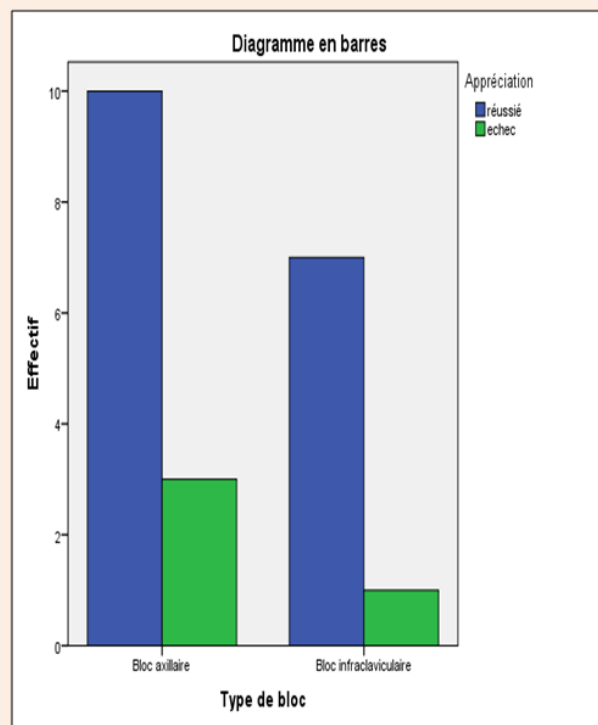


Figure 3: Success and Fail scores.

References

1. Chin KJ, Singh M, Velayutham V, Chee V (2010) Infraclavicular brachial plexus block for regional anesthesia of the lower arm. *Anesth Analg* 111(4): 1072.
2. McCartney CJ, Lin L, Shastri U (2010) Evidence basis for the use of ultrasound for upper-extremity blocks. *Reg Anesth Pain Med* 35(2 Suppl): S10-S15.