

Ilizarov fixator in the management of benign, malignant and complicated cases of bone tumours

Abstract

Objective: evaluate the Ilizarov fixator in the management of bone tumours regarding the duration and the ease of the procedure, the outcome and the complications.

Methods: This study was done at the Department of Orthopedic surgery in Ain Shams University Hospitals. 15 patients with benign or malignant tumours were treated by resection followed by bone and soft tissue reconstruction and Ilizarov circular fixator in January 2012-April 2013 and followed up till July 2014.

Results: Follow-up was done with a mean period of 21.7 (14-28) months. Adjustment of the frame was done as required. As regards malignant tumours, the disease free survival has a mean of 22.8 (12-30) months. 2 patients developed local recurrence. The overall survival was a mean of 25.8 (13-30) months. 1 patient died as a result of chemotherapy. The MSTs score was 50% to 100% with a mean value of 84.6%. ASAMI-bone score was excellent in 53% of the cases, good in 2 cases, fair in 1 case but poor in 4 cases. ASAMI-function score was excellent in 53% of cases, good in 33% of cases, fair in 1 case and poor in 1 case. The adverse effects were 7 problems, 5 obstacles and 6 complications according to Paley's classification.

Conclusion: Biological reconstruction using Ilizarov circular fixator should be considered safe and effective in the management of benign and low grade malignant tumours, and a salvage treatment in case of failure of other methods of limb salvage.

Volume 6 Issue 3 - 2016

Sherif F Ahmed Kamel,¹ Mohamed Abdel Rahman,² Salah A Abou Seif²¹Lecturer of Orthopedic Surgery, Ain Shams University, Egypt²Professors of Orthopedic Surgery, Ain Shams University, Egypt

Correspondence: Sherif F Ahmed Kamel, Department of Orthopedic Surgery, Faculty of Medicine, Ain Shams University, Cairo, Egypt, Tel (+20)(12)25090586, Email sheriff_farid@med.asu.edu.eg

Received: November 07, 2016 | **Published:** November 07, 2016

Introduction

Amputation was the main treatment of malignant bone tumours, however it is currently used selectively and infrequently. Limb preserving procedures are now used because of effective chemotherapy protocols and medications, improved imaging modalities, and advanced reconstructive surgery. The patient age, site of the tumour and stage of disease help to determine the most efficient surgical treatment. Options for skeletal reconstruction include endoprostheses, allografts, allograft-prosthetic composites, vascularised bone grafts, arthrodesis, expandable prostheses, rotationplasty, and limb-lengthening techniques. Two crucial points must be considered. Firstly, the rates of survival should be equivalent or better than those associated with amputation. Also, the reconstructed limb must be functional. Functional outcome studies comparing limb-sparing procedures and amputation have restrictions, such as the inability to randomize treatment and the subjective nature of crucial outcome measures.¹

Distraction osteogenesis means the use of a distraction force to induce the formation of skin, muscle, nerve, vascular structures, connective tissue, lymphatic vessels, and bone. Although, the first devices were used for limb lengthening, this biologic process is now used to treat many other orthopaedic conditions, such as nonunion; malunion; angular deformities due to congenital, developmental, or traumatic conditions; segmental bone loss due to trauma or infection; joint contractures; burn contractures; and talipes equinovarus.²

In the case of skeletal reconstruction, bone defects are ideally repaired with viable bone reconstruction. Distraction osteogenesis with a ring fixator that was developed by Ilizarov and callotasis with a unilateral fixator by De Bastiani, have been universally used for the management of many orthopaedic problems.³⁻⁶ The main advantage of distraction osteogenesis is that it can achieve regenerated viable bone with the same strength and width as that of the native bone.

Peripheral nerves, vessels, muscles, tendons, ligaments, and skin are also gradually lengthened with a ratio to the lengthened bone.⁷ The Ilizarov method is a safe means of limb reconstruction in the setting of primary or secondary reconstruction of bone tumours. Limb lengthening, bone transport, repair of nonunion, and correction of deformity, in the setting of bone tumours management, could be safely and effectively managed by the circular fixator.⁸

Patients and methods

This study was done at the department of orthopedic surgery in Ain Shams University hospitals. The study was done on 15 patients with benign or malignant tumours, who were treated by resection followed by bone and soft tissue reconstruction and Ilizarov circular fixator during January 2012-April 2013; and the cases were followed up till July 2014. The mean age of the patient was 21.1(7-52) years old. The patients were 9 male and 6 female. They present with different pictures; the most common was pain only, deformity, and pain with swelling. 7 cases were benign and 8 cases were malignant. The most common pathology was osteosarcoma (5 cases). The most common anatomical site was the distal tibia (4 cases). 7 patients only underwent previous surgeries.

Inclusion criteria

- Sex: Both sexes.
- Age: 5-60 years.
- Shortening or bone defect more than 2 cm or limb deformity in benign or malignant tumours with good prognosis.

Exclusion criteria

- Psychiatric disorder or refusal to have a circular fixator.
- Malignant tumours with poor prognosis.

The patients were evaluated clinically (history, general and local examinations), radiologically (plain x-ray, CT scan, MRI, isotope bone scan, and arteriography), laboratory investigations and biopsy of needed.

According to the above measures, the patients were staged according to the surgical staging system of Enneking (1980), which is now the universal system for tumours staging adopted, by the musculoskeletal tumour society.⁹

Preoperative neoadjuvant chemotherapy was given to the osteosarcoma cases (5 cases)

Operative technique

- a. Anesthesia (general or regional), positioning, sterilization and draping.
- b. Surgical approach according to the location of the tumour and exposure of the tumour mass without breaching it.
- c. Resection of the tumor (marginal if benign, or wide if malignant).
- d. Application of the circular fixator (e.g. Ilizarov) as appropriate.
- e. Corticotomy was done if distraction osteogenesis had been planned to restore the length or for proper angular deformity correction. Otherwise, the Ilizarov frame was used as a static external fixator.
- f. Reattachment of ligaments and tendons ensuring adequate soft tissue coverage.
- g. Wound closure in layers and dressing.

Postoperative management

- A. Histopathological Examination of the resected segment for assessment of the response to preoperative chemotherapy e.g. by measuring the tumor necrosis index.
- B. Follow up Proper antibiotic and sedation in the first few days postoperatively
- C. X –ray films were done in at least two views.
- D. Patients with tumours in the lower limbs were given prophylaxis against DVT.
- E. Adjuvant chemotherapy was given in osteosarcoma cases starting from about two weeks after removal of the stitches.
- F. The patients will be followed up in the out-patient clinic at regular intervals; weekly for 2 months, twice per month for the next 4 month, then monthly till removal of the frame, and then on regular basis according to the oncological diagnosis. This assessment will include :

G. This assessment will include :

- i. Assessment of malignant tumours
- ii. Clinical and functional assessment

We used the standard system of musculoskeletal tumour society (MSTS) with its modification developed by Enneking et al.⁹

Radiological assessment

- a. Local recurrence.
- b. Systemic recurrence and metastasis.
- c. Bone formation and skeletal defect restoration

Assessment of the Ilizarov fixator

Using the classification of the Association for the Study and Application of the Method of Ilizarov (ASAMI) based on clinical (functional) and radiological (bony) findings.⁸

Results

Follow-up was done with a mean period of 21.7 (14-28) months. In the office, assessment of the outcome as regards the tumour and the Ilizarov fixator was done using the MSTS score for all cases and the ASAMI-bone and ASAMI-function scores for the cases.⁸ Moreover, adjustment of the frame was done as required.

As regards malignant tumours, the disease free survival has a mean of 22.8 (12-30) months. 2 patients developed local recurrence. The overall survival was a mean of 25.8 (13-30) months. 1 patient died as a result of chemotherapy.

As regards all cases, the MSTS score was 50% to 100% with a mean value of 84.6%. As regards the ASAMI-bone score, it was excellent in 53% of the cases, good in 2 cases, fair in 1 case but poor in 4 cases. The ASAMI-function score was excellent in 53% of cases, good in 33% of cases, fair in 1 case and poor in 1 case.

The adverse effects in our study were 7 problems, 5 obstacles and 6 complications according to Paley’s classification.¹⁰ The most common adverse event was pin tract infection, which was more severe in patient’s receive (Tables 1,2 and Figures 1-4).

Table 1 MSTS score for cases (B= benign, M= malignant)

Case	Tumor	MSTS score	Percentage
Case 1	B	29	97
Case 2	M	21	70
Case 3	B	29	97
Case 4	B	28	93
Case 5	M	19	63
Case 6	B	25	83
Case 7	B	28	93
Case 8	M	16	53
Case 9	B	30	100
Case 10	M	15	50
Case 11	M	29	97
Case 12	M	27	90
Case 13	B	28	93
Case 14	M	28	93
Case 15	M	29	97

Table 2 Number of lower limb cases in each category of ASAMI score

Score	ASAMI-bone	ASAMI-functional
Excellent	8	8
Good	2	5
Fair	1	1
Poor	4	1

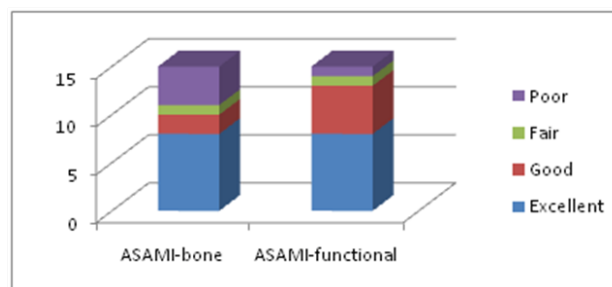


Figure 1 A stratified bar graph showing the results of lower limb cases as regards ASAMI scores.

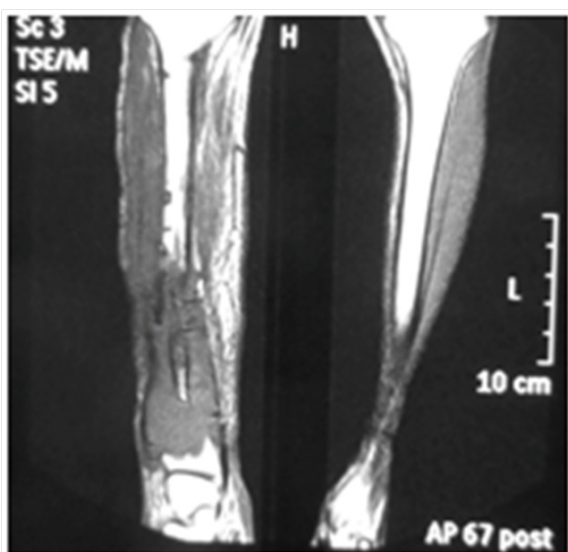


Figure 2 MRI coronal cut of the leg showing local recurrence in case 2.

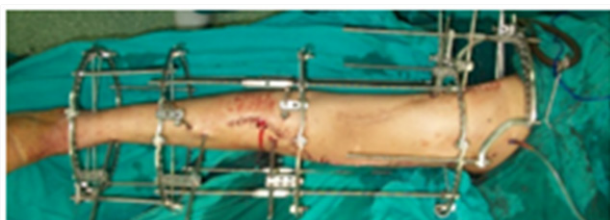

Figure 3 Application of Ilizarov frame in case 1.

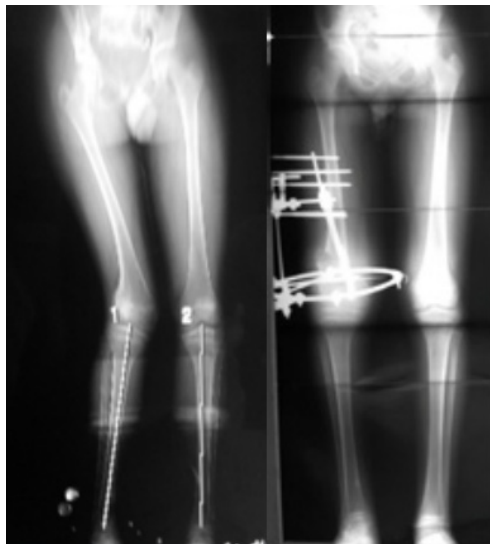

Figure 4 Case 9 (A: preoperative scannogram, B: scannogram after full correction).

Discussion

The aim of this study is to assess the efficacy and safety of the use of the Ilizarov fixator in the management of a wide range of benign and malignant tumours. We were tempted by the well-developed literature that supports this technique.

When we compare our results to those of McCoy T.H. et al (2012) (8) study, we find that our study was shorter in the period of follow-up (a mean follow-up of 22.8 months in our study as compared to

81.7 months in their study) and our MSTS score was less (84.6% as compared to 93%). Moreover, we had more complications (6 versus 2) but fewer obstacles (5 versus 18). We think that this might be because we have included complicated cases with previous surgeries as cases 8 and 10 and cases who received chemotherapy as in osteosarcoma cases, which was not present in McCoy et al study. Also, we included more cases with malignant tumours (50% against 35% of cases). However, our ASAMI-bone score was better (66% of cases were excellent and good in comparison to 65%) as well as our ASAMI-function score (87% of cases were excellent and good in contrast to 65%). We believe that this might be due to the younger age of our cases (mean 21.1 years old in opposition to 22.6 years). Also, we did not use distraction osteogenesis in all cases (the frame was used statically for fixing pedicled fibula transfer in some cases).

If we compare our results with those of Tsuchiya et al.,¹¹ we find that we had lower ASAMI-function score (87% were excellent and good versus 89% in their study). This might be a result of including complicated cases with previous surgeries as cases 8 and 10 and their cases received intra-arterial chemotherapy, which is more effective than conventional chemotherapy. On the other hand, we had fewer complications (2 versus 10). The reason for this might be that we did not use the Ilizarov frame dynamically for bone transport in all of our cases. Moreover, they had used intramedullary nailing in some cases to reduce the external fixation time, and this additional procedure might add to the causes of complications.

It is evident that we had more complications than Tsuchiya et al.¹² study. This could be due to that we have included a variety of benign and malignant tumours together with complicated cases with previous operations, but they included benign cases only. If we compare the benign cases in our study without previous operations, we can see that our complications were comparable.

In contrast to Erler K et al.¹³ study, our adverse events were less (18 against 21), we had better functional score (87% of cases were excellent and good as compared to 77% of cases in their series). This could be due to their smaller sample size (9 versus 15) and more cases with malignant tumours in their study (66% of cases versus 50%) in ours. Table 16 discusses the differences between our study and the previous studies.

The adverse effects in our study were 7 problems, 5 obstacles and 6 complications according to Paley's classification. The most common adverse event was pin tract infection, which was more severe in patients receiving chemotherapy (osteosarcoma cases). This was contradictory to the results of the study done by Tsuchiya et al.¹⁴ on the safety of external fixation during postoperative chemotherapy who concluded that post-operative chemotherapy for malignant bone tumours did not adversely affect the ability to achieve union or cause hypertrophy of the vascularised fibular graft and had a minimal effect on distraction osteogenesis.

We suspect that the adverse events, as contractures, in our study were due to lack of compliance of some patients and prolonged external fixation time. These patients were reluctant to do adequate joint motion exercises while in the Ilizarov frame. Others refused to stop smoking (case 2) which had led to development of infection and delayed union or weak regenerate. Also, poor personal hygiene in some cases enhanced the occurrence of infection. In case 10, the patient was subjected to heavy doses of radiotherapy after previous successful tumor surgery, which results in endarteritis obliterans and repeated infection and failure of grafting.

Conclusion

Biological reconstruction using Ilizarov circular fixator should be considered safe and effective in the management of benign and low grade malignant tumours, and a salvage treatment in case of failure of other methods of limb salvage.

Acknowledgments

None.

Conflicts of interest

None.

References

1. DiCaprio MR, Friedlaender GE. Malignant bone tumours: limb sparing versus amputation. *J Am Acad Orthop Surg*. 2003;11(1):25–37
2. Murray JH, Fitch RD. Distraction histiogenesis: principles and indications. *J Am Acad Orthop Surg*. 1996;4(6):317–327.
3. De Bastiani G, Aldegheri R, Renzi-Brivio L, et al. Limb lengthening by callus distraction (callotaxis). *J Pediatr Orthop*. 1987;7(2):129–134.
4. Ilizarov GA. The Transosseous Osteosynthesis: Theoretical and Clinical Aspects of the Regeneration and Growth of Tissue. *Springer-Verlag, Berlin*. 1992.
5. Ilizarov GA. The tension–stress effect on the genesis and growth of tissues: Part I. The influence of stability of fixation and soft–tissue preservation. *Clin Orthop*. 1989;238:249–281.
6. Podolsky A, Chao EY. Mechanical performance of Ilizarov circular external fixators in comparison with other external fixators. *Clin Orthop*. 1993;293:61–70.
7. Tsuchiya H, Tomita K. Distraction osteogenesis for treatment of bone loss in the lower extremity. *J Orthop Sci*. 2003;8:116–124.
8. McCoy TH, Kim HJ, Cross MB, et al. Bone tumor reconstruction with the Ilizarov method. *J Surg Oncol*. 2013;107(4):343–352.
9. Enneking WF, Dunham W, Gebhardt MC, et al. A system for the functional evaluation of reconstructive procedures after surgical treatment of tumours of the musculoskeletal system. *Clin Orthop Relat Res*. 1993;286:241–246.
10. Paley D. Problems, obstacles, and complications of limb lengthening by the Ilizarov technique. *Clin Orthop relat Res*. 1990;250:81–104.
11. Tsuchiya H, Tomita K, Minematsu K, et al. Limb salvage using distraction osteogenesis. A classification of the technique. *J Bone Joint Surg Br*. 1997;79(3):403–411.
12. Tsuchiya H, Morsy AF, Matsubara H, et al. Treatment of benign bone tumours using external fixation. *J Bone Joint Surg Br*. 2007;89(8):1077–1083.
13. Erler K, Yildiz C, Baykal B, et al. Reconstruction of defects following bone tumor resections by distraction osteogenesis. *Arch Orthop Trauma Surg*. 2005;125:177–183.
14. Tsuchiya H, Shirai T, Morsy AF, et al. Safety of external fixation during postoperative chemotherapy. *J Bone Joint Surg Br*. 2008;90(7):924–928.