

Bone Marrow Injection for Treatment of Aneurysmal Bone Cyst

Research Article

Volume 5 Issue 3 - 2016

Mahmoud Abdel-Ghany*, Wael M Shaaban, Abdel-Hamied A Atallah, Tharwat M Abdel-Rahman and Tohamy G Hassan

Department of Orthopedics, Faculty of Medicine, Egypt

***Corresponding author:** Mahmoud I Abdel-Ghany, Assistant Professor of Orthopedic and Trauma Surgery Faculty of Medicine for Girls, Egypt, Email: mhghany@hotmail.com

Received: February 26, 2016 | **Published:** July 29, 2016

Abstract

Study design: Patients had Aneurysmal bone cyst lesion that underwent to be treated by Injection of Autologous Bone Marrow Aspirates (ABM) and follow up of this case for the final results.

Patients and Methods: Sixteen patients had had Aneurysmal bone cyst had been treated by ABM injections. Study have 16 patients 11 females (68.75 %) and 5 male (31.25 %). Age ranged from 3-14 years with average age 7.5 years. Number of injections for every patient ranged from 2-6 times with average 4.4 times. This study including 5 cases (31.25 %) with proximal femoral cyst, 9 cases (56.25 %) had tibial cyst (2 distal and 7 proximal tibia) and 2 cases (12.5 %) had proximal humeral cyst. All patients treated by injection of Autologous Bone Marrow Aspirates which obtained from the iliac crest. The bone marrow aspirates was obtained percutaneous by bone marrow aspiration needle, According to follow up X-ray during injections we decide continuity of injections. Average size of the defect was 2.3 cm. and average amount bone marrow/inj. Was 10.2 cc.

Results: Pain Score according to VAS ranged from 3-9 with average 5.7 which was improved to average 1.5 at final follow up. Healing time ranged from 21 - 90 days with average 42.2 days. Motion of the arm as patients can move their arm without pain was allowed. Weight bearing for the lower limbs also had been allowed as patients felt pain subsided even there is no complete healing radiological.

Conclusion: Aneurysmal Bone cyst has risk for fracture and recurrence after various modalities of treatment. Bone marrow has the advantage of percutaneous treatment (minimal Invasive) and has no recurrence reported for the current study.

Introduction

Aneurysmal bone cyst (ABC) is a benign, tumor-like, highly vascular, locally aggressive, and relatively rare osteolytic lesion of unknown etiology [1]. Treatment options for aneurysmal bone cysts are simple curettage with or without bone grafting, complete excision, embolization, radiation therapy, or a combination of these modalities [2,3]. Radical surgical excision should be the goal of surgery to decrease the recurrence rate. Recurrence rate is significantly lower in case of total excision [4].

Autologous MSC have been harvested, processed, and read ministered according to protocols distinct for the target application. It ranges from simple single-step approaches by injection of unprocessed or concentrated blood or bone marrow aspirates, to fabrication of engineered constructs by natural or synthetic scaffolds with cells [5]. Percutaneous injection of autologous bone marrow [6,7], allogenic demineralized bone matrix, and percutaneous curettage and bone grafting had been used with widely variable success rate [8].

Material and Methods

Sixteen patients had aneurysmal bone cyst had been treated by ABM injections. Study have 16 patients 11 females (68.75 %) and 5 male (31.25 %). Age ranged from 3-14 years with average

age 7.5 years. Number of injections for every patient ranged from 2-6 times with average 3.0 times. Interval between injections was 2-3 weeks according to the size of the defect. This study including 5 cases (31.25 %) with proximal femoral cyst, 9 cases (56.25 %) had tibial cyst (2 distal and 7 proximal tibia) and 2 cases (12.5 %) had proximal humeral cyst. Three cases (18.75 %) had been discovered after fractures and treated conservatively by slab, cast or traction with persistence of parts of the cyst. Repeated fractures at the same site of the cyst recorded in 3 cases with more conservative treatment. Measurements of the cyst sizes were calculated by MRI views ranged from 3-21 cm with average size 14.8 cm.

All patients treated by injection of autologous bone marrow aspirates which obtained percutaneous from the iliac crest. Site of aspiration was changed every 3 ml. either in depth or directions. According to the size estimated by the MRI the amount of bone marrow is aspirate was obtained on heparinized syringes (Figure 1). Percutaneous injection of bone marrow to the site of the cyst till resistance for injection and cyst cannot contain more aspirates. Many cases has to aspirate the blood contents of the cyst before injections; especially those whom coming without previous fractures. Amount of aspirated marrow reduced every time and needs for aspirates in the last injections may not need to more than 5-7 cc. of aspirated bone marrow. Average numbers

of injections were 4.4 times ranged from 3-6 with time intervals between injections 2-3 weeks (Table 1). Clinical evaluations every visit and routine X-ray before injections has to be obtained to

follow up the progress of healing. Average size of the defect was 2.3 cm. and average amount bone marrow/inj. Was 10.2 cc.

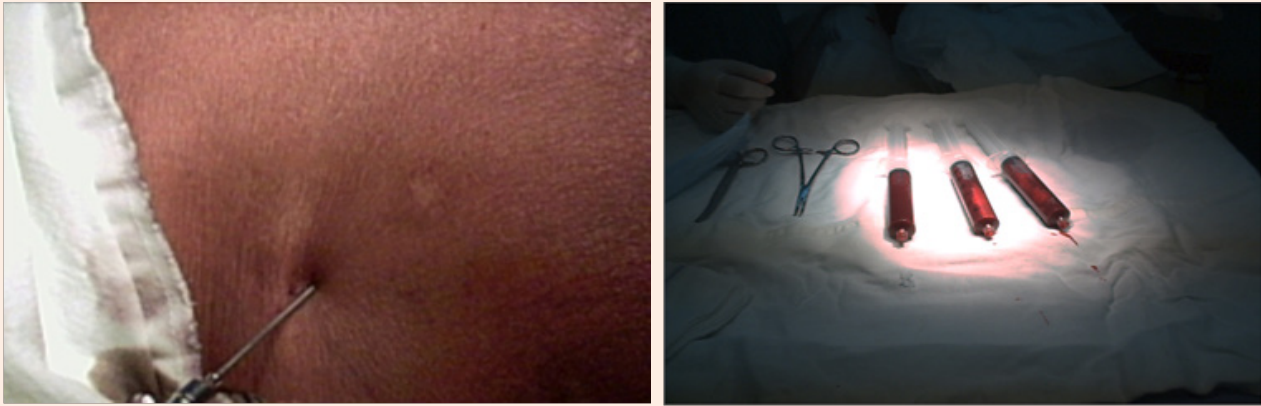


Figure 1: A: Percutaneous aspiration from the posterior Iliac crest, B: Bone marrow aspirates in heparinized syringes.

Table 1: Patients data preoperative postoperative.

S.No	Age	Time for Healing	No. of Injection	Size of Select (L)	Circumference	Size/cm	AVEGE of BMA\Inj	VAS Pre	VAS Post
1	3	21	4	7	3.5	24.3	11.75	9	1
2	6	35	4	9	2.5	22.5	12.5	10	1
3	5	42	2	5	1	5	4.5	8	3
4	11	28	3	8	1.5	12	9	9	0
5	9	49	4	9	3	27	15	10	4
6	4	63	6	4	3.5	15	10	10	2
7	12	42	3	4	2	8	6	9	1
8	5	28	4	7	2	14	15	8	3
9	7	70	2	8	3	24	30	10	3
10	14	90	2	6	2.5	15	12	10	2
11	4	28	2	8	2	16	20	10	2
12	6	35	2	9	2	18	15	10	1
13	3	49	4	4	2	8	10	8	0
14	9	21	3	7	2	14	10	9	0
15	12	35	2	8	1.5	12.5	10	9	0
16	11	42	2	3	1	3	15	10	2
Average	7.6	42.3	3.0	6.6	2.1	14.8	12.8	9.3	1.5

Results

Follow up ranged from 18 months to 4 years for all patients. Close follow up until clinical improvement and radiological consolidation of the cyst. Pain Score according to Healing time ranged from 21 - 90 days with average 42.2 days. Motion of the arm as patients can move their arm without pain was allowed. Weight bearing for the lower limbs also had been allowed as patients felt pain subsided even there is no complete healing radiological. Painless non supported gait was observed and

normal full activity with returning to their ordinary activities for all patients. Sports activities like football and running were return to normal in 7 children five out of them had tibial cyst (Figures 2 & 3) and other two patients had proximal femoral cyst (Figures 4 & 5) were returning to their normal sport activities. VAS ranged from 3-9 with average 5.7 which was improved to average 1.5 at final follow up (Figure 6). At final radiological evaluation we found all cases had consolidated felling of cysts by bony tissue in X-ray film and continuity of the cortical osseous structures. No cases of recurrence were observed for the last follow up of all patients.

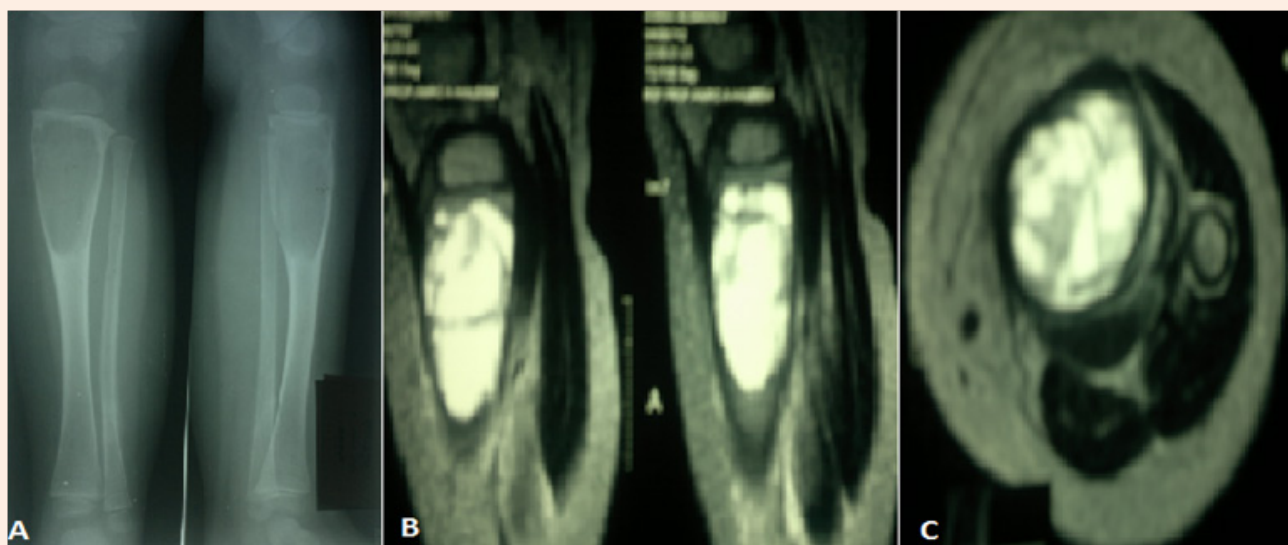


Figure 2: Juxta articular tibial aneurysmal bone cyst close to proximal physis in 3 years old girl A. Plain X-ray AP and lateral B,C: MRI of the same case sagittal and axial cuts shows septum and how the cyst is close to physis.

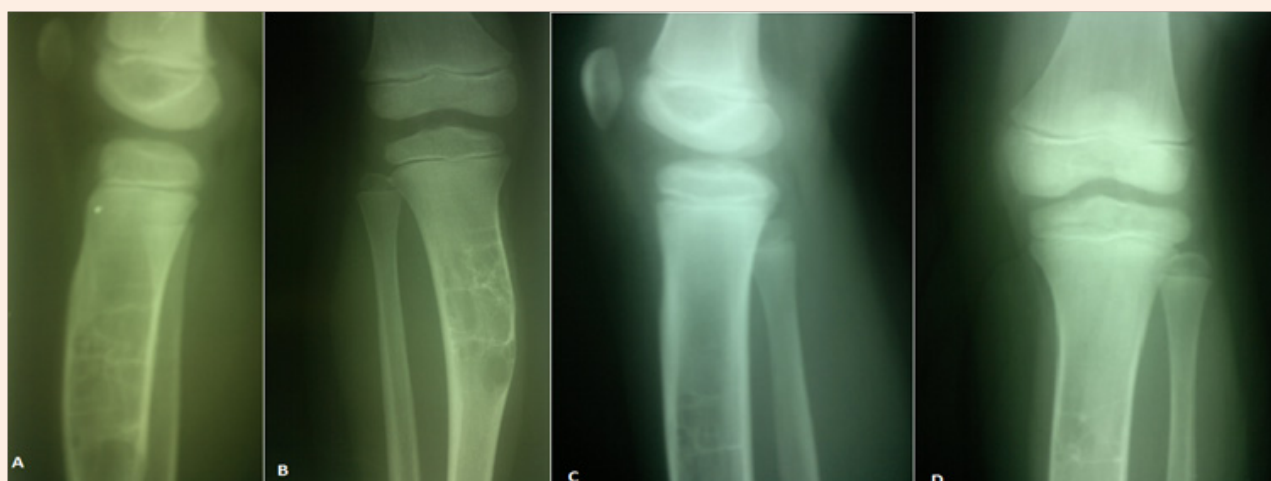

Figure 3: Follow up X-ray for the girl A,B: 2 years follow up with formed tibia, C,D : 3 years follow up of the patients with remodeling of the tibia and normal consolidated bone.

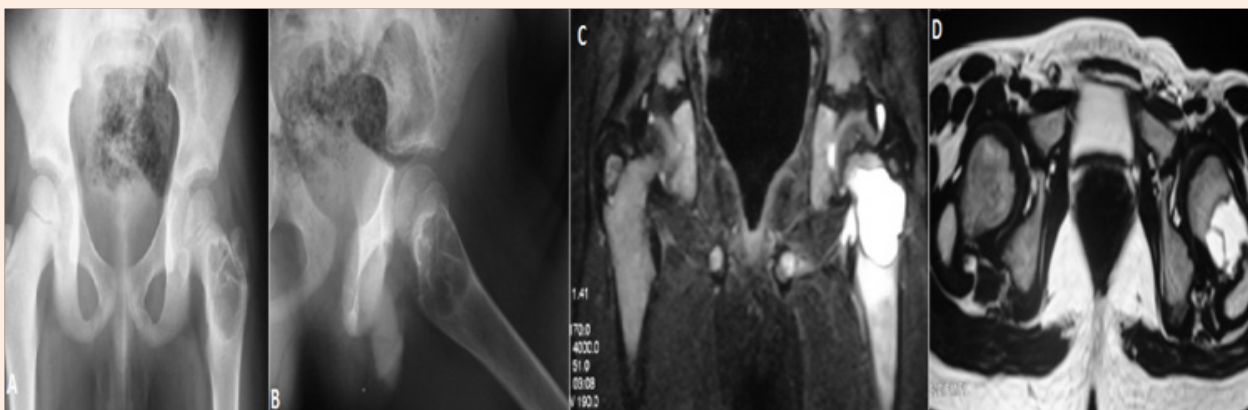

Figure 4: A, B: Plain X-ray with proximal femoral Aneurysmal bone cyst AP and Lat. C,D: MRI pelvis with huge cyst close to the physes.

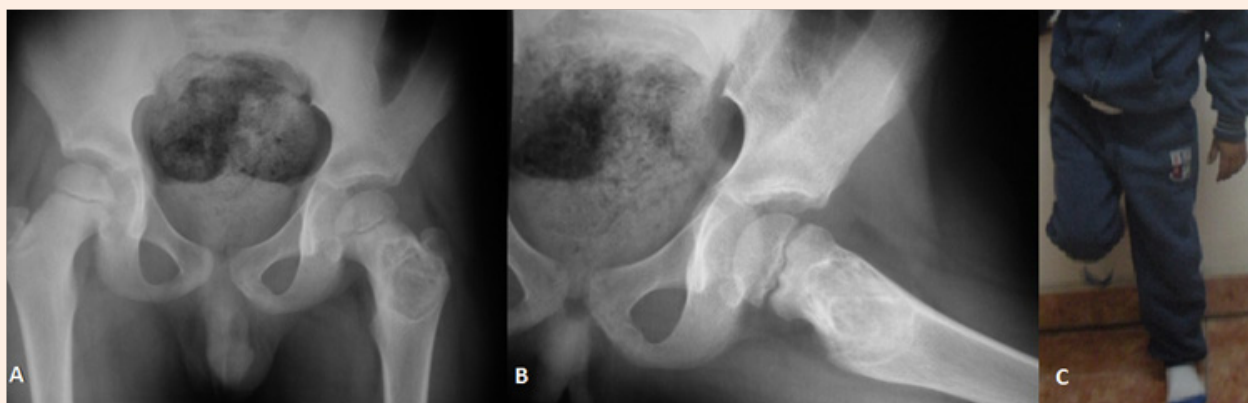


Figure 5: Follow up 3months Plain X-Ray with consolidated bone and patient can stand on his affected limb.

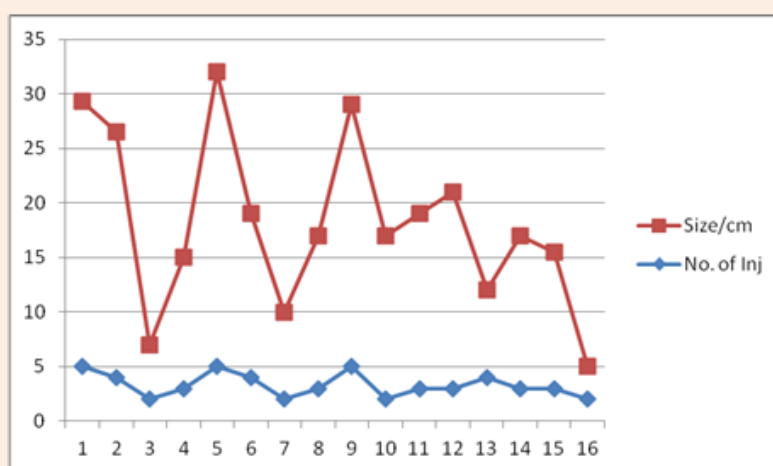


Figure 6: Shows the relation between size of defect and number of injections.

Discussion

The prevalence of Aneurysmal bone cyst (ABCs) is 1.4 cases per 100,000 individuals, and they constitute approximately 1 % of all bone tumors [1,9]. It is known as benign, highly vascular, locally aggressive tumors and there are reports for its recurrence rates after curettage were reported to be equal or less than 50 % [10].

Treatment of ABC is also controversial. The options for treatment are curettage with or without bone grafting, complete excision, arterial embolization, intralesional drug injections (steroid and calcitonin), and radiation⁽²⁾. En bloc resection is preferred when the ABC is growing superficially and eccentrically and more than half of the bone width is intact. Careful curettage and bone grafting still remains the surgical method of choice in the majority of cases, when the ABC is more destructive and affects the subchondral bone of the joints [11]. Despite this osteogenic characteristic, the clinical use of marrow as an osteogenic source has remained limited [12]. In this study all patients with aneurysmal bone cyst treated by repeated percutaneous autologous bone marrow aspiration and intralesional injection which had neither harvested site wounds nor injection site. Bhargava et al 2007 mentioned that the advantage of use of bone marrow without operative exposure of either the donor or recipient site [12]. Bone allografts, this material are employed mainly for reconstruction of cases with bone defects. Disadvantages include the risk of transmission of infectious agents and the risk of fracture due to bone fragility

Selective arterial embolization is available since 1980s and shows much promise for treating aneurysmal bone cyst in small studies. Few cases have been treated with this therapy and gives variable results in several studies [13]. Another method of treatment is intralesional injections for that difficult case like juxtaarticular cysts which is difficult to treat by surgical approach or there is a risk in surgery [14]. Depending on the size and nature of the lesion, the patient's fluid volume and blood loss may have to be monitored closely. Special consideration is necessary in dealing with aneurysmal cysts that are near open physes [15].

In this study we have 5 cases (31.25 %) (2 cases of proximal tibial cyst and 3 cases with proximal femoral cyst) had juxtaarticular aneurysmal huge cyst and no needs for adjuvant material during intralesional injection of BMA with complete consolidation. Special consideration is necessary in dealing with ABCs that are near open physes. In literature there is a special consideration then operating around physes. The reported rate of physeal injury is significant, and patients and their families must be made aware of this possibility. Furthermore, it has been shown that attempts to spare the adjacent physes by performing less than aggressive curettage of ABCs have resulted in increased risk of local recurrence in patients with open growth plates [15,16].

Patients suffering from aneurysmal bone cyst require a long follow-up due to the possibility of late recurrence of the tumor [15]. Some studies have reported recurrence rates as high as 59% with intralesional excision [17] and as low as 0% with resection [18]. In this studies with 3 years follow up there are no recurrence has been observed for all case Hammadi and Cole treated four children with ABC by saucerization of the cyst and injection

of BM after open excision of all new bone formation under the periosteum. They concluded that bone marrow injections are likely to augment the healing of aneurysmal cysts of long bones treated with saucerization as well as reducing the morbidity and costs of alternative bone-grafting methods [19].

Relatively little has been written regarding ABCs arising near growth plates. In one study from the Rizzoli Institute, a juxtaepiphyseal location was associated with an increased risk of subsequent growth arrest and skeletal deformities [20]. Cummings et al. [21] used Argon beam in group of ABC and inject intralesional phenol and they didn't find any differences between group treated by Argon beam with or without phenol injection [21]. Shiel II et al. [22] reported 20 cases of ABC treated by percutaneous injection of Doxycycline; they considered build up of normal bone cortex is a sign of healing with low recurrence rate (5%) [22]. Brosjö et al. [23] reported case with aggressive aneurysmal bone at the proximal humerus in Sweden women was successfully treated using sequential percutaneous injections of polidocanol after exclusion of malignancy [23].

Conclusion

Aneurysmal Bone cyst has risk for fracture and recurrence after various modalities of treatment. Bone marrow has the advantage of percutaneous treatment (minimal Invasive) and has no recurrence reported for the current study. Risk and precautions should be considered at cysts close to physes can be treated easily by this simple technique. However we have no cases of recurrence but we suggest this method of treatment for the recurrent cases which were treated before by any other surgical procedure.

References

1. Ruiter DJ, van Rijssel TG, van der Velde EA (1977) Aneurysmal bone cysts: a clinicopathological study of 105 cases. *Cancer* 39(5): 2231-2239.
2. Tsai JC, Dalinka MK, Fallon MD, Zlatkin MB, Kressel HY (1990) Fluid-fluid level: a nonspecific finding in tumors of bone and soft tissue. *Radiology* 175(3): 779-782.
3. Weinstein JN (1991) Differential diagnosis and surgical treatment of primary benign and malignant neoplasm. In: Frymoyer JW (Eds.), *The adult spine: principles and practice*. Raven Press, New York, pp. 830-850.
4. Zileli M, Isik HS, Ogut FE, Is M, Cagli S, et al. (2013) Aneurysmal bone cysts of the spine. *Eur Spine J* 22(3): 593-601.
5. Steinert AF, Rackwitz L, Gilbert F, Nöth U, Tuan RS (2012) Concise Review: The Clinical Application of Mesenchymal Stem Cells for Musculoskeletal Regeneration: Current Status and Perspectives. *Stem Cells Transl Med* 1(3): 237-247.
6. Lokiec F, Ezra E, Khermosh O, Wientroub S (1996) Simple bone cysts treated by percutaneous autologous marrow grafting. A preliminary report. *J Bone Joint Surg Br* 78(6): 934-937.
7. Yandow SM, Lundeen GA, Scott SM, Coffin C (1998) Autogenic bone marrow injections as a treatment for simple bone cyst. *J Pediatr Orthop* 18(5): 616-620.
8. Killian JT, Wilkinson L, White S, Brassard M (1998) Treatment of unicameral bone cyst with demineralized bone matrix. *J Pediatr Orthop* 18(5): 621-624.

9. Leithner A, Windhager R, Lang S, Haas OA, Kainberger F (1999) Aneurysmal bone cyst. A population based epidemiologic study and literature review. *Clin Orthop Relat Res* 363: 176-179.
10. Vergel De Dios AM, Bond JR, Shives TC, McLeod RA, Unni KK (1992) Aneurysmal bone cyst. A clinicopathologic study of 238 cases. *Cancer* 69(12): 2921-2931.
11. Szendrői M, Cser I, Kónya A, Rényi-Vámos A (1992) Aneurysmal bone cyst. A review of 52 primary and 16 secondary cases. *Arch Orthop Trauma Surg* 111(6): 318-322.
12. Bhargava R, Sankhla S, Gupta A, Changan R, Gagal K (2007) Percutaneous autologous bone marrow injection in the treatment of delayed or nonunion. *Indian J Orthop* 41(1): 67-71.
13. Rossi G, Rimondi E, Bartalena T, Gerardi A, Alberghini M, Staals EL, et al. (2010) Selective arterial embolization of 36 aneurysmal bone cysts of the skeleton with N2butyl cyanoacrylate. *Skeletal Radiol* 39(2): 161-167.
14. Bush CH, Adler Z, Drane WE, Tamurian R, Scarborough MT, et al. (2010) Percutaneous radionuclide ablation of axial aneurysmal bone cysts. *AJR Am J Roentgenol* 194(1): W84-W90.
15. Otsuka T, Kobayashi M, Sekiya I, Yonezawa M, Kamiyama F, et al. (2001) A new treatment of aneurysmal bone cyst by endoscopic curettage without bone grafting. *Arthroscopy* 17(7): E28.
16. Lin PP, Brown C, Raymond AK, Deavers MT, Yasko AW (2008) Aneurysmal bone cysts recur at juxtaphyseal locations in skeletally immature patients. *Clin Orthop Relat Res* 466(3): 722-728.
17. Schreuder HW, Veth RP, Pruszczynski M, Lemmens JA, Koops HS (1997) Aneurysmal bone cysts treated by curettage, cryotherapy and bone grafting. *J Bone Joint Surg* 79(1): 20-25.
18. Marcove RC, Sheth DS, Takemoto S, Healey JH (1995) The treatment of aneurysmal bone cyst. *Clin Orthop Relat Res* 311: 157-163.
19. Hemmadi SS, Cole W (1999) Treatment of aneurysmal bone cysts with saucerization and bone marrow injection in children. *J Pediatr Orthop* 19(4): 540-542.
20. Capanna R, Springfield DS, Biagini R, Ruggieri P, Giunti A (1985) Juxtaepiphyseal aneurysmal bone cyst. *Skeletal Radiol* 13(1): 21-22.
21. Cummings JE, Smith RA, Heck RK (2010) Argon Beam Coagulation as Adjuvant Treatment after Curettage of Aneurysmal Bone Cysts; A Preliminary Study. *Clin Orthop Relat Res* 468(1): 231-237.
22. Shiels II WE, Mayerson JL (2013) Percutaneous Doxycycline Treatment of Aneurysmal Bone Cysts With Low Recurrence Rate: A Preliminary Report. *Clin Orthop Relat Res* 471(8): 2675-2683.
23. Brosjö O, Tsagozis P (2014) Treatment of an aggressive aneurysmal bone cyst with percutaneous injection of polidocanol: a case report. *J Med Case Rep* 8: 450.