

Clinical and radiographic results of kyphoplasty with mid-term follow-up

Abstract

The goal of our retrospective case series is to understand better the demographics and outcomes of kyphoplasty in improving pain in insufficiency fractures that are non-responsive to conservative treatment, identify risk factors for recurrence of back pain due to new fractures or not, discern and understand the timing for symptom improvement after the procedure, and correlate the amount of vertebral height correction with clinical improvement. We hypothesized that kyphoplasty would be effective for pain management in vertebral compression fractures that have been refractory to clinical management. Eighty-one patients underwent kyphoplasty and were followed at two, four, and nine weeks and at one year. Demographics, clinical and radiographic outcomes, and risk factors for new fractures and other complications were analyzed. Maximal improvement in the VAS was seen at two weeks in 90% of our patients and at nine weeks 100% reached maximal improvement. At one-year follow up, recurrent or new onset back pain was noted in 27% of patients, while only 24% of had new vertebral fractures. Fractures at the adjacent level accounted for 50% of the new onset insufficiency vertebral fractures. Approximately 50% of patients had passed away or were not reachable at one year. Also, 50% of our osteoporotic compression fractures happened at the upper lumbar spine. Female sex was the only significant risk factor for subsequent new onset back pain. Male sex and lumbar fractures responded worse to the kyphoplasty treatment. Finally, the amount of radiographic reduction did not correlate with clinical outcomes. From the data analyzed from this case series, we found that kyphoplasty provides a safe and effective treatment for pain in patients with vertebral compression fractures.

Keywords: Kyphoplasty, Pain management, Visual analog scale, SF-36

Volume 1 Issue 4 - 2014

Robert Ryu,¹ Ferno Techy,² Vivek Mohan,³
Anis Mekhail⁴

¹Department of Orthopaedics, Ohio State University Wexner Medical Center, USA

²Rocky Mountain Associates in Orthopedic Medicine, USA

³Spine Center of Dupage Medical Group, USA

⁴Department of Orthopaedic Surgery, University of Illinois at Chicago, USA

Correspondence: Robert Ryu, Department of Orthopaedics, The Ohio State University, 725 Prior Hall, Columbus, OH 43210, USA, Tel (614) 293-2165, Email Robert.Ryu@osumc.edu

Received: June 26, 2014 | **Published:** December 20, 2014

Abbreviations: VAS, Visual Analog Scale; SF-36, Short-Form Health Survey; SD, Standard Deviation; R, Range

Introduction

Kyphoplasty and vertebroplasty present minimally invasive treatment alternatives for pathological vertebral compression fractures that have failed nonoperative management. The global prevalence of vertebral compression fractures is estimated to be approximately 1.4 million,¹ including 750,000 in the United States.² The actual prevalence of vertebral osteoporotic compression fractures is unknown because of the lack of standardization in how vertebral compression fractures are defined as well as the subsequent overall lack of diagnosis.³ Some have estimated that only 30% of vertebral compression fractures are acknowledged clinically and that many are merely found incidentally on routine imaging studies.⁴ Nevertheless, significant morbidity and mortality is associated with symptomatic patients with vertebral compression fractures presenting with low back pain, with reports of survival rates by Kaplan-Meier method of 53.9%, 30.9% and 10.5% at 3, 5, and 7 years, respectively.⁵ Hence, from 2001 to 2006, vertebroplasty procedures doubled in number performed, from 4.3 to 8.9 procedures per 1000 persons⁶ in the US. Patient outcomes following vertebroplasty or kyphoplasty for osteoporotic compression fractures have been reported in numerous studies. Recent prospective, randomized, placebo controlled studies revealed no difference between vertebroplasty and a sham operation.^{7,8} Based on these studies, the American Academy of Orthopaedic Surgery published evidence-based, clinical-practice guidelines recommending “against vertebroplasty for patients who present with an osteoporotic spinal compression fracture.”⁹ Nevertheless, vertebral filling operations for

the treatment of insufficiency vertebral compression fractures remain widely used, mostly with excellent results in terms of pain, function and complications as supported by a recent by meta-analysis of six randomized-controlled trials.¹⁰

The purpose of this study is to further understand the demographics and outcomes of kyphoplasty in improving pain in insufficiency fractures that are not responsive to conservative treatment, identify risk factors for recurrence of back pain due to new fractures or not, discern and understand the timing for symptom improvement after the procedure, and correlate the amount of vertebral height correction with clinical improvement. We hypothesized that kyphoplasty would be effective in pain management for these patients.

Materials and methods

All patients in this study (n=81) were referred to the surgeon’s clinic. Visual analog scale (VAS) questionnaires (painscale from 1-10) were given preoperatively and postoperatively in the clinic at subsequent visits up to a year. Patients were consented to the procedure only after understanding the risks and benefits to the procedure. All procedures were performed in the hospital operating room. Patients were placed in the prone position. With intra-operative bi-planar fluoroscopy (Figure 1), the procedure was performed as described in the technique guide. All kyphoplasties were performing using Kyphon Balloon Kyphoplasty (Medtronic, Memphis, TN). Patients were sent home the same day if no complications occurred. Postoperatively, patients were not braced and had no physical restrictions. Patients were seen in clinic after the procedure at least twice within the first year. Spine anterior-posterior and lateral radiographs of the appropriate level(s)

were obtained preoperatively and at each clinic visit. One year after the end of data collection period, patients were called to obtain short-form health survey (SF-36) scores. The questionnaires were performed over the phone and with either the patient or a family member's assistance, all questions were completed. All data were collected only after Institutional Review Board approval was obtained from our institution. Demographics, clinical and radiographic outcomes, and risk factors for new fractures and other complications were analyzed. Data analysis was performed using SPSS (Chicago, IL) utilizing student's t-tests.

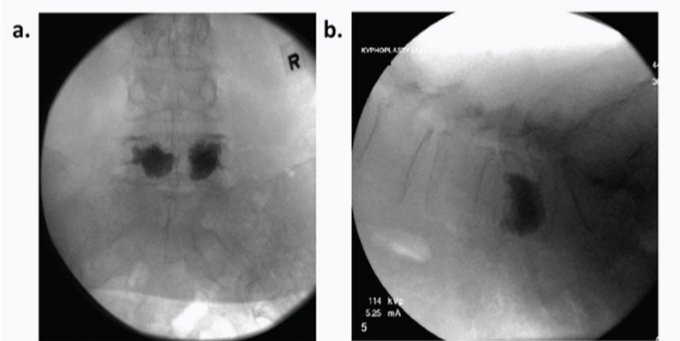


Figure 1 AP (A) and lateral (B) intra-operative fluoroscopic images of L5 kyphoplasty. (Case performed by Fernando Techy, M.D. at Advocate Lutheran General Hospital, Park Ridge, IL).

Results

Demographics

Eighty-one patients underwent kyphoplasty during this period (Table 1).

Visual Analog Scores

Fifty-nine patients (73%) had documented follow-up with VAS or written notes about subjective improvement at two and four weeks postoperatively. Of these, recurrent back pain or new back pain was noted in 16/59 (27%) at one-year follow up. Gender was a statistically significant difference: those with recurrence were 100% female (p=0.044). Otherwise, age, number of levels, location of level did not show statistically significant correlation with recurrent back pain after kyphoplasty. Fifty-one (63%) patients had documented postoperative VAS scores, which composed the inclusion group for the following

data. Maximum VAS improvement was seen at 0-2 weeks in 90.2% (46/51) of the patients. Five patients had maximum improvement between 4 to 9 weeks. Gender was a statistically significant difference in time to maximum improvement. In 0-2 week maximum VAS group, 93.5% were female, and three of five (60%) were females in the 4-10 week VAS score group (p=0.0082). Gender as an independent risk factor was also investigated. Five out of the 51 (10%) patients were male, and they had statically worse VAS scores (3.0 versus 0.80), as compared to females (p=0.0095). Age, number of levels, and location of levels were not statistically significant with respect to postoperative VAS scores.

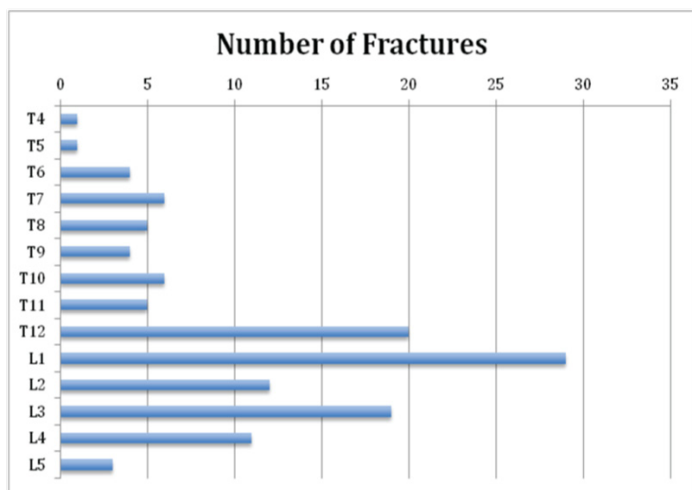
The patients' ages were also evaluated. Subsequent fractures were seen in 80% (4/5) of people older than 90 but only 23% in people younger than 80 (p=0.0172). Overall incidence of new fractures in one-year follow up was 24%. Patients under the age of 70 were more likely to have recurrent or new back pain, 60% vs 17.4% (p=0.0039). There were significant results identified through our data analysis. The location of the kyphoplasty was at higher levels in younger patients as compared to patients more than 80 years of age, which was statistically significant (p=0.004). Gender, most improved VAS score, and number of levels involved did not show statistically significant differences. The number of levels performed was also analyzed independently. With greater than one level fractured, additional compression fractures tended to involve lower levels (p=0.01). Statistical differences were not seen with respect to age, gender, recurrence, or subsequent fractures. However, there was a noticeable trend that was almost significant (p=0.055) showing that single-level fractures had an increased risk of recurrent or new back pain as compared to multilevel compression fractures (25% versus 16%). There was no statistical significant correlation found with age, gender, number of levels with the vertebral level of kyphoplasty. With respect to fracture level: Lumbar (L2-L5) levels were associated with a higher rate of multi-level compression fractures (p=0.00013). Otherwise, compression fracture location was not statistically associated with age, gender, recurrence, subsequent fracture (Table 2) (Figure 2). Radiographic analysis was also performed. Forty patients of the previous inclusion criteria had adequate postoperative radiographs for evaluation. Percent reduction compared to posterior height was measured on the anterior cortex and middle of the vertebral body. Radiographic reduction via kyphoplasty did not correlate with recurrent back pain, subsequent fracture, or maximally improved VAS. However, anterior cortex reduction improved with number of levels involved and lower levels. Middle vertebra reduction improved with younger age (p=0.033).

Table 1 Demographics

Age	#	%	Number of levels	#	%	Level	#	%
<70	10	12%	1	49	60.5%	Thoracic Level	33	20.0%
70s	28	35%	2	17	21.0%	T-L Level	49	29.7%
80s	38	47%	3	14	17.3%	Lumbar Level	83	50.3%
90s	5	6%	4	1	1.2%			
			Total	81				
Sex								
Male	13	16%						
Female	68	84%						

Table 2 Compression fracture location level

Number of Fractured Levels	Avg. High Level	Avg. Low Level
1 level	(T)11.8	(T)11.8
2 level	(T)11	(T)12.6
3 & 4 levels	(T)12	(L)5.8

**Figure 2** Vertebral compression fracture incidence by vertebral level.

Long-term follow-up SF-36 Scores

We were able to complete SF-36 questionnaires over the phone with 32 patients. Twenty-six of the 81 patients' contact numbers were disconnected or not working. The remaining 14 passed away since their procedure. We could not get contact information for eight patients. The mean physical health score was 63.1 (SD 17.9; R=18.4-94). The mean mental health score was 72.1 (SD 15.3, R=18-92.6). The overall mean SF-26 score was 70.7 (SD 16.6, R=17.75-94.75).

Complications

Recurrence/New back pain: Female gender was the only significant risk for recurrence or new back pain ($p=0.044$). Age and number of levels were not significant in affecting the recurrence rate. Risk of New Osteoporotic Fracture: Fractures postoperatively were seen in 15/51 (29%) patients (Table 3). No significant correlation was found between a new vertebral compression fracture with respect to age, gender or number of levels. Thirty-five percent (18/51) of our patients did have a new vertebral compression fractures in one-year follow up, 10 (55%) of which were adjacent to the kyphoplasty level(s).

Discussion

Kyphoplasty and vertebroplasty present minimally invasive treatment alternatives for pathological vertebral compression fractures that have failed nonoperative management. The actual prevalence of vertebral osteoporotic compression fractures is unknown because of the lack of standardization in how vertebral compression fractures are defined as well as the subsequent overall lack of diagnosis.³ Patient outcomes following vertebroplasty or kyphoplasty for osteoporotic compression fractures have been reported in numerous studies. With mid-term follow up results, our study supports the hypothesis that

kyphoplasty is an effective treatment for vertebral compression fractures in terms of pain and function.

Vertebroplasty for osteoporotic fractures

In a prospective, randomized, controlled study, Blasco et al.¹¹ revealed with 12 months of follow up, patients undergoing vertebroplasty for osteoporotic fractures had better VAS and quality of life outcomes than those undergoing medical nonoperative management. In another prospectively randomized study, comparing vertebroplasty to medical nonoperative management, Voormolen et al.¹² concluded that vertebroplasty led to significantly greater pain reduction, less pain medication use, and improved mobility and overall physical function one day and two weeks after treatment. Alvarez et al.¹³ performed a similar study in a prospective, non-randomized study, which demonstrated that vertebroplasty was associated with substantially greater pain reduction at three and six months post-procedure, when compared to medical treatment. When compared to optimal medical treatment, kyphoplasty was also associated with better functional scores and less pain medication use at three months. At one-year follow up, there was no difference between the two methods. In another prospective non-randomized study, Diamond et al.¹⁴ demonstrated that vertebroplasty was superior to medical management in reducing pain and improving physical activity on the first post-procedure day. However, there was no difference at 1.5, five or 12 months. In another one of his studies, Diamond et al.¹⁵ compared vertebroplasty to medical management, finding that although vertebroplasty led to better pain scores and functional outcomes at six weeks, there was no difference at one- or two-year follow up. Moreover, Diamond found that the incidence of adjacent vertebral fractures at two years was no different between the vertebroplasty and medical management groups.

In a meta-analysis of 30 studies consisting of 2086 patients, Hockmuth et al.¹⁶ found that kyphoplasty consistently produced rapid pain relief in each study. The complication rates in overall for these studies were 0.9% major morbidity, 0.1% cement embolism, and 0% mortality. In another meta-analysis of 69 studies with over 4000 patients, comparing vertebroplasty and kyphoplasty, Hulme et al.¹⁷ declared that both procedures are effective in relieving pain. The overall complication rates for vertebroplasty were 3.9% symptomatic complications, 6% neurologic sequelae, 6% pulmonary embolism; and the overall complication rates for kyphoplasty were 2% symptomatic complications, 0.03% neurologic sequelae, and 0.01% pulmonary embolism. Eck et al.¹⁸ substantiated Hockmuth and Hulme's findings with a larger meta-analysis of 136 studies with over 9500 patients, comparing clinical outcomes of vertebroplasty and kyphoplasty. Complication rates were similar as well with vertebroplasty having 1.6% symptomatic cement extravasation, 0.9% pulmonary embolism, 0.3% hematoma formation, and 0.1% infection; while kyphoplasty had 0.03% symptomatic cement extravasation, 0.04% pulmonary embolism, 0.03% infection. There are also multiple case series reports that described significant, immediate pain relief after vertebroplasty for osteoporotic, pathological vertebral compression fractures.¹⁹⁻²⁶

Vertebral filling procedures for compression fractures associated with tumors

In a randomized, controlled study, Berenson et al.²⁷ compared kyphoplasty to nonoperative treatment of vertebral compression fractures from metastatic disease, finding that patients undergoing kyphoplasty had greater relief of pain, higher quality of life scores,

and better overall function. McGirt et al.¹⁹ conducted a meta-analysis of 35 kyphoplasty studies and 74 vertebroplasty studies, finding that these vertebral filling procedures for pathological compression fractures are superior to medical treatment with minimal complications. In the same systematic review, McGirt examined 18 case series of management of pathological vertebral compression fractures secondary to malignancy. With this review, he asserted that both kyphoplasty and vertebroplasty are effective in reducing pain with minimal complications. Weil found that 94% of patients in a series of 37 tumor-associated vertebral compression fractures had significant pain improvement, while 8.1% had transient radiculopathy from cement leakage. Cortet et al.²⁰ described cement extravasation in 72.5% of cases, 6.9% of which required re-operation. Several other studies on tumor-associated vertebral compression fractures treated with kyphoplasty and vertebroplasty found that asymptomatic cement extravasation from 4% to 26%.^{21–24,28}

Prospective randomized placebo controlled studies

Using the Australian New Zealand Clinical Trials Registry, Buchbinder et al.⁷ compared the following outcomes between vertebroplasty and sham procedure: pain, quality of life, and functional status. Sham procedure entailed injection of a short-acting anesthetic in the vertebral periosteum. At one week, one month, three months, and six months, there was no difference between the two groups; both groups reported significant improvement in pain. Kallmes et al. also found that there was no difference between vertebroplasty and sham procedure at one month.⁸

Kyphoplasty for osteoporotic fractures

In a prospective study comparing vertebroplasty with kyphoplasty for single-level osteoporotic compression fractures, Omidi-Kashani et al.²⁹ found significant improvement from baseline in both VAS and SF-36 scores in both treatment groups. However, in this study did not reveal any difference in pain and functional outcomes between the kyphoplasty and vertebroplasty groups. In a prospective, randomized controlled study with 24 months of follow up, Van Meirhaeghe et al.³⁰ found that patients who underwent kyphoplasty had earlier and better improvement in quality of life, function, mobility, and pain than those undergoing non-operative management. In another prospective, randomized, controlled study, Kasperk et al.²⁵ compared kyphoplasty with nonoperative medical management of osteoporotic fractures, finding that those who had kyphoplasty had better pain scores and earlier return to activity. Grafe et al.²⁵ later reported on the outcomes of these same patients at 12 months, finding that those who underwent kyphoplasty had better pain relief and fewer clinic visits and fewer complications including adjacent vertebral fractures. In our study, about 24% (12/51) of our patients with documented VAS had a new vertebral compression fracture, with three more patients sustaining fractures in their extremities as well. Roughly half of the new vertebral compression fractures occurred at a level adjacent to the kyphoplasty level. In addition to the aforementioned studies,^{26,31–35} there are many others demonstrating reliable and rapid relief of pain following kyphoplasty for osteoporotic vertebral compression fractures. Taylor et al.³⁶ performed a meta-analysis of 35 studies comprised of 1,946 patients, finding that kyphoplasty led to rapid and marked improvement in pain scores.

In our series, maximal improvement in the VAS was seen at two weeks in 90% of our patients, and at nine weeks 100% reached maximal improvement. About half of the vertebral compression fractures seen

in our patients were in the high lumbar region, which might seem unusual, but when fractures were seen in the lumbar region, there was a significantly increased incidence of multiple concurrent fractures, probably indicating the severity of osteoporosis in the individual. Furthermore, radiographic reduction via kyphoplasty did not correlate with recurrent back pain, subsequent fracture, or maximal improved VAS. Twenty-seven percent of patients had recurrent back pain in one year, and 24% had a recurrent vertebral fracture. For about half of our patients who had recurrent compression fractures, the level was adjacent to the previous fracture. We also identified the female gender as the only significant risk factor for subsequent new onset back pain. All patients in the study had some decrease in VAS scores. However, we did notice that women with compression fractures had significantly better VAS scores short- and long-term compared to men. Statistically significant higher final VAS scores were noted in lumbar fractures. Comparing our patients' SF-36 scores at long-term follow-up with other studies, our patients' scores are comparable to those with long-term follow-up. Our patients' average SF-36 score values are also very similar to age-matched controls seen in the literature.¹³ We can conclude that patients were able to return to a significant level of activity as a result of their treatment.

Our study has some limitations. As gender, pre-operative VAS, number of levels, surgeon's experience, fractures of thoraco-lumbar region (T12 and L1), and radiographic vertebral anterior/posterior height difference were not associated with any differences in the final VAS score, a statistical significance might be seen if this study were repeated with a larger sample. In spite of the statistically significant differences we did find, the clinical differences are few but should not be interpreted as the contraindication to performing a kyphoplasty. When we spoke to the patients during the collection of data for the SF-36 forms, many clearly stated that they felt significant improvement in pain relief very soon after the procedure, which consequently allowed them to perform some of their routine activities of daily living.

Conclusion

As we were only able to contact half of our patients, we should reiterate that vertebral compression fractures still carry a significant morbidity and mortality for our patients. Keeping them active and pain free is crucial in maintaining their health and longevity. As we had no direct mortalities or complications from this procedure, we conclude that kyphoplasty provides a safe and effective treatment for pain in patients with vertebral compression fractures.

References

1. Johnell O, Kanis JA. An estimate of the worldwide prevalence and disability associated with osteoporotic fractures. *Osteoporos Int.* 2006;17(12):1726–1733.
2. Carmona RH. Bone health and osteoporosis: a report of the Surgeon General. *Reports of the Surgeon General.* 2004.
3. Black DM, Cummings SR, Stone K, et al. A new approach to defining normal vertebral dimensions. *J Bone Miner Res.* 1991;6(8):883–892.
4. Svedbom A, Alvares L, Cooper C, et al. Balloon kyphoplasty compared to vertebroplasty and nonsurgical management in patients hospitalised with acute osteoporotic vertebral compression fracture: a UK cost-effectiveness analysis. *Osteoporos Int.* 2013;24(1):355–367.
5. Savage JW, Schroeder GD, Anderson PA. Vertebroplasty and Kyphoplasty for the Treatment of Osteoporotic Vertebral Compression Fractures. *J Am Acad Orthop Surg.* 2014;22(10):653–664.

6. Weinstein JN. Balancing science and informed choice in decisions about vertebroplasty. *N Engl J Med.* 2009;361(6):619–621.
7. Buchbinder R, Osborne RH, Ebeling PR, et al. A randomized trial of vertebroplasty for painful osteoporotic vertebral fractures. *N Engl J Med.* 2009;361(6):557–568.
8. Kallmes DF, Comstock BA, Heagerty PJ, et al. A randomized trial of vertebroplasty for osteoporotic spinal fractures. *N Engl J Med.* 2009;361(6):569–579.
9. Esses SI, McGuire R, Jenkins J, et al. The treatment of symptomatic osteoporotic spinal compression fractures. *J Am Acad Orthop Surg.* 2011;19(3):176–182.
10. Anderson PA, Froysheter AB, Tontz WL. Meta-analysis of vertebral augmentation compared with conservative treatment for osteoporotic spinal fractures. *J Bone Miner Res.* 2013;28(2):372–382.
11. Blasco J, Martinez-Ferrer A, Macho J, et al. Effect of vertebroplasty on pain relief, quality of life, and the incidence of new vertebral fractures: a 12-month randomized follow-up, controlled trial. *J Bone Miner Res.* 2012;27(5):1159–1166.
12. Voormolen MH, Mali WP, Lohle PN, et al. percutaneous vertebroplasty compared with optimal pain medication treatment: short-term clinical outcome of patients with subacute or chronic painful osteoporotic vertebral compression fractures. The VERTOS study. *AJNR Am J Neuroradiol.* 2007;28(3):555–560.
13. Alvarez L, Alcaraz M, Perez-Higueras A, et al. Percutaneous vertebroplasty: functional improvement in patients with osteoporotic compression fractures. *Spine (Phila Pa 1976).* 2006;31(10):1113–1118.
14. Diamond TH, Champion B, Clark WA. Management of acute osteoporotic vertebral fractures: a nonrandomized trial comparing percutaneous vertebroplasty with conservative therapy. *Am J Med.* 2003;114(4):257–265.
15. Diamond TH, Bryant C, Browne L, et al. Clinical outcomes after acute osteoporotic vertebral fractures: a 2-year non-randomised trial comparing percutaneous vertebroplasty with conservative therapy. *Med J Aust.* 2006;184(3):113–117.
16. Hochmuth K, Proschek D, Schwarz W, et al. Percutaneous vertebroplasty in the therapy of osteoporotic vertebral compression fractures: a critical review. *Eur Radiol.* 2006;16(5):998–1004.
17. Hulme PA, Krebs J, Ferguson SJ, et al. *Vertebroplasty and kyphoplasty: a systematic review of 69 clinical studies.* *Spine (Phila Pa 1976).* 2006;31(17):1983–2001.
18. Eck JC, Nachtigall D, Humphreys SC, et al. Comparison of vertebroplasty and balloon kyphoplasty for treatment of vertebral compression fractures: a meta-analysis of the literature. *Spine J.* 2008;8(3):488–497.
19. McGirt MJ, Parker SL, Wolinsky JP, et al. Vertebroplasty and kyphoplasty for the treatment of vertebral compression fractures: an evidenced-based review of the literature. *Spine J.* 2009;9(6):501–508.
20. Cortet B, Cotten A, Boutry N, et al. Percutaneous vertebroplasty in patients with osteolytic metastases or multiple myeloma. *Rev Rhum Engl Ed.* 1997;64(3):177–183.
21. Fourney DR, Schomer DF, Nader R, et al. Percutaneous vertebroplasty and kyphoplasty for painful vertebral body fractures in cancer patients. *J Neurosurg.* 2003;98(1 Suppl):21–30.
22. Lane JM, Hong R, Koob J, et al. Kyphoplasty enhances function and structural alignment in multiple myeloma. *Clin Orthop Relat Res.* 2004;426(426):49–53.
23. Dudeny S, Lieberman IH, Reinhardt MK, et al. Kyphoplasty in the treatment of osteolytic vertebral compression fractures as a result of multiple myeloma. *J Clin Oncol.* 2002;20(9):2382–2387.
24. Sun G, Cong Y, Xie Z, et al. Percutaneous vertebroplasty using instruments and drugs made in China for vertebral metastases. *Chin Med J (Engl).* 2003;116(8):1207–1212.
25. Kasperk C, Hillmeier J, Noldge G, et al. Treatment of painful vertebral fractures by kyphoplasty in patients with primary osteoporosis: a prospective nonrandomized controlled study. *J Bone Miner Res.* 2005;20(4):604–612.
26. Lieberman IH, Dudeny S, Reinhardt MK, et al. Initial outcome and efficacy of “kyphoplasty” in the treatment of painful osteoporotic vertebral compression fractures. *Spine (Phila Pa 1976).* 2001;26(14):1631–1638.
27. Berenson J, Pflugmacher R, Jarzem P, et al. Balloon kyphoplasty versus non-surgical fracture management for treatment of painful vertebral body compression fractures in patients with cancer: a multicentre, randomised controlled trial. *Lancet Oncol.* 2011;12(3):225–235.
28. Pflugmacher R, Schleicher P, Schroder RJ, et al. Maintained pain reduction in five patients with multiple myeloma 12 months after treatment of the involved cervical vertebrae with vertebroplasty. *Acta Radiol.* 2006;47(8):823–829.
29. Omidi-Kashani F, Samini F, Hasankhani EG, et al. Does percutaneous kyphoplasty have better functional outcome than vertebroplasty in single level osteoporotic compression fractures? A comparative prospective study. *J Osteoporos.* 2013;690329.
30. Van Meirhaeghe J, Bastian L, Boonen S, et al. A Randomized Trial of Balloon Kyphoplasty and Non-Surgical Management for Treating Acute Vertebral Compression Fractures: Vertebral Body Kyphosis Correction and Surgical Parameters. *Spine (Phila Pa 1976).* 2013.
31. Masala S, Cesaroni A, Sergiacomi G, et al. Percutaneous kyphoplasty: new treatment for painful vertebral body fractures. *In Vivo.* 2004;18(2):149–153.
32. Rhyne A, Banit D, Laxer E, et al. Kyphoplasty: report of eighty-two thoracolumbar osteoporotic vertebral fractures. *J Orthop Trauma.* 2004;18(5):294–299.
33. Shindle MK, Gardner MJ, Koob J, et al. Vertebral height restoration in osteoporotic compression fractures: kyphoplasty balloon tamp is superior to postural correction alone. *Osteoporos Int.* 2006;17(12):1815–1819.
34. Voggenreiter G. Balloon kyphoplasty is effective in deformity correction of osteoporotic vertebral compression fractures. *Spine (Phila Pa 1976).* 2005;30(24):2806–2812.
35. Wilhelm K, Stoffel M, Ringel F, et al. Preliminary experience with balloon kyphoplasty for the treatment of painful osteoporotic compression fractures. *Rofo.* 2003;175(12):1690–1696.
36. Taylor RS, Fritzell P, Taylor RJ. Balloon kyphoplasty in the management of vertebral compression fractures: an updated systematic review and meta-analysis. *Eur Spine J.* 2007;16(8):1085–1100.