

Multidisciplinary management of penile calciphylaxis in a patient undergoing hemodialysis

Abstract

Penile necrosis in end-stage chronic kidney disease patients on hemodialysis presents complex pathophysiology involving vascular, metabolic, and dialysis-related factors. This clinical case emphasizes the significance of prompt multidisciplinary management. Surgical interventions like penectomy with scrotal pedicled flaps offer effective reconstruction, preventing complications. Long-term success mandates diligent oversight of metabolic and vascular issues. A comprehensive approach integrating urology, vascular surgery, and nephrology specialists is essential for optimal patient outcomes and quality of life.

Keywords: Penile necrosis, hemodialysis, chronic kidney disease, calciphylaxis, gangrene, surgery

Volume 14 Issue 2 - 2024

Malki Mohamed Amine, Roger Kenza Ngeno, Yaagoubi Ahmed, Alami Rayan, Ahsaini Mustapha, Mellas Soufiane, Tazi Mohammed Fadl, El Ammari Jalal, El Fassi Jamal, Farih My Hassan

Department of Urology, Centre Hospitalier Universitaire Hassan II (CHU Fes), Morocco

Correspondence: Malki Mohamed Amine, Department of Urology, Centre Hospitalier Universitaire Hassan II (CHU Fes), Morocco, Email aminemalki14@gmail.com

Received: April 12, 2024 | **Published:** April 26, 2024

Introduction

Although rare, penile necrosis represents a serious complication requiring urgent management, especially among patients with end-stage chronic kidney disease (CKD) receiving hemodialysis. These incidents take on a particularly concerning dimension. The underlying pathophysiology in these cases remains complex, involving a combination of vascular, infectious, and metabolic factors. Through exploration of our clinical case, we will examine the clinical, etiological, and therapeutic aspects of penile necrosis occurring in patients with end-stage chronic kidney disease undergoing hemodialysis.

Case presentation

A 65-year-old male patient, known to have hypertension with end-stage renal disease undergoing hemodialysis twice weekly for 5 years, presented to the emergency department with loss of foreskin

of the penis and blackish discoloration of the glans penis for 5 months associated with necrosis of the extremities of the upper and lower limbs. It is noted that the patient had received treatment from charlatans (Figure 1–3). There was no history of discharge, bleeding or trauma preceding the complaints. The patient also had a history of difficulty urinating. On examination, there was an area of blackish discoloration at the tip of the penis measuring approximately 3 x 3cm, with exposure of the skin of the foreskin and a rupture of the corpus spongiosum. The area of gangrene was sensitive without local elevation of temperature. Examination of the abdomen, scrotum, testicles and perineum was normal. Routine blood tests showed Hb 7, eGFR 13, serum calcium 9.3 mg/dL and phosphorus 6 mg/dL. A multidisciplinary surgical management between urologist, vascular surgeon and nephrologist was proposed. We proposed a penectomy with coverage using crossed scrotal flaps (Figure 4) and vascular surgeons for regularization of toes and finger pulps. Histopathological examination revealed calcifications in the intima of arteries with thrombosis and microabscesses in the epidermis.

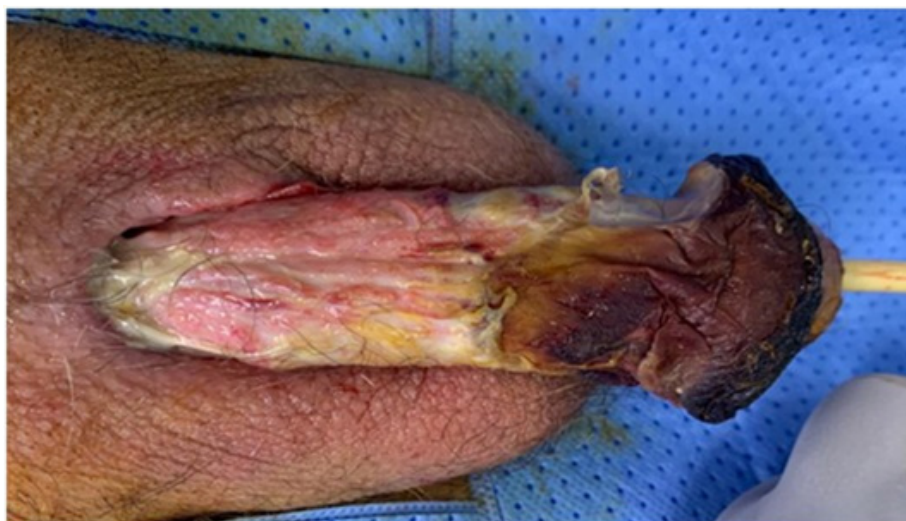

Figure 1 Dry necrosis of the cutaneous covering of the glans and the distal portion of the penis with loss of skin of the penile shaft in its proximal portion.

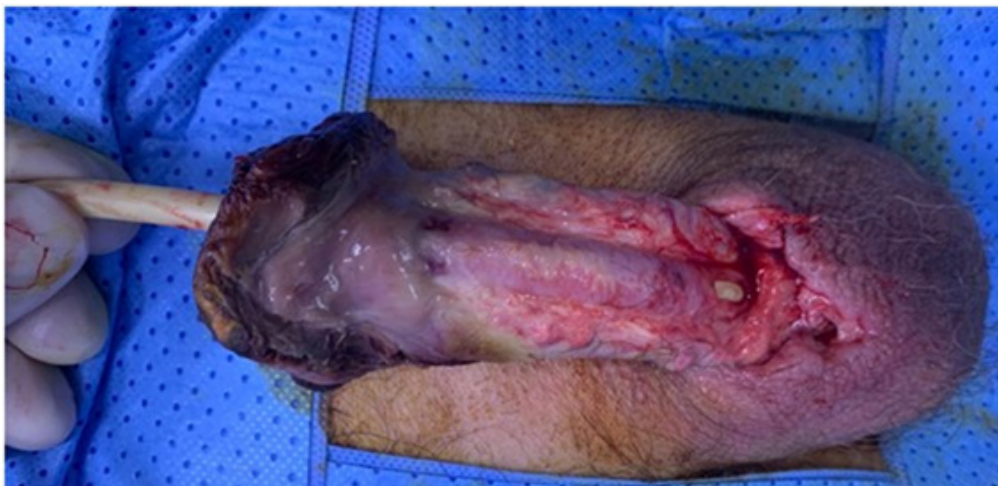

Figure 2 Loss of substance at the level of the spongy body.

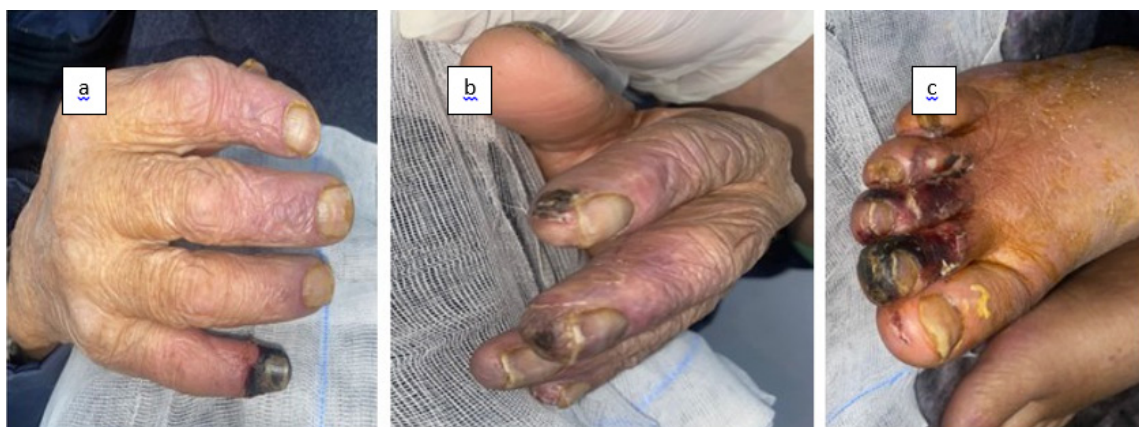

Figure 3a Dry necrosis of the pulp of the fifth finger.

3b Necrotic plaque on the second and third fingers.

3c Dry necrosis on the second, third, and fourth toes.

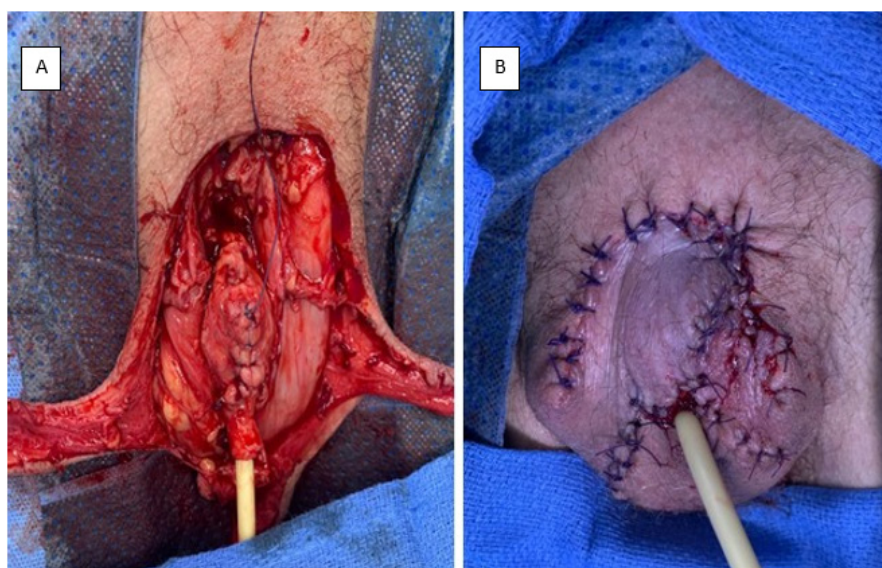


Figure 4A depicts a penectomy procedure with the liberation of scrotal flaps.

4B Illustrates the completion of the coverage step.

Discussion

The pathophysiological mechanisms underlying penile necrosis in patients undergoing hemodialysis are complex and multifactorial. First, patients with end-stage kidney disease have an increased risk of vascular disorders, including atherosclerosis, due to endothelial dysfunction and accumulation of pro-coagulant factors in the blood. This impairment of vascular function can compromise blood perfusion to penile tissues, thus facilitating the development of necrosis.¹ Second, the metabolic imbalances frequently observed in patients with kidney disease, such as hyperphosphatemia and hypercalcemia, can lead to calcification of blood vessels. This vascular calcification also impairs tissue perfusion, further increasing the risk of tissue necrosis in the male genital region.²

Additionally, dialysis itself can cause vascular and hemodynamic complications such as episodes of hypotension and hemodynamic fluctuations, which further compromise blood perfusion of penile tissues. These vascular and metabolic disturbances create a favorable environment for the occurrence of tissue necrosis in the male genital region.³ This clinical case poignantly illustrates the severe complications associated with end-stage kidney disease, particularly calciphylaxis of the glans that spread to the lower and upper extremities, suggesting that penile necrosis can be part of systemic calciphylaxis. A few cases of penile calciphylaxis have been described in the literature.⁴ The convergence of vascular, metabolic and infectious factors contributes to the occurrence of these devastating complications in hemodialysis patients. Self-medication by charlatans, as observed in this patient, can worsen the situation by delaying adequate medical management.

The management of these cases requires a multidisciplinary approach involving specialists from various fields such as urology, vascular surgery and nephrology. This collaboration provides comprehensive and tailored care for each patient, taking into account the different aspects of their pathology and comorbidities. Early surgical intervention, as proposed here with a penectomy and coverage with scrotal pedicled flaps, emerges as a promising alternative to free skin grafting for reconstruction of penile sheath defects. This

technique provides satisfactory functional, esthetic and psychological results, with an acceptable morbidity⁵ limiting the spread of gangrene and preventing more serious complications such as sepsis. However, once the acute phase is managed, particular attention must be paid to managing the underlying metabolic and vascular complications in order to optimize long-term outcomes in these high-risk patients.

Conclusion

This case highlights the importance of multidisciplinary management and early intervention in the treatment of penile necrosis in hemodialysis patients. A holistic approach, integrating both surgical treatment and comorbidity management, is essential to provide patients with the best chance of recovery and improved quality of life.

Acknowledgments

None.

Conflicts of interest

The author declares that there is no conflicts of interest for this article.

References

1. Zoccali C. Traditional and emerging cardiovascular and renal risk factors: an epidemiologic perspective. *Kidney Int.* 2006;70(1):26–33.
2. Palit S, Kendrick J. Vascular calcification in chronic kidney disease: the role of disordered mineral metabolism. *Curr Pharm Des.* 2014;20(37):5829–5835.
3. Maria EA, Charles JF, Ioannis B, et al. Hypertension in kidney transplant recipients. *World J Transplant.* 2022;12(8):211–222.
4. Boumaoui NE, Aghamir B, Jonon R, et al. Penile necrosis revealing calcific uremic arteriopathy or calciphylaxis. *Nephrology & Therapeutics.* 2018;14(5):386.
5. Mendel L, Morel N, Paparel P, et al. Penile plasty using pedicled scrotal flaps: an interesting alternative to free skin grafting. *Progress in Urology.* 2017;27(13):690–693.