

# Double magnets causing double perforations – a case report

## Abstract

Magnets are unusual gastrointestinal foreign bodies. Ingestion of multiple magnets may lead to serious complications including bowel perforation. We are presenting the case of an 11 year old girl who ingested 2 singing magnets. The patient presented with a history of pain abdomen and bilious vomiting and constipation of one day duration, 20 days after ingestion of the magnets. On examination there was distension of abdomen and severe tenderness all over the abdomen along with rigidity. Abdominal radiograph showed the presence of foreign bodies in the abdomen. In view of features of peritonitis the patient was taken up for an exploratory laparotomy. Intraoperatively two perforations were found, one in the jejunum and the other in the ileum. The perforations were caused due to the pressure necrosis caused by the presence of magnets in different loops of the bowel. The perforations were closed. Postoperative period was uneventful.

In conclusion, it is important to be aware of the problems that can be caused in cases of multiple magnet ingestion and to intervene at the earliest to prevent further complications.

**Keywords:** magnet ingestion, intestinal perforation, peritonitis, foreign bodies, exploratory laparotomy

Volume 10 Issue 6 - 2020

**Anusiri Inugala**

Niloufer Institute of Child Health, Hyderabad, India

**Correspondence:** Anusiri Inugala, Department of Pediatric Surgery, Niloufer Institute of Child Health, India.  
Email [anusirireddy@gmail.com](mailto:anusirireddy@gmail.com)

**Received:** October 12, 2020 | **Published:** November 06, 2020

## Introduction

Magnets are unusual gastrointestinal foreign bodies. The bullet shaped magnets are popular in children owing to the sound produced while a pair of these is tossed in air, thus the name, singing magnets or rattlesnake eggs. Ingested magnets are a serious health hazard for children as loops of bowel may be trapped between multiple magnets and undergo pressure necrosis leading to intestinal obstruction and perforation leading to peritonitis. We are reporting an unusual case where a child ingested multiple magnets and developed intestinal necrosis and perforation.

## Case report

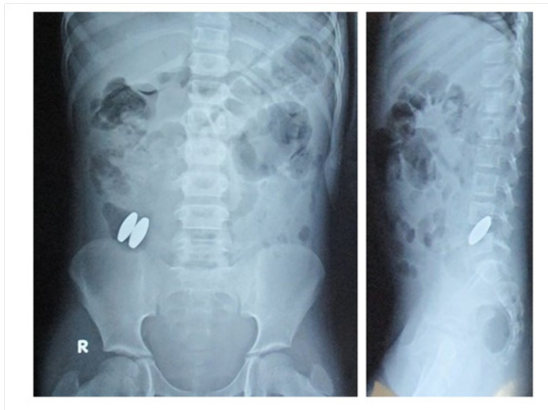
An 11 year old girl presented with a history of pain abdomen, bilious vomiting, abdominal distension and constipation of one day duration. There was a history of ingestion of 2 singing magnets 20 days back. On examination there was distension of abdomen and severe tenderness all over the abdomen along with rigidity. Abdominal radiograph showed the presence of foreign bodies in the abdomen (Figure 1). The patient was resuscitated and in view of features of peritonitis the patient was taken up for an exploratory laparotomy. Intraoperatively, bilious fluid was present in the peritoneal cavity. Multiple adhesions were present between the bowel loops. Two perforations were found in the bowel, one in the jejunum and the other in the ileum with the magnets present within the bowel near the perforations (Figures 2, 3). The perforations were caused due to the pressure necrosis caused by the presence of magnets in different loops of the bowel. The edges of perforations were freshened and perforations were closed. Peritoneal lavage was done and an abdominal drain was placed. Postoperatively the patient recovered well and the drain was removed on post operative day 5. On follow up after one month the patient was doing well.

## Discussion

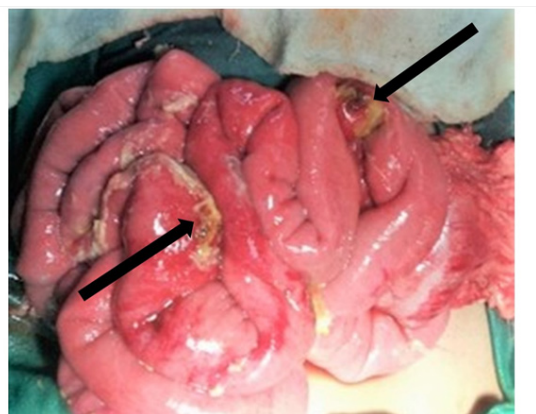Foreign body ingestion is a common clinical problem in paediatrics with 80% of cases involving children between the ages of 6 months

and 3 years.<sup>1</sup> Commonly ingested objects include coins, toy parts, jewellery, batteries, needles and pins, and fish and chicken bones.<sup>2</sup> In 80–90% of cases, spontaneous passage through the gastrointestinal tract occurs once the foreign body has entered the small bowel, so that surgical intervention is not usually necessary. Upper gastrointestinal foreign bodies are amenable to retrieval by endoscopy.<sup>3</sup> Singing magnets are made of ferromagnetic haematite. When thrown into air, they attract each other and make buzzing sounds, like a rattlesnake. That is why these magnets are also known as rattlesnake eggs. Multiple magnet ingestion is especially hazardous, because individual magnets tend to interact through the bowel wall. Magnets attract one another forcefully, and through pressure necrosis can cause serious bowel injury. Magnet ingestion is a rising problem in children and can cause a variety of problems including intestinal obstruction and perforation. Honzumi et al.,<sup>4</sup> reported a case of a 3 year old with a jejunoileal fistula after ingesting multiple magnets.<sup>4</sup> Younglim et al.,<sup>5</sup> reported a case of a 9 month old who ingested 5 magnets 3 of which passed spontaneously, however the other two lead to the formation of a jejunoileal fistula for which surgery was required.<sup>5</sup> There are multiple reported cases of bowel perforation due to multiple magnet ingestion.<sup>6–8</sup> In 2012, European and North American Societies of Pediatric Gastroenterology, Hepatology, and Nutrition (ESPGHAN and NASPGHAN) developed an algorithm for the management of single or multiple magnets ingestion. They recommend early surgical intervention when multiple magnets get beyond the stomach and there is no progression of magnets on serial radiographs to prevent serious complications especially in symptomatic cases.<sup>9</sup> The majority of swallowed magnetic objects are components of toys. Thus, some educational and preventative measures are required to minimize the likelihood of ingestion. Media has an important role to provide awareness about this issue. Parents should be informed about potential dangers of these kinds of toys and objects. Another important point is that parents and caregivers should not think that the ingested magnet, even if it is small, could pass spontaneously like other harmless objects and they should take the child to hospital promptly. Toys should have

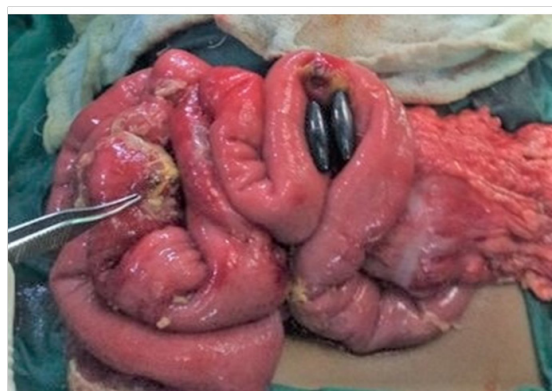warning labels on their packages and it should be emphasized that it can cause serious illness even life-threatening conditions if children swallow such hazardous magnets.<sup>10</sup> Finally, clinicians who care for children should be alert about magnet ingestion and when a patient presents with metallic foreign body ingestion, even if there is no symptom, they should suspect of magnet ingestion to be able to make early and rapid evaluation.



**Figure 1** Abdominal radiograph showing two magnets.



**Figure 2** Intraoperative picture showing the two perforations (marked by arrows).



**Figure 3** Intraoperative picture showing the two magnets.

## Conclusion

It is important to be aware of the problems that can be caused in cases of multiple magnet ingestion and to intervene at the earliest to prevent further morbidity. Concerns regarding magnet ingestion in young children have increased because of the current popularity of new generation high-powered magnets, and our case highlights the potential hazards and associated gastrointestinal complications of ingestion of such magnets in the young children.

## Acknowledgments

None.

## Funding

None.

## Conflicts of interest

The authors have no conflicts of interest to declare.

## References

1. Suk-Koo L, Nam-seon B, Hyun-Hahk K. Mischievous magnets: unexpected health hazard in children. *J Pediatr Surg*. 1996;31:1694–1695.
2. Hachimi-Idrissi S, Corne S, Vandenplas Y. Management of ingested foreign bodies in childhood: our experience and review of the literature. *Eur J Emerg Med*. 1998;5:319–323.
3. Laurance Hill J, Voigt RW. Foreign bodies. In: Ashcraft KW, editor. *Pediatric surgery*, 3rd edn. Philadelphia: WB Saunders Company. 2000:146–152.
4. Honzumi M, Shigemori C, Ito H, et al. An intestinal fistula in a 3-year old child caused by ingestion of magnets: report of a case. *Surg Today*. 1995;25(6):552–553.
5. Younglim Kim, Jeana Hong, Suk-Bae Moon, Ingestion of multiple magnets: The count does matter. *Journal of Pediatric Surgery Case Reports*. 2014; 2(3):130–132.
6. Lee SK, Beck N, Kim H. Mischievous magnets: unexpected health hazard in children. *J Pediatr Surg*. 1996;31(12):1694–1695.
7. Chung JH, Kim JS, Song YT. Small bowel complication caused by magnetic foreign body ingestion of children: two case reports. *J Pediatr Surg* 2003;38(10):1548–1550.
8. Tay ET, Weinberg G, Levin TL. Ingested magnets: the force within. *Pediatr Emerg Care*. 2004;20:466–467.
9. Hussain SZ, Bousvaros A, Gilger M, et al. Management of ingested magnets in children. *J Pediatr Gastroenterol Nutr*. 2012;55(3):239–242.
10. Hernández Anselmi E, Gutiérrez San Román C, Barrios Fontoba JE, et al. Intestinal perforation caused by magnetic toys. *J Pediatr Surg*. 2007;42(3):E13–E6.