

Minimally invasive thyroidectomy: A cosmetic alternative to standard thyroidectomy

Abstract

Background: We report on minimally invasive thyroidectomy (MIT) through a 2–4cm incision hypothesize similar clinical results to standard open thyroidectomy.

Methods: Between January 2019 and March 2020, 61 MIT were evaluated for clinical outcomes, and patient satisfaction on a 1–10 scale.

Results: The 61 study patients underwent MIT procedure. The final diagnoses were benign nodular goitre (63%), and papillary thyroid carcinoma (37%). Five patients had temporary recurrent laryngeal nerve paresis and four patients had temporary hypocalcemia.

Conclusion: In selected patients, MIT through a 1,5–3cm incision assistance is a safe alternative to standard open thyroidectomy in the hands of an experienced surgeon. The clinical results are equivalent and patient satisfaction is significantly improved.

Keywords: thyroidectomy, cricoid cartilages, maglinant lesions

Volume 10 Issue 3 - 2020

Tham X Ngo,¹ Khoi A Nguyen,² Long X Nguyen,¹ Vu DPVo¹

¹Department of Head and Neck Surgery, Hochiminh city Oncology Hospital, Vietnam

²Department of Oncology, University of Medicine Pham Ngoc Thach, Vietnam

Correspondence: Tham X Ngo, Hochiminh city Oncology Hospital, Head and Neck Surgery, Vietnam, Tel +84972436069, Email ngoxtham@gmail.com

Received: May 12, 2020 | **Published:** May 29, 2020

Background

The traditional Kocher operation is characterized by a 10–12cm long skin incision which results in a visible large scar in the neck. In recent years, since the first reported case of endoscopic parathyroidectomy by M. Gagner in 1996, several minimally invasive techniques for thyroidectomy have been developed with the core aim of reducing the incision length to bring the highest cosmetic outcome for patients and young women in particular. These attempts have made outstanding progress in thyroid surgery.

Minimally Invasive Thyroidectomy (MIT) includes 3 methods: completely endoscopic thyroidectomy with CO₂ insufflation, minimally invasive video-assisted thyroidectomy (MIVAT) without gas insufflation, and minimally invasive non-endoscopic thyroidectomy (MINET).

In our study, we applied the minimally invasive video-assisted thyroidectomy without gas insufflation, and minimally invasive non-endoscopic thyroidectomy. The main advantage of these two techniques appears to be the smaller incision which is about 1,5 to 3cm in the neck compared to the traditional Kocher incision.¹⁻⁴

Materials and methods

Study protocol

Between January 2019 and Mach 2020, MIT was applied for 61 patients of department of 5th surgery of Hochiminh city Oncology hospital for clinical outcomes within 3 months.

Indications

- Benign goiter nodule ≤4.5cm
- Thyroid volume <100ml as estimated by ultrasound
- Well-differentiated maglinant lesions ≤2cm, without level VI lymph nodes
- Non-thyroiditis and non-hyperthyroidism

Contraindications

- Benign goiter >4.5cm
- Poorly-differentiated maglinant lesions >2cm, with lymph nodes
- Thyroiditis /hyperthyroidism
- Obese patients
- Previous neck surgery

Methods

Interventional study without control group (Figure 1).

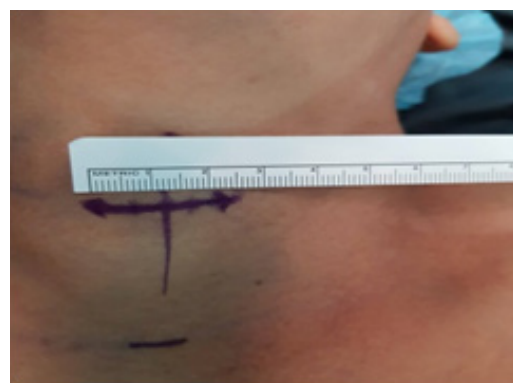

Figure 1 Incision length of MIT.

Surgical technique

As the traditional thyroidectomy technique, a soft roll is placed underneath the shoulders in order to have a slight extension of the neck.

MIT is to place the skin incision much higher than the Kocher incision. There are, in most people, one or two natural skin creases at

the level of thyroid and cricoid cartilages which is about 1cm with the aim to approach and monitor the superior pole's artery of the thyroid and the isthmus. The length of the incision is in the range of 1,5 and 3cm.

Using skin hooks, the superior and inferior subplatysmal flaps are developed using electrocautery and blunt dissection with the finger, the back of the toothed pick up or the pressure of a peanut. The midline connection of the sternohyoid muscles is divided by electrocautery then the sternothyroid muscle covering each thyroid lobe is separated and fully exposed with the support of two retractors farabeuf.

Mobilize of the superior pole. Another Kocher clamp is positioned on the superior pole of the thyroid lobe applying anterior and lateral traction. Blunt dissection with a "peanut" further sweeps the fibers of the sternothyroid muscle in order to clearly visualize the superior pole vessels. Usually, the Kocher clamp is repositioned further upward for better traction and exposure of the vessels and preserve parathyroid gland

Mobilize the inferior pole and preserve the inferior parathyroid gland. After that, the lobe that had been freed from its attachments to make it easy for finding out the recurrent laryngeal nerve (RLN). Searching and protecting the RLN which comes close to the thyroid and the ligament of Berry before entering the larynx.

The similar technique is applied to the remaining thyroid lobe in total or subtotal thyroidectomy. About the minimally invasive thyroidectomy video assisted, the procedure is the same; however, the incision length is smaller. Hence, the 4 mm 30° endoscope is used to get a more accurate vision of the posterial vessels then preserve the parathyroid gland as well as posterial laryngeal nerve. Patient satisfaction on cosmetic outcome of surgery scars is evaluated with the scale from 1 to 10. (Figure 2-9)(Table 1-2)

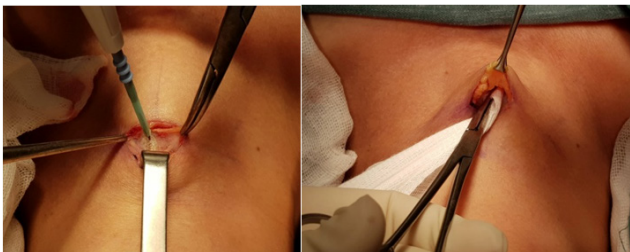


Figure 2 Extension of subplatysmal flap and midline.

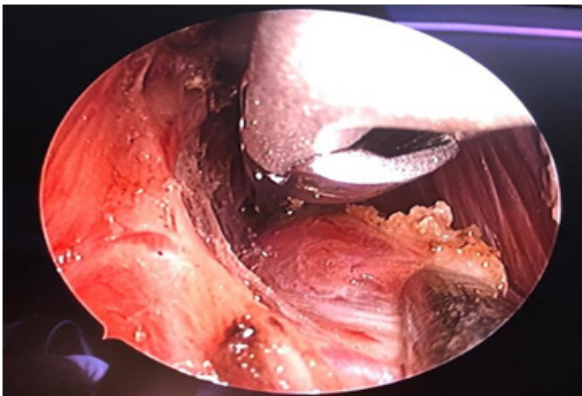


Figure 3 Mobilization of superior pole with video assisted.

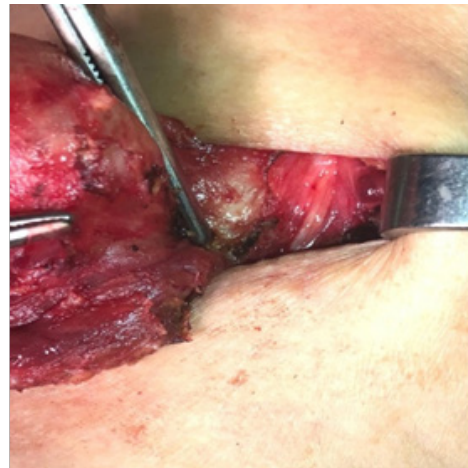

Figure 4 Recurrent laryngeal nerve.

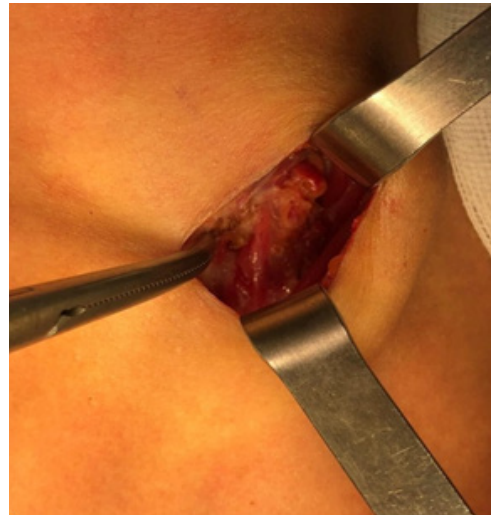

Figure 5 Superior parathyroid and recurrent laryngeal nerve.

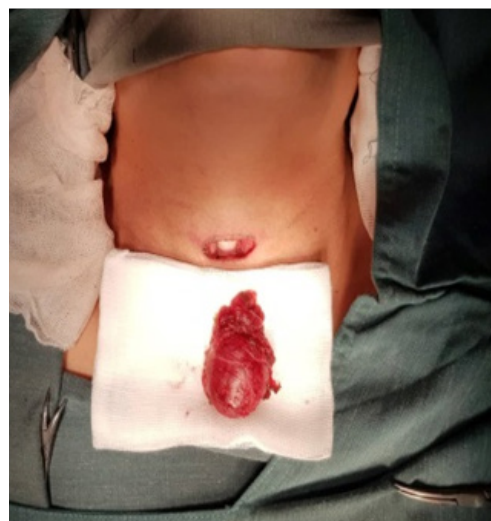

Figure 6 Postoperative thyroid lobe.

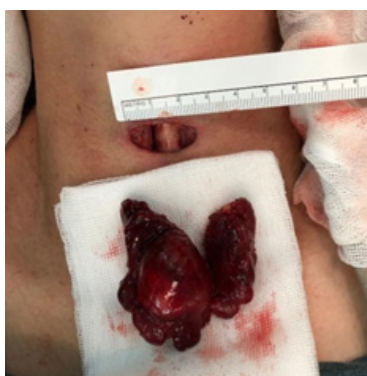

Figure 7 Postoperative total thyroid.

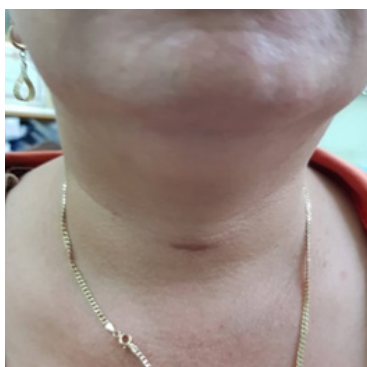


Figure 8 Neck scar after 01 month.

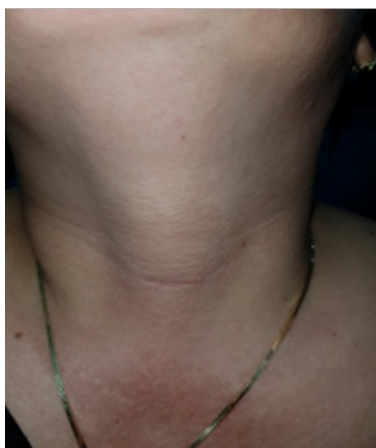

Figure 9 Neck scar after 03 months.

Table 1 Size of nodules

Size of nodules	Ratio
<1cm	17 (27.9%)
1-3.5cm	30 (49.2%)
>3.5cm	14 (22.9%)

Table 2 Procedures of executed operation

	Non endoscopic	Endoscopic	Total
Lobectomy	37	7	44 (76.7%)
Total or subtotal thyroidectomy	15	2	17 (23.3%)
Total	52	9	61 (100%)

Results

On 61 cases, the youngest was 13 years old and the oldest was 63. The mean age was 33,5. The female ratio was 97% whilst there were only 2 male patients. The benign cases took 67% and malignant tumor 33% all of which were papillary thyroid carcinoma. An investigation on adverse events was run and followed after 1 and 3 months. The results are as follows:

Transitory nerve palsy 8.2% (05 cases); transitory hypoparathyroidism 6,5%(4 cases). Most cases showed recovery after 1 month and none of them were recorded to have definitive hypoparathyroidism and definitive nerve palsy after operations 3 months. No recognition on any postoperative bleeding and wound infection was noted.

The surgical time was from 25 to 90 minutes, the mean time was 46,7 minutes. The hospital stay was 1-2 days, the mean hospital stay was 1.54 days. We have only 7/61 patients who were recorded with in severe keloid scars (11.4%). On the cosmetic outcome assessment, most of these 61 cases were in the range of 8 and 10, two of which were noted to be 8. The mean was $9,1 \pm 1,2$ points.⁵⁻⁸

Discussion

The mean surgical time “skin to skin” was 46, 7 minutes, which was similar to the one of the author De Napoli et al. 49.3+/-12 minutes and Del Rio et al. 48+/-4 minutes whilst faster than K Sapalidis et al (71.23+/-23.81 minutes) and Godvenic (135.4+/-51.1).

The most common adverse event is transitory hypoparathyroidism after operation with 4 cases (6,5%) and transitory nerve palsy (8.2%). None of them underwent post operative bleeding and wound infection. Our result on transitory hypoparathyroidism was lower than the one of the reports of the authors Delrio (24.9%), K. Sapalidis (10.4%), Govednik (9.7%). Relating to the transitory nerve palsy, our result seemed to be higher than the one of the authors Delrio (2.4%), K. Sapalidis (2.4%), Govednik (1.1%). However, after 3 months, the percentage of definitive nerve palsy and definitive hypoparathyroidism was 0,0%, which was the same with the one of the aforementioned authors including Delrio (0.8%), K. Sapalidis (0.0%), Govednik (0.0%).

The mean hospital stay was 1.54 days. This result was similar to the result of the authors K. Sapalidis (1.14 days), Delrio (1.3 days).

Patient satisfaction on the post operative cosmetic outcome was pretty high. Our study achieves 9,1/10 whilst the one of Govednik reached 9,56/10.

Conclusion

Minimally invasive thyroidectomy (MIT) included the video assisted and non video assisted is a safe technique and becomes more popular all over the world. It could be applied to all sorts of normal thyroid goiter and reduces the large incision on patients' neck, especially female as well as bringing the more effective cosmetic outcome.

Conflicts of interest

The authors have no conflicts of interest to declare.

Funding

None.

Acknowledgments

None.

References

1. Cara M, Govednik MD, Samuel K, et al. Minimally invasive-nonendoscopic thyroidectomy: A cosmetic alternative to robotic-assisted thyroidectomy. *Surgery*. 2014;156(4):1030–1037.
2. Miccoli P, Berti P, Conte M, et al. Minimally invasive surgery for thyroid small nodules. *Endocrinol Invest*. 1999;22(11):849–851.
3. Bertil Hamberger, Dimitrios Linos, Woong Youn Chung. Minimally Invasive Non-Endoscopic Thyroidectomy: The MINET Approach. Verlag Berlin Heidelberg. Minimally invasive thyroidectomy. *Springer*. 2012;133–140.
4. Mehmet Zafer Sabuncuoglu, Aylin Sabuncuoglu, Isa Sozen, et al. Minimally invasive surgery using mini anterior incision for thyroid diseases: a prospective cohort study. *Int J Clin Exp Med*. 2014;7(10):3404–3409.
5. Miccoli P, Minuto MN, Ugolini C, et al. Minimally invasive video assisted thyroidectomy for benign thyroid disease: an evidence-based review. *World J Surg, Review*. 2008;32(7):1333–1340.
6. K Sapalidis, KS Mylonas, E Kotidis, et al. Minimally Invasive Video-Assisted total Thyroidectomy (mi V.A.T.T)– case series of 48 patients. *Curr Health Sci J*. 2016;42(1):40–46.
7. David J, Terris, MD, Peter Angelos, et al. Minimally Invasive Video-Assisted Thyroidectomy Thyroidectomy A Multi-institutional North American Experience. *Arch Otolaryngol Head Neck Surg*. 2008;134(1):81–84.
8. Bertil Hamberger, Dimitrios Linos, Woong Youn Chung. Minimally Invasive Video-Assisted Thyroidectomy. Bertil Hamberger. Minimally invasive thyroidectomy. *Springer*. 2012;127–131.