

Silent colonic perforation complicating a ventriculoperitoneal shunt with trans-anal protrusion

Abstract

Ventriculoperitoneal shunt (VPS) is the most common treatment for hydrocephalus, but it can have many complications. Migration of the distal catheter within the bowel is a rare complication, but it can result in a potentially serious infectious complication, sepsis, or even death. In this study, we report a case of a young child with a peritoneal shunt catheter migrating into the colon and protruding through the anus.

Keywords: anal protrusion, hydrocephalus, ventriculoperitoneal shunt

Volume 9 Issue 5 - 2019

Mostafa Zain,¹ Amir Ibrahim,¹ Ahmed Mohamed Khalil,² Mostafa Kotb,¹ Ahmed Khairi¹

¹Department of Pediatric Surgery, Alexandria Faculty of Medicine, Egypt

²Department of Neurosurgery, Alexandria Faculty of Medicine, Egypt

Correspondence: Mostafa Zain, Department of Pediatric Surgery, Alexandria Faculty of Medicine, Egypt, Tel +201021236588, Email zaingom3a2010@yahoo.com

Received: September 14, 2019 | **Published:** October 07, 2019

Introduction

Ventriculoperitoneal (VP) shunt surgery is the treatment of choice for hydrocephalus with approved efficacy. Nonetheless, in 10-30% of patients, abdominal complications may develop. These complications include peritoneal pseudocyst, migration of the catheter to various organs including intestine, vagina, scrotum, umbilicus, and urinary bladder, in addition to volvulus, ascitis, inguinal hernia and intestinal obstruction.¹

Spontaneous bowel perforation is a rare complication of VP shunt, where it can occur anytime, ranging from few weeks to several years after the insertion of the device in 0.01% to 1% of patients.² It can present with a wide range of manifestations starting from being asymptomatic in up to 50% of the cases, to the extent of developing serious infectious complications, sepsis or even death.³ In this study, we report a case of a 2-year-old girl with a VP shunt catheter migrating into the colon and protruding through the anus 1 year after its placement.

Case Report

A 2-year-old girl, who had a VP shunt inserted for treating idiopathic hydrocephalus at the age of 11 months, presented to our hospital with her mother complaining of tube-like structure protruding through the anus of her child accompanied with persistent vomiting and fever. On general examination, she was mildly feverish with mild dehydration. Neck stiffness was noted and accompanied with brisk tendon reflexes; however, no neurological deficit was present. Otherwise, the abdominal examination was normal.

On digital rectal examination, the catheter could not be felt. Investigations revealed marked polymorphonuclear leucocytosis and sterile blood culture. Cerebrospinal fluid analysis and cultures showed exudative ventriculitis due to *E.coli* predominance along with other coliform organisms.

Abdominal X-ray and ultrasound (US) examinations confirmed the absence of peritonitis or pneumoperitoneum. However, CT abdomen revealed a hyper dense catheter projecting inside the descending colon. There was no free fluid in the peritoneal cavity (Figure 1). The patient was commenced on intravenous antibiotics and subsequently, the ventricular catheter was retrieved via an incision over the scalp. By pulling the protruding end through the anus, the distal catheter was then removed. The patient was kept under close observation for any sign of peritonitis or perforation for 5 days. Afterwards, she started oral feeding gradually and was discharged on the 6th day. No further problems were noted during regular follow-ups at the outpatient clinic.

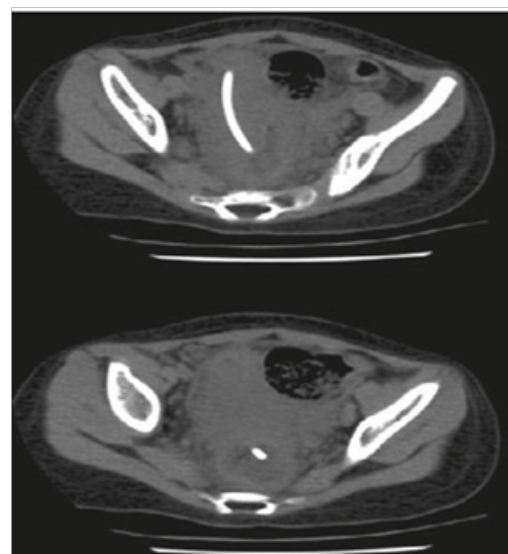


Figure 1 Coronal sections of abdominal computed tomography showing distal catheter penetrating into the rectum.

Discussion

Spontaneous bowel perforation is a rare complication of VP shunt surgery, where it occurs only in 0.01% to 0.07% of shunted patients and mostly encountered in children.⁴ Any segment of the GI tract can be involved, but the most commonly reported site is the colon. Other organs reported include small intestine, stomach, urinary bladder, fallopian tubes and liver and even to the external and internal jugular veins.⁵ In the majority of the cases the patient was either asymptomatic or presented with a catheter protruding per-anus or per-oral. To our best knowledge, a total of 113 cases, including our case, reported anal protrusion of VP shunt with 58 cases ranging from 0-10 years.^{2,6} Nevertheless, 47.4% present with the manifestations of acute abdomen, for instance, diarrhea, abdominal pain and tenderness.⁷ Patients may reveal symptoms and signs of raised intracranial pressure, meningitis, ventriculitis and cerebral abscess as well.⁸ Regrettably, the overall mortality rate is relatively high, where it can reach up to 15-18%, and it is further increased further more if infection is present. Mortality is about 22% and 33% with central nervous system and intra-abdominal infections, respectively.⁹

Though several mechanisms have been proposed, the etiology of the bowel perforation after VP shunt surgery is not fully understood. Local inflammatory reaction or fibrosis surrounding the distal catheter is believed to have an anchoring effect on the tube resulting in pressure on an area of the bowel, and subsequently causes perforation of the wall.¹⁰ The length of the intra-abdominal part as well as the type of the catheter may also be implicated in the bowel perforation and lastly, a foreign body-like reaction as a result of silicon allergy.¹¹

Whenever the catheter protrudes through the anus or mouth, the diagnosis of bowel perforation is considered straight forward. Plain X-ray and CT scan of the abdomen are among the diagnostic modalities of choice. The former may reveal pneumoperitoneum, while the latter may show thickened bowel wall or mucosa and peritoneal collections.¹² Other investigations suggestive of bowel perforation induced by VP shunt include ventriculomegaly, air in the ventricles and intracranial suppuration on CT brain scan.¹² Should a CSF culture from shunt tapping or lumbar puncture is positive for intestinal flora such as *E. coli*, *Klebsiella* and anaerobes bacteria, then bowel perforation is strongly suspected.¹³

The treatment of a VP shunt complicated by bowel perforation is a neurosurgical emergency.⁷ The principles of management include VP shunt removal, intravenous antibiotics administration and external ventriculostomy till a biochemically and microbiologically normal CSF is yielded.⁵ Depending on the general condition of the patient, the method of VP shunt removal is advocated.¹⁴ In cases presenting per-anus, like our case, the catheter can be pulled out through the anus without further surgical intervention as the perforation site usually becomes sealed off due to the development of a chronic fibrous sheath surrounding the shunt track.¹⁵ Other reported methods include percutaneous removal in absence of peritonitis,¹² and in cases with retracted catheter, colonoscopy can be used to retrieve the distal catheter.¹¹ Some patients, including ours, become shunt independent; therefore, do not require further shunting after the resolution of infection. However, a new shunt should be inserted in patients who are shunt dependent.¹⁶ Laparotomy must be performed if intra-abdominal infection was confirmed or in case of persistent fistulous tract that does not close spontaneously after endoscopic or percutaneous removal.¹⁷

In our patient, the diagnosis of the bowel perforation after VP shunt was easy as the distal part of the VP shunt catheter projected

through the anus. Clinical examination, laboratory investigations and imaging confirmed that the absence of abdominal or intracranial infection, and the prompt administration of antibiotic treatment along with the surgical removal of the catheter both resulted in the favourable outcome.

To sum up, any patient with VP shunt who presents with meningitis or ventriculitis due to bowel flora should be evaluated for bowel perforation. Together with antibiotics, shunt removal should be done and individualized according to the patient's current clinical condition.

Acknowledgments

None.

Funding

None.

Conflict of interest

There is no conflict of interest.

References

1. Park CK, Wang KC, Seo JK, et al. Transanal protrusion of peritoneal catheter: a case report and literature review. *Child Nerv Syst.* 2000;16(3):184-189.
2. Liu Y, Li C, Tian Y. Ventriculo-peritoneal shunt trans-anal protrusion causing Escherichia coli ventriculitis in child: Case report and review of the literature. *Chin Neuro surg J.* 2017;3:9.
3. Sathyanarayana S, Wylene EL, Baskaya MK, et al. Spontaneous bowel perforation after ventriculoperitoneal shunt surgery: case report and a review of 45 cases. *Surg Neurol.* 2000;54(5):388-396.
4. Ferreira PR, Bizzi JJ, Amantea SL. Protrusion of ventriculoperitoneal shunt catheter through the anal orifice. A rare abdominal complication. *J Pediatr Surg.* 2005;40(9):1509-1510.
5. Li HN, Tan TC, Cheung FC. Transanal protrusion of ventriculoperitoneal shunt. *Surgical Pract.* 2008;12:93-96.
6. Hai A, Rab AZ, Ghani I, et al. Perforation into gut by ventriculoperitoneal shunts: A report of two cases and review of the literature. *J Indian Assoc Pediatr Surg.* 2011;16(1):31-33.
7. Vinchon M, Baroncini M, Laurent T, et al. Bowel perforation caused by peritoneal shunt catheters: diagnosis and treatment. *Oper Neurosurg.* 2006;58:76-82.
8. Panagea S, Cartmill TD, Panigrahi H. Intracerebral sepsis due to intestinal perforation by ventriculo-peritoneal shunts: two cases. *J Infect.* 1997;35(1):86-88.
9. Yousfi MM, Jackson NS, Abbas M, et al. Bowel perforation complicating ventriculoperitoneal shunt: case report and review. *Gastrointest Endosc.* 2003;58(1):144-148.
10. Bodeliwala S, Agrawal A, Mittal A, et al. Transanal protrusion of ventriculoperitoneal shunt via appendicular perforation: A rare case report. *J Pediatr Neurosci.* 2016;11(3):274-276.
11. Brownlee JD, Brodkey JS, Schaefer IK. Colonic perforation by ventriculoperitoneal shunt tubing: a case of suspected silicone allergy. *Surg Neurol.* 1998;49(1):21-24.
12. Digray NC, Thappa DR, Arora M, et al. Silent bowel perforation and transanal prolapse of a ventriculoperitoneal shunt. *Pediatr Surg Int.* 2000;16(1-2):94-95.
13. Brook I. Meningitis and shunt infection caused by anaerobic bacteria in children. *Pediatr. Neurol.* 2002;26(2):99-105.

14. Ghritlaharey RK, Budhwani KS, Shrivastava DK, et al. Trans-anal protrusion of ventriculo-peritoneal shunt catheter with silent bowel perforation: report of ten cases in children. *Pediatr Surg Int.* 2007;23(6):575–580.
15. Bales J, Morton RP, Airhart N, et al. Transanal presentation of a distal ventriculoperitoneal shunt catheter: Management of bowel perforation without laparotomy. *SurgNeurol Int.* 2016;7:S1150–S1153.
16. Ozturk H, Is M, Ozturk H, et al. Transanal protrusion of ventriculoperitoneal shunt catheter. *J Coll Physicians Surg Pak.* 2012;22(11):733–734.
17. Zhou F, Chen G, Zhang J. Bowel perforation secondary to ventriculoperitoneal shunt: case report and clinical analysis. *J Int Med Res.* 2007;35(6):926–929.