

# Dysphasia caused by cervical diffuse idiopathic skeletal hyperostosis, a case report

## Abstract

Diffuse idiopathic skeletal hyperostosis (DISH) is a systemic enthesopathy with involvement of ossification of anterior longitudinal ligament (OALL). Although DISH is usually associated with benign nature, cervical large OALL should be considered as a consideration in differential diagnosis of dysphasia. A 73-year-old-man presented with dysphasia and his radiographs showed massive OALL at C4/5. A filling defect was confirmed at the same level by video fluoroscopy. Followed by failure of conservative treatment, surgical treatment of symptomatic OALL due to DISH was performed. Satisfactory recovery of swallowing was obtained without radiographic recurrence of OALL one year after surgery.

**Keywords:** ossification of anterior longitudinal ligament, dysphasia, diffuse idiopathic skeletal hyperostosis

Volume 6 Issue 3 - 2017

Ken Ninomiya,<sup>1</sup> Ryoma Aoyama,<sup>1</sup> Satoshi Suzuki,<sup>1</sup> Hiraku Hotta,<sup>2</sup> Itsuo Watanabe,<sup>1</sup> Kensuke Ochi,<sup>1</sup> Sakiko Mizuno,<sup>1</sup> Masamichi Onizawa,<sup>1</sup> Yuki Yoshida,<sup>1</sup> Yusuke Sanjyou,<sup>3</sup> Takeshi Morii,<sup>4</sup> Tateru Shiraishi,<sup>1</sup> Ukei Anazawa<sup>1</sup>

<sup>1</sup>Orthopedics Department, Tokyo Dental College Ichikawa General Hospital, Japan

<sup>2</sup>Rehabilitation Department, Tokyo Dental College Ichikawa General Hospital, Japan

<sup>3</sup>Oral and Maxillofacial Surgery Department, Tokyo Dental College Ichikawa General Hospital, Japan

<sup>4</sup>Orthopedics Department, Kyorin University Hospital, Japan

**Correspondence:** Ken Ninomiya, Orthopedics Department, Tokyo Dental College Ichikawa General Hospital, Japan, Tel 81-47-322-0151, Fax 81-47-325-4456, Email [kenninomi@aol.com](mailto:kenninomi@aol.com)

**Received:** March 10, 2017 | **Published:** March 15, 2017

**Abbreviations:** OALL, ossification of anterior longitudinal ligament; DISH, diffuse idiopathic skeletal hyperostosis; CT, computed tomography; VF, video fluoroscopy; SCM, sternocleidomastoid muscle

## Introduction

Diffuse idiopathic skeletal hyperostosis (DISH) is a non-inflammatory enthesopathy of unknown etiology.<sup>1,2</sup> It occurs primarily in men and the prevalence increases with age.<sup>1</sup> DISH is defined as presence of ossification of anterior longitudinal ligament (OALL) at least four continuous vertebral bodies with spared disc space.<sup>3</sup> Dysphagia is a common complaint especially among elderly people with the extremely broad causes.<sup>4</sup> Frequency of dysphasia induced by DISH is relatively low,<sup>5-7</sup> but this disorder can be an important consideration in differential diagnosis of dysphasia. Herein, we describe one case of successful treatment for dysphasia caused by DISH. This case report includes review of literature on pathology and treatment for dysphasia associated with DISH.

## Case presentation

A 73-year-old-man complained dysphasia over the past four months. This patient had a past medical history of atrial fibrillation and ischemic colitis. He complained neck stiffness without any neurological symptoms. His x-ray and Computed Tomography (CT) of cervical spine demonstrated a presence of continuous OALL from C3-Th2 with partial disruption. Video fluoroscopy (VF) revealed filling defect at C4/5, which is a level of most massive prominent of OALL, impaired epiglottic inversion and retention of contrast agent in pyriform sinus, epiglottic vallecula, and esophageal orifice due to OALL. Because 3 months of initial conservative therapy, such as anti-inflammatory medication and swallowing therapy, was unsuccessful, surgical removal of OALL underwent under general anesthesia.

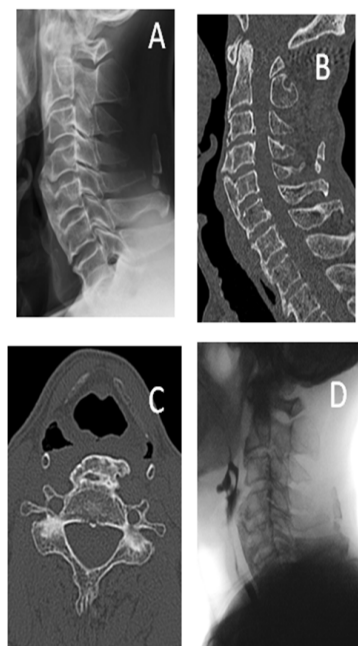
A transverse incision was designed parallel to anterior edge of the sternocleidomastoid muscle (SCM). The incision was carried through the platysma and the carotid vessels are located by palpation. By retracting the SCM and carotid sheath structures laterally and the esophagus and the trachea medially, the cervical bodies were exposed. OALL was identified following reflection of deep cervical fascia and the longus coli muscle. The area of OALL protrusion was reduced using osteotomes and rongeurs to approximate the native anterior vertebral surface. Sufficient removal of OALL between C3 to C6 was confirmed by postoperative x-ray. After irrigation by normal saline solution, a suction drain was placed in deep layer and the wound was closed in anatomic layers. The patient started to eat general food one day after surgery and was satisfied with improvement of swallowing. Recovery of swallowing function was also confirmed by VF seven days after the surgery. The swallowing function has been maintained postoperatively for one year and no recurrence of OALL was observed radiographically.

## Discussion

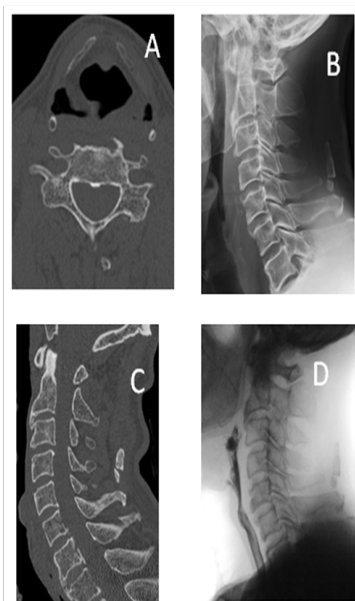
According to previous reports, severe dysphagia resulting from DISH seems to be a rare occurrence. Prevalence of DISH with the age of more than 40y/o is reported as 2.8% and only 0.1-6% of those will develop dysphagia.<sup>5-7</sup> The pathogenesis of dysphasia caused by OALL has been argued in many studies.<sup>8,9</sup> Mechanical obstruction, reaction in the surrounding tissues, or prevertebral edema are assumed as reason for dysphasia associated with DISH. The first treatment of patients with symptomatic OALL is conservative therapy, which includes anti-inflammatory medication, steroids, muscle relaxants, diet modification, and swallowing therapy.<sup>10,11</sup> However, recent review article presented that conservative treatment was effective only for 35 of 169 (20.7%) cases.<sup>12</sup> If conservative therapy is not effective, surgical treatment should be considered. Resection of symptomatic

OALL alone by the anterior approach is commonly performed, and many studies have revealed the satisfactory results followed by this surgical procedure.<sup>13,14</sup> However, some studies demonstrated that fusion surgery with resection of OALL is desirable for patients associated with segmental instability to prevent recurrence.<sup>15,16</sup>

In this case report, the patient was treated with osteophyctomy alone for impairment of swallowing caused by DISH because severe segmental instability was not confirming edradiologically. Though careful observation is still necessary, the patient presented satisfactory recovery of swallowing without recurrence one year after surgery (Figure 1) (Figure 2).



**Figure 1** (A) (B) (C) Preoperative X-ray and CT show prominent ossification of anterior longitudinal ligament at C4/5. (D) Preoperative video fluoroscopy (VF) demonstrates filling defect along the pharynx due to massive osteophyte.



**Figure 2** (A) (B) (C) Postoperative X-ray and CT show resection of ossification of anterior longitudinal ligament at from C4 to C6. (D) Postoperative VF reveals good passage of contrast agent in esophagus during swallowing.

## Acknowledgements

Yusuke Sanjyou (Tokyo Dental College Ichikawa General Hospital, Oral and maxillofacial surgery).

## Conflict of interest

The author declares no conflict of interest.

## References

1. Resnick D, Shaul SR, Robins JM. Diffuse idiopathic skeletal hyperostosis (DISH): Forestier's disease with extraspinous manifestations. *Radiology*. 1975;115(3):513–524.
2. Forestier J, Lagier R. Ankylosing hyperostosis of the spine. *Clinical Orthopaedics and Related Research*. 1971;74:65–83.
3. Oppenlander ME, Orringer DA, La Marca F, et al. Dysphagia due to anterior cervical hyperosteoehyotosis. *Surg Neurol*. 2009;72(3):266–270.
4. Madhavan A, LaGorio LA, Cray MA, et al. Prevalence of and risk factors for dysphagia in the community dwelling elderly: a systematic review. *J Nutr Health Aging*. 2016;20(8):806–815.
5. Rotes-Querol J. Clinical manifestations of diffuse idiopathic skeletal hyperostosis (DISH). *Br J Rheumatol*. 1996;35:1193–1194.
6. Kmucha ST, Cravens RB Jr. DISH syndrome and its role in dysphagia. *Otolaryngol Head Neck Surg*. 1994;110(4):431–436.
7. Aydin E, Akdogan V, Akkuzu B, et al. Six cases of Forestier syndrome, a rare cause of dysphagia. *Acta Otolaryngol*. 2006;126(7):775–778.
8. Girgis IH, Guirguis NN, Mourice M. Laryngeal and pharyngeal disorders in vertebral ankylosing hyperostosis. *J Laryngol Otol*. 1982;96(7):659–664.
9. Oga M, Mashima T, Iwakuma T, Sugioka Y. Dysphagia complications in ankylosing spinal hyperostosis and ossification of the posterior longitudinal ligament: roentgenographic findings of the developmental process of cervical osteophytes causing dysphagia. *Spine*. 1993;18(3):391–394.
10. Kristensen S, Sander KM, Pedersen PR. Arch Cervical involvement of diffuse idiopathic skeletal hyperostosis with dysphagia and rhinolalia. *Arch Otorhinolaryngol*. 1988;245(6):330–334.
11. Akhtar S, O'Flynn PE, Kelly A, et al. The management of dysphasia in skeletal hyperostosis. *J Laryngol Otol*. 2000;114(2):154–157.
12. Verlaan JJ, Boswijk PF, de Ru JA, et al. Diffuse idiopathic skeletal hyperostosis of the cervical spine: an underestimated cause of dysphagia and airway obstruction. *Spine J*. 2011;11(11):1058–1067.
13. Urrutia J, Bono CM. Long-term results of surgical treatment of dysphagia secondary to cervical diffuse idiopathic skeletal hyperostosis. *Spine J*. 2009;9(9):e13–e17.
14. Mizuno J, Nakagawa H, Song J. Symptomatic ossification of the anterior longitudinal ligament with stenosis of the cervical spine: a report of seven cases. *J Bone Joint Surg Br*. 2005;87(10):1375–1379.
15. Murayama K, Inoue S, Tachibana T, et al. Ossified posterior longitudinal ligament with massive ossification of the anterior longitudinal ligament causing dysphagia in a diffuse idiopathic skeletal hyperostosis patient. *Medicine*. 2015;94(32):e1295.
16. Hwang JS, Chough CK, Joo WI. Giant anterior cervical osteophyte leading to Dysphagia. *Korean J Spine*. 2013;10(3):200–202.