

# Management and outcomes of ovarian masses measuring $\geq 5$ cm in pregnancy - a series of six cases

## Abstract

Ovarian masses  $\geq 5$ cm in diameter have been found in only 0.04–0.05% of pregnant women. Most of the adnexal masses encountered during pregnancy are simple cysts  $< 5$ cm in diameter and about 70% would resolve by the early second trimester. The persistent cysts with gradual increase in size required surgical management. Adnexal masses requiring surgical intervention in pregnancy have been reported for around 1% to 2.3% of all gestations. In the series we reviewed 6 cases at different trimesters of pregnancy with ovarian masses measuring  $\geq 5$ cm that were managed surgically in a regional hospital in Oman. We observed the maternal perinatal outcome after removal of cysts either by Laparotomy or during cesarean delivery. Ovarian masses with acute complications warranted immediate surgical intervention irrespective of gestational age and incidental findings of ovarian masses during cesarean section required removal to avoid delayed diagnosis of malignancy and repeat surgery.

**Keywords:** ovarian mass, ovarian cyst, pregnancy, laparotomy, trimester, endometriomas, para ovarian cysts, haemoperitoneum

Volume 5 Issue 3 - 2016

Nishat Fatema,<sup>1</sup> Muna Mubarak Al badi,<sup>1</sup>  
Zarrin Tasnim Moon<sup>2</sup>

<sup>1</sup>Department of Obstetrics and Gynaecology, Ibri Regional Hospital, Oman

<sup>2</sup>Department of Human Biology, Molecular Genetics & Microbiology, University of Toronto, Canada

**Correspondence:** Nishat Fatema, Ibri Regional Hospital, Ibri PO Box 352, Ministry of Health, Oman, Tel +96892402237, Email nishat.doc.om@gmail.com

**Received:** November 29, 2016 | **Published:** December 05, 2016

## Introduction

Adnexal masses in pregnancy are a diagnostic and management challenge that is increasingly being faced by obstetricians. The incidence of ovarian masses occurring during pregnancy is about 1 in 400—in 1,312 live births. Adnexal masses requiring surgical intervention in pregnancy have been reported to be around 1% to 2.3% of all gestations.<sup>1,2</sup> Only 0.04–0.05% of pregnant women are found to have ovarian masses  $\geq 5$ cm in diameter. Most of the adnexal masses encountered during pregnancy are simple cysts  $< 5$ cm in diameter and about 70% resolve by the early second trimester. The persistent cysts with gradual increasing in size required surgical management. The conventional method of surgical intervention is laparotomy if the mass is  $> 5$ cm, solid, bilateral, or persists into the second trimester. Dermoid cysts is the most common around 25%, followed by corpus luteal cysts, functional cysts, and paraovarian cysts which are 17%, Serous cystadenomas 14%, mucinous cyst adenomas are 11%, Endometriomas are 8%. The overall incidence of malignancy in an adnexal mass noted in pregnancy is 1–8%. Malignancy is not the only concern associated with an adnexal mass in pregnancy. Masses that persist into the second trimester are at risk for torsion, rupture, or labor obstruction.<sup>3,4</sup> The fifth most common surgical emergencies are ovarian torsions. During pregnancy diagnosis of ovarian torsion can be challenging. Ovarian torsions are commonly misdiagnosed since the signs and symptoms are non-specific and similar to other abdominal diseases.<sup>5</sup>

We reported 6 case scenarios at different trimesters of pregnancy with adnexal masses. Among them 3 cases were presented with ovarian torsions at the 1st and 2nd trimesters of gestation and another set of 3 patients incidentally diagnosed to have ovarian cyst during caesarean section. We carried out this study to share our experience of managing ovarian cysts measuring  $\geq 5$ cm with acute presentation during the antenatal period that were operated on with conventional methods of laparotomy or incidental diagnosis during caesarean delivery and to evaluate the pregnancy outcomes after removal of the cysts.

## Material and methods

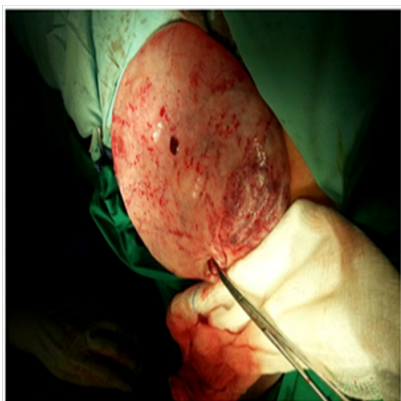
In our case series we observed 6 cases of ovarian masses with pregnancies that were operated on our hospital between January 2011 to 2016 October. Ovarian cysts  $\geq 5$ cm in size with the presence of an intrauterine alive fetus in any trimester of pregnancy that underwent surgery due to complications or with caesarian delivery were included. Cysts, which measured less than 5cm and were managed conservatively during the course of pregnancy, were excluded. Ethical approval was taken from the regional ethical committee. All data were extracted from computerized hospital medical records. The 1<sup>st</sup> trimester of pregnancy described until the 12<sup>th</sup> weeks of gestation and 2<sup>nd</sup> trimester counted the 13–28<sup>th</sup> weeks of gestation. Atosiban infusion for 48 hours post operative was used as tocolysis to prevent premature uterine contractions, for the cases who underwent laparotomy antenatal. Patients' data and neonatal outcomes are shown in Table 1. Data related to cyst characteristics and histopathological natures are listed in Table 2.

## Cases

### Case-I

A 25-year-old Primigravida at 8 weeks of gestational age attended our obstetric emergency unit with lower abdominal pain that lasted for two hours in duration. She conceived spontaneously with no history of ovarian stimulation treatments. On general examination she was vitally stable. However abdominal examination revealed that a palpable mass at the middle of the lower abdomen corresponding to 20 weeks in size was tender on palpation. Baselines of all investigations were within normal limit. Eventually a radiology ultrasound revealed that the gravid uterus with intra uterine alive fetus corresponding to 8 weeks of gestation and a huge anechoic well defined cystic lesion in the middle of lower abdomen measuring 13.8x8.8cm with no doppler signal around it. Both ovaries were masked by the mass. Minimal amount of free fluid was seen in the pouch of Douglas. An urgent laparotomy was undertaken, during which a large unilocular thick walled right-

sided ovarian cyst was detected measuring around 14x8.5cm in size (Figure 1). The cyst was twisted twice with clear fluid inside it. A right ovarian cystectomy was then carried out, and around 1700ml clear fluid aspirated from the cyst. The remaining ovarian tissue and fallopian tube were preserved. Postoperatively she was placed on oral progesterone (Tab Dydrogesterone 10mg BID) support upon hospital discharge. Histopathology report confirmed serous cyst adenoma in the ovary with signs of torsion. Tumor markers were within the normal limit. She was on regular ANC follow up which was uneventful. At 40weeks and 1day of gestation she delivered by a spontaneous vaginal delivery of a live baby of weighting 3kg with Apgar score 9/1minute and 10/5minute.



**Figure 1** Per operative findings of unilocular ovarian cyst (Case 1).

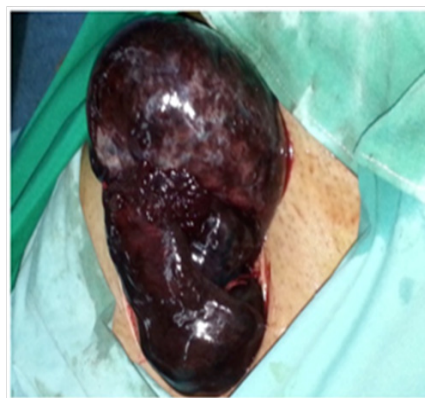### Case-2

A 31year old female G2P1 at 24weeks of gestation arrived at our ANC clinic with complaints of a sudden onset of lower abdominal pain since the past 4hours. She was registered at 9weeks of gestation at the local health center and was put on regular ANC follow up afterwards. Upon physical examination, her vital signs were within normal limits but she appeared to be in distress due to continuous pain. Upon abdominal examination the lower right quadrant was revealed to be tender on palpation, with voluntary guarding. Immediate radiological USG was done which detected a gravid uterus with a live fetus corresponding of 25weeks gestation, a well defined heterogenous solid cystic lesion was also seen in right adnexa measuring 14x6.6cm. No blood flow detected around the mass on color and power doppler ultrasound. The ultrasound finding suggested either ovarian torsion or complicated appendicular mass. So an emergency laparotomy was warranted. After abdominal exploration there was hemoperitoneum of around 200ml. A right sided tubo-ovarian gangrenous mass was detected that was found twisted three times around it's pedicle measuring around 15x6cm. Right sided salpingo-oophorectomy was carried out after untwisting the mass. The left tube and the ovary appeared to be normal. She kept on Atosiban infusion for 48hours to prevent premature uterine contraction after surgery. She was discharged on 4<sup>th</sup> postoperative day in stable condition with a viable intrauterine pregnancy. Histopathology of the mass suggested haemorrhagic corpus luteal cyst with evidence of torsion. She eventually had an uncomplicated spontaneous delivery of a full term live infant at 39 gestationalweeks with a weight of 2.5kg and Apgar score 9/1min and 10/5min.

### Case-3

A woman who was G3P2 was admitted at the 6weeks of gestation

with lower abdominal pain, which continued for 3-4hours in duration associated with vomiting. She was conceived with ovulation induction drug in view of secondary infertility. She had a history of right-sided ovarian cyst 1-year prior, which was managed conservatively by hormones. On USG, a gravid uterus with intrauterine gestational sac and a small fetal pole was seen. A large right adnexal mass was also noticed which measures to be around 6x7cm with free fluid surrounding it, using color Doppler poor signal suggestive of the ovarian torsion. The left ovary was normal and free fluid seen in the POD. We performed an emergency laparotomy. A gangrenous right ovarian cyst was observed measuring 6x7 (Figure 2) and right salpingo-oophorectomy was performed. Histopathology analysis revealed haemorrhagic gangrenous cyst. Postoperatively the patient received tocolysis as mentioned. She was discharged at the 4<sup>th</sup> postoperative day and had an uneventful pregnancy course. At 40weeks of gestation she had an emergency C/S in view of fetal distress and delivered an alive baby with birth weight of 3.3kg and Apgar scores of 8 and 10 at 1minute and at 5, respect minutes after birth.



**Figure 2** Intra operative findings of gangrenous ovarian mass (Case 2).

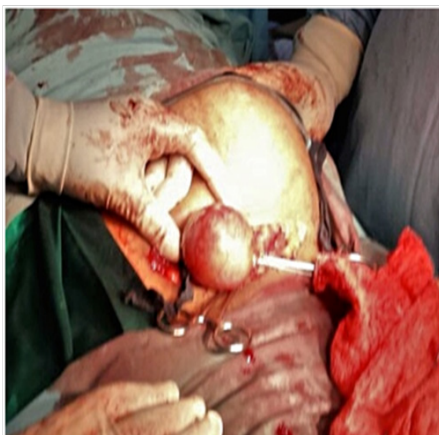### Case-4

A 37year old G2P0Ab1 women at 31weeks of gestation, arrived at our obstetric emergency unit with complaints of per vaginal bleeding since one hour. During antepartum follow up course she was diagnosed with a case of major degree placenta previa (Type IV) and was administered strict regular weekly follow up at the antenatal clinic. Her past medical and obstetric history was unremarkable except for the case of one 1<sup>st</sup> trimester complete miscarriage. Upon admission she was haemodynamically stable. She was kept under conservative management until 34<sup>th</sup> week of gestation. An emergent caesarian section was performed while she started bouts of per vaginal bleeding again at 34weeks of gestation. A live preterm infant was delivered with a weight of 1.7kg with a A/S-2/1min and 7/5min and shifted to neonatal intensive care unit (NICU) for further management. Following delivery of the baby, while checking for adnexa incidentally a right ovarian dermoid cyst was detected measuring around 6x4cm so, cystectomy was performed. Perioperative she received one pint of whole blood in view of haemorrhage due to transient uterine atony. Her post operative haemoglobin level was 11gm/dl. The histopathology report confirmed mature cystic teratoma (dermoid cyst). Her post operative period was uneventful and she was discharged in improved condition on the 5<sup>th</sup> post operative day.

### Case-5

The patient G9P7Ab arrived at the 38<sup>th</sup>week of gestation because

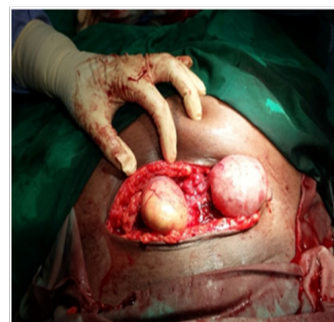
of labour pain. Her antenatal period was uneventful. She delivered a 3.0kg infant by emergency cesarean section due to fetal distress. The baby was transfer to SCBU (special care baby unit) for observation due to transient tachypnea. Upon examination of adnexa after delivery of the baby, a 6x6cm diameter mass (Figure 3) originating from the right ovary was found and cystectomy was done. Clinical diagnosis was suggestive of dermoid cyst. Histopathological results confirmed that the mass was a mature cystic teratoma (dermoid cyst).



**Figure 3** Incidental findings of unilateral ovarian cyst (Case 5).

**Case-6**

A female that was 39years of age G3P2 was admitted at 38weeks for planned cesarean section (CS) inview of previous history of 2 CS. She underwent cesarean section and delivered a healthy live baby with weight of 3.2kg and the Apgar scores measured at 1min and 5min was 9 and 10 respectively. Bilateral ovarian cyst that was observed measured 5x4cm on the right side and 5x5cm on the left side (Figure 4). So Bilateral ovarian cystectomy was performed. Histopathology revealed bilateral mature cystic teratoma.



**Figure 4** Incidental findings of bilateral ovarian cysts (Case 6).

**Results**

Among the 6 cases, 3 of those cases had acute presentation in their antenatal period and underwent laparotomy. For the other 3 cases cysts were found incidentally during caesarean delivery. For two of the cases (case 2&3) salpingo oophorectomy was done at affected side inview of ischemia due to torsion. For other cases (case 1,4,5,6) cystectomy was performed. Two patients at their 1st trimester and 1 case at her 2<sup>nd</sup> trimester of gestation arrived with acute presentation. One patient had a history of an infertility treatment with ovulation induction drug (Table 1). Five cases were found with unilateral cyst and one patient had bilateral cysts. All cysts serous cyst adenoma, haemorrhagic corpus luteal cyst, and mature cystic teratoma/dermoid cyst were benign which was confirmed by histopathology (Table 2). Case 4 had preterm cesarean delivery at 34weeks inview of antepartum haemorrhage due to major degree placenta previa and she was given blood transfusion due to haemorrhage. Neither the patients experienced miscarriage, premature rupture of membrane, non-progress of labour or malpresentation. All patients had hospital stay for 4-6 days postoperative on average. There were no perinatal mortality but 2 babies had SCBU admission due to prematurity and transient tachypnea which needed to be kept under observation (Table 3).

**Table 1** Demographic data of patients

Demography	Case 1	Case 2	Case 3	Case 4	Case 5	Case 6
Age	23	30	32	37	39	39
Gravida	1	2	3	2	9	3
Parity	0	1	2	0	7	2
Previous miscarriage	No	No	No	Yes	Yes	No
Gestational age at time of presentation	1sttrimestr	2ndtrimestr	1sttrimestr	Incidental findings during LSCS	Incidental findings during LSCS	Incidental findings during LSCS
History of infertility treatment	No	No	Yes	No	No	No
Hypertensive disorder	No	No	No	No	No	No
Gestational diabetes	No	No	No	No	No	Yes
Gestation at time of laparotomy	8	26	6	34	38	38

**Table 2** Maternal and fetal complications and outcomes following surgery

Maternal and fetal Complications & Outcomes	Case 1	Case 2	Case 3	Case 4	Case 5	Case 6
Type of surgery	Laparotomy+cystectomy	Laparotomy+salpingo oophorectomy	Laparotomy+salpingo oophorectomy	LSCS	LSCS	LSCS
Blood transfusion	No	No	No	Yes	No	No
Tocolysis (Atosiban) after cystectomy	Yes	Yes	Yes	No	No	No
Miscarriage after surgery	No	No	No	No	No	No
IUGR	No	No	No	Yes	No	No
PPROM	No	No	No	No	No	No
Preterm delivery	No	No	No	Yes	No	No
Placenta previa	No	No	No	Yes	No	No
Malpresentation	No	No	No	No	No	No
Non progress of labour	No	No	No	No	No	No
Gestation at time of delivery	40	39	40	34	38	38
Mode of delivery	SVD	SVD	LSCS	LSCS	LSCS	LSCS
Indication of LSCS	-	-	Fetal distress	APH	Fetal distress	Elective
Duration of hospital stay	5	5	4	6	5	5
Birth weight	3.3	2.5	3.3	1.7	3	3.2
Apgar score in 1 min	9	9	8	2	4	9
Apgar score in 5 min	10	10	10	7	6	10
Perinatal mortality	No	No	No	No	No	No
SCBU admission	No	No	No	Yes	Yes	0

**Table 3** Cyst related data

Cyst related data	Case 1	Case 2	Case 3	Case 4	Case 5	Case 6
Ovarian torsion	Yes	Yes	Yes	No	No	No
Size of cyst (cm)	14x8.5	15x6	6x7	6x4	6x6	5x4(right)5x5(Left)
Site of cyst	Unilateral	Unilateral	Unilateral	Unilateral	Unilateral	Bilateral
Cyst rupture	No	No	No	No	No	No
Cyst haemorrhage	No	Yes	Yes	No	No	No
Histopathology nature of cyst	Serous cyst adenoma	haemorrhagic corpus luteal cyst	haemorrhagic gangrenous cyst	Mature cystic teratoma	Mature cystic teratoma	Mature cystic teratoma
Tumor marker CA125	Normal	Normal	Normal	-	-	-

## Discussion

Adnexal masses measuring  $\geq 5$ cm in diameter have been found in 0.04–0.05% of pregnant women. We report a series of 6 cases with ovarian mass  $\geq 5$ cm with viable intrauterine pregnancy that was managed by surgical intervention. Removal of ovarian cysts during pregnancy is required to diminish possible cause of dystocia, eliminate

the danger of torsion, ruptures, or hemorrhage, and the danger of malignant transformation.<sup>6</sup> Less than 10 % of women with persistent adnexal masses during pregnancy may present in an acute condition.

There is a 1% increased risk of ovarian torsions in pregnant women in comparison to non-pregnant patients. Ovarian torsions in pregnant women mostly occurred in the first half of their pregnancy.

It is hypothesized that the risk of ovarian torsion are decreased by the second half of pregnancy due to increased gravid uterine size that limits the mobility of ovaries.<sup>7</sup>

Our patients that were complicated with ovarian torsions were presented themselves early 1<sup>st</sup> trimester and the first half of their 2<sup>nd</sup> trimester. The common symptoms of ovarian torsions are abdominal pain (100%), vomiting (85%), and leukocytosis (56%), which is mentioned in a study in which 39 cases of ovarian torsions during pregnancy were studied. Ovarian torsion is one of the important differential diagnosis in pregnancy specially if the patient has a history of infertility treatment.<sup>5</sup> Regarding our reported cases that had ovarian torsion all of them suffered from acute lower abdominal pain and one patient had history of infertility treatment with ovulation induction drug.

Ultrasound is the preferred diagnostic tool for detecting ovarian torsion. Acute torsion of the ovary may have various appearances on USG. If the ovary is shifted from its normal position, the presence of torsion may be assumed. To improve diagnostic specification, USG color Doppler analysis can be helpful because power Doppler imaging can detect the affected ovary has lack of blood flow.

The whirlpool sign (on the color Doppler the appearance of vessels are seen coiling in a twisted vascular pedicle) is the particular USG feature of ovarian torsions. In a series, the presence of this sign that was detected using color Doppler ultrasonography in 28 patients which were surgically confirmed to have torsion with a diagnostic accuracy of 87%.<sup>5,7</sup>

For our cases those who had ovarian torsion we predicted the torsion by color Doppler analysis before surgery.

CA 125 estimation as tumor marker is not useful in most patients because they are found to be normally elevated especially in the 1<sup>st</sup> trimester of pregnancy.<sup>2</sup> Once ovarian torsion is suspected clinically or diagnosed by USG the surgical intervention is performed. A report where emergency laparotomies were performed on pregnant women with adnexal masses revealed that spontaneous miscarriage and preterm birth rates were reported to be 40%. Maternal death from ovarian torsion has not been yet reported in the literature.<sup>1</sup> Generally, laparotomy is the choice of surgery for adnexal masses in pregnancy.<sup>4</sup>

However recently, laparoscopy is used during the first trimester of pregnancy when there is indication for diagnosis and treatment of ectopic pregnancy, acute adnexal disease, management of abnormal pelvic masses, and appendicitis.<sup>8</sup>

The concerns regarding the use of laparoscopy during pregnancy includes technical difficulty, possible injuries caused by laparoscopy instruments like the Veress needle, and the trocar, the insufficient studies regarding the effects of pneumoperitoneum the entry of carbon dioxide into the uterine cavity, and the suspected fetal acidosis due to maternal conversion of carbon dioxide to carbonic acid.<sup>4</sup>

In a study of 48 patients with adnexal masses operated by laparoscopy, the outcome of the pregnancies were normal in all cases except for one where there was fetal loss 4days after the laparoscopy. After laparotomy or laparoscopy for ovarian torsion the continuation of pregnancy without adverse outcomes are still not described well in literature.<sup>8</sup>

Previous studies reported that patients who underwent emergency surgery because of adnexal torsion or hemorrhage had a greater

incidence of abortion and preterm delivery compared to patients who underwent elective laparotomy.<sup>9</sup>

However, in our hospital settings we didn't have the laparoscopy facility at that time so we performed laparotomy for all our antenatal patients with ovarian torsion and we did not face any complications such as miscarriage, premature rupture of membrane or preterm delivery after surgery. Incidental findings of ovarian masses during cesarean section are infrequently occurring with an incidence of only 0.012%. The histopathology of most masses found during cesarean delivery are mature cystic teratoma (27%) and simple cysts (21.2%).<sup>10</sup>

For three of our cases, we found ovarian cysts incidentally during cesarean section and all of these cysts were mature cystic teratoma (dermoid cyst) confirmed by histopathology.

Regarding neonatal outcomes, preterm deliveries are frequently reported complication in the literature. But the effects of asymptomatic ovarian masses on the preterm labor rate is unknown, thus more studies are suggested. In recent studies there were no severe neonatal morbidity or mortality mentioned for those who had ovarian mass incidentally diagnosed during cesarean delivery.<sup>11</sup>

In our study among 6 babies, 2 babies had SCBU admission but due to preterm delivery for APH and transient tachypnea for fetal distress. There were no complications noted on neonatal outcome due to presence of ovarian mass.

## Conclusion

Although the ideal timing of surgery for persistent ovarian mass measuring  $>5$ cm in pregnancy is safe in the 2<sup>nd</sup> trimester of gestation, however in case of ovarian torsion or ruptured cysts with acute complications required immediate surgical management irrespective of gestational age. Removal of ovarian cysts found during cesarean delivery is suggested to diminish the need for future surgery avoiding the delay in the diagnosis of an ovarian malignancy, the adnexa should be carefully explored after closing the uterine incision during caesarean section.<sup>7</sup>

## Acknowledgements

We would like to thank Dr. Neeru Vinod Arora (Senior Consultant, Department of Obstetrics and Gynaecology, Ibri Regional Hospital) for her cooperation and for providing us with operative photographs (Case 5&6).

## Conflict of interest

The author declares no conflict of interest.

## References

1. Balci O, Gezginc K, Karatayli R, et al. Management and outcomes of adnexal masses during pregnancy: a 6-year experience. *J Obstet Gynaecol Res.* 2008;34(4):524–528.
2. Gasim T, Al Dakheel SA, Al Ghamdi AA, et al. Ovarian tumors associated with pregnancy: a 20-year experience in a teaching hospital. *Arch Gynecol Obstet.* 2010;282(5):529–533.
3. Sayin NC, Inal HA, Varol FG. Pregnancies complicated by adnexal masses: a case series. *Arch Gynecol Obstet.* 2008;278(6):573–577.
4. Hoover K, Jenkins TR. Evaluation and management of adnexal mass in pregnancy. *Am J Obstet Gynecol.* 2011;205(2):97–102.

5. Morton MJ, Masterson M, Hoffmann B. Case report: ovarian torsion in pregnancy – diagnosis and management. *J Emerg Med.* 2013;45(3):348–351.
6. Whitecar MP, Turner S, Higby MK. Adnexal masses in pregnancy: a review of 130 cases undergoing surgical management. *Am J Obstet Gynecol.* 1999;181(1):19–24.
7. Elhalwagy H. Management of ovarian masses in pregnancy. *Trends in Urology, Gynaecology & Sexual Health.* 2009;14(1):14–18.
8. Mathevet P, Nessah K, Dargent D, et al. Laparoscopic management of adnexal masses in pregnancy: a case series. *Eur J Obstet Gynecol Reprod Biol.* 2003;108(2):217–222.
9. Hess LW, Peaceman A, O'Brien WF, et al. Adnexal mass occurring with intrauterine pregnancy: report of fifty-four patients requiring laparotomy for definitive management. *Am J Obstet Gynecol.* 1988;158(5):1029–1034.
10. Cengiz H, Kaya C, Ekin M, et al. Management of incidental adnexal masses on caesarean section. *Niger Med J.* 2012;53(3):132–134.
11. Baser E, Erkilinc S, Esin S, et al. Adnexal masses encountered during cesarean delivery. *Int J Gynaecol Obstet.* 2013;123(2):124–126.