

Perforated benign giant gastric ulcer in a young patient: a rare entity

Abstract

A 33year old lady presented to our Accident and Emergency (A&E) department with acute onset epigastric pain that became generalised with vomiting and fever. History revealed chronic habitual use of 'over the counter' (OTC) non-steroidal anti-inflammatory drug (NSAID), Neurofen Plus for chronic shoulder pain and significant smoking habit. Clinical examination showed severe dehydration with evidence of sepsis and haemodynamic instability. There was a generalised abdominal tenderness with guarding. A diagnosis of acute abdomen with generalised peritonitis due to a suspected perforated viscus was made. An urgent CT scan showed free peritoneal air and fluid. She was transferred directly from the resuscitation room to the operating theatre and underwent an emergency laparotomy and closure of perforated giant gastric ulcer measuring 4cmx3cm in size. This case of rare giant perforated benign gastric ulcer in a young patient highlights the importance of early recognition of the risk factors such as the chronic use of NSAIDs in peptic ulcer disease and its complication.

Keywords: giant gastric ulcer, non-steroid anti-inflammatory drugs, sepsis, emergency laparotomy, helicobacter pylori

Volume 4 Issue 6 - 2016

Anish Gandecha, Kausalya Gunasekaran,
Stalin Dharmayan, Abraham Ayantunde

Department of Surgery, South end University Hospital, United Kingdom

Correspondence: Abraham Ayantunde, FRCS, Department of Surgery, Southend University Hospital, Westcliff-on-Sea, SS0 0RY, United Kingdom, Tel 01702435555, Fax 01702385856, Email biodunyantunde@yahoo.co.uk

Received: May 25, 2016 | **Published:** October 07, 2016

Abbreviations: A & E, accident and emergency; CT, computerized tomography; GDU, giant duodenal ulcer; GGU, giant gastric ulcer; NSAIDs, non-steroidal anti-inflammatory drugs; OTC, over the counter; PPI, proton pump inhibitors; PUD, peptic ulcer disease

Introduction

Peptic ulcer disease (PUD) of the upper gastrointestinal tract is a relatively common condition which is readily treated with lifestyle modifications and proton pump inhibitors (PPI). Clinicians are generally aware of known risk factors including *Helicobacter pylori* infection, non-steroidal anti-inflammatory drugs (NSAIDs) use and lifestyle factors such as stress and smoking. NSAIDs are one of the most common OTC purchased medications and regularly consumed by the general population. Regular NSAIDs users are up to four times more likely to develop gastric ulcers than non users.¹ Giant gastric ulcers (GGU) are arbitrarily defined as ulcers greater than 2cm in diameter.^{2,3} It is usually located in the lesser curvature of the stomach but can be present in any part of the stomach. GGU are more likely to be malignant especially in the elderly and very prone to perforation because of the size.³ We report this case of a rare perforated benign giant gastric ulcer in a young lady with the hope that it will reinforce the importance of recognising the risks factors such as the chronic use of NSAIDs and smoking in the pathogenesis of the entity.

Case presentation

A 33year old lady presented with sudden onset of a sharp stabbing epigastric pain and feeling of generally being unwell for 3days before presentation to the hospital. The pain gradually became generalised over the ensuing period. She had associated vomiting and fever. She had no other significant medical history apart smoking habit of 20 cigarettes a day for 17years and intake of up to 12 tablets of Neurone plus for the past 6years obtained without prescription for long term

shoulder pain. Clinical examination showed an acute ill lady with severe dehydration, evidence of sepsis and haemodynamic instability. She had a temperature of 38.2degree Celsius on admission. Recorded vital signs on admission were heart rate of 150beats/minute, blood pressure of 96/79 mmHg, respiratory rate of 20cycles/minute and oxygen saturation of 92% on air. There was a generalised abdominal tenderness with guarding. A diagnosis of acute abdomen with generalized peritonitis due to a suspected perforated viscus was made. Routine blood tests showed elevated leucocytosis of $18 \times 10^9/L$ and C-reactive protein of 250mg/dL. She was immediately commenced on aggressive intravenous fluid resuscitation, analgesics, intravenous antibiotics and oxygen supplement through a nasal catheter. She had a urethral catheter placed for hourly urine output measurement and a nasogastric tube placed for gastrointestinal decompression. An urgent computerised tomography (CT) scan showed free peritoneal air and fluid with significant thickening of the pylorus and duodenum. She was transferred directly from the resuscitation room to the operating theatre and underwent an immediate emergency laparotomy and closure of a perforated benign giant gastric ulcer. The findings at laparotomy included a perforated gastric ulcer in the anterior aspect of the pylorus measuring 4cm x 3cm in size. In addition, there was generalised peritonitis with about 2L of purulent gastric and duodenal content sand surrounding chronic scarring of the pyloroduodenal region.

The patient progressed satisfactorily postoperatively and she was discharged home on the 8th day post surgery with oral Omeprazole at 20mg daily and *H.pylori* eradication therapy (Figure 1). The histology of the ulcer biopsies only showed reactive gastritis with a perforated gastric ulcer slough. Follow up in the outpatient department showed full recovery from the operation with no upper GIT symptoms to report. Subsequent upper GIT endoscopy performed 12weeks post surgery revealed complete healing of the ulcer with negative urease test for *H.pylori*.

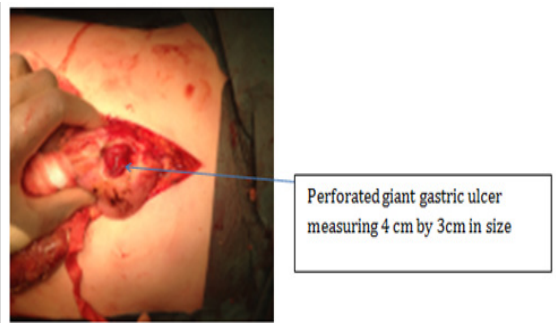


Figure 1 Intra-operative finding of a perforated giant gastric ulcer.

Discussion

Peptic ulcer disease (PUD) remains a common medical problem worldwide, with life time prevalence ranging from approximately 11% to 20% for men, and 8% to 11% for women in spite of widespread use of proton pump inhibitors (PPI) and H2 receptor antagonists. Given this substantial life time prevalence, there are major economic losses and health care expenditures associated with this problem.⁴ The etiopathogenesis of PUD is heterogeneous, and the most important factors in the causation of Peptic ulcer are NSAIDs use and *H. Pylori* infection. Development of gastric ulcer is primarily associated with weakened defence capability of the gastric mucosa and normal or lowered levels of gastric acid secretion, whereas duodenal ulcers are more commonly related to gastric acid hyper secretion.⁴ Giant gastric ulcers (GGU) are arbitrarily defined as ulcers more than 2cm in diameter.^{2,3} The data relating to the pathophysiology of giant peptic ulcers are scanty, and different explanations have been given as to why certain subsets of patients develop these giant ulcers. These factors include genetic predisposition, dietary or environmental factors, microbial influence, variations in immunological response or a combination of all these factors, besides *H. pylori* and NSAID use.⁵ The vast majority of giant peptic ulcers occur in the body of stomach compared to those developing in the pre-pyloric region or in the duodenum.⁶ Giant duodenal ulcers comprise approximately 1-2% of all duodenal ulcers which require surgical intervention. Giant peptic ulcers readily develop complications of bleeding, perforation or obstruction.⁶ The majority of GDUs present with bleeding. They manifest with melaena, haematochezia, haematemesis or a combination of the above. Complete endoscopic haemostasis is far more difficult to achieve in actively bleeding giant duodenal ulcers than the bleeding giant gastric ulcers.⁷ The reported perforation rate of these giant peptic ulcers varies between 0-7%.⁸ With the advent of proton pump inhibitors, majority of these giant ulcers are managed medically and surgical intervention is reserved for complications such as perforation, uncontrolled bleeding after initial endoscopic treatment and gastric outlet obstruction due to scarring.^{3,4,7} Eradication of *H. pylori* has been well documented to improve the healing rate of peptic ulcers.⁹

The surgical treatment of perforated peptic ulcer has changed dramatically in the last 3 decades, from radical surgery of vagotomy or even partial gastrectomy to simple open or laparoscopic omental patch closure.^{10,11} Laparoscopic approach is mainly reserved for low risk patients with minimal peritoneal contamination.¹⁰ Majority of the patients with perforated ulcer managed this way are subsequently followed with PPI and *H.pylori* eradication therapy. Simple patch

closure with biopsies of the ulcer edge or ulcer excision is the best option for perforated Gastric ulcers. The medical eradication of *H. pylori* results in resolution of ulcer diathesis without the long-term need for antacid therapy or definitive surgery in patients who have undergone simple omental patch closure for perforated Peptic ulcer disease. Our patient despite having a perforated giant gastric ulcer had a simple closure of the perforation without recourse to a radical resection. This was followed by PPI and *H.pylori* eradication therapy with a complete ulcer healing on follow up endoscopy 12weeks after surgery.

Conclusion

Despite the advances in the management of peptic ulcer disease with the use of PPIs and endoscopic techniques, giant peptic ulcers are still associated with high rates of morbidity and mortality. Therefore, surgical evaluation of a patient with giant PUD should be an integral part of the patient care. Discontinuation of NSAIDs and eradication of *H. pylori* are recommended as part of the treatment protocol. Perforated giant peptic ulcers need a more radical surgery than the routine simple omental patch closure or ulcer excision.

Acknowledgements

None.

Conflict of interest

The author declares no conflict of interest.

References

1. Malouf J, Alam S, Kanj H, et al. Hypergonadotropic hypogonadism with congestive cardiomyopathy: an autosomal-recessive disorder? *American Journal of Medical Genetics*. 1985;20(3):483-489.
2. Narahara K, Kamada M, Takahashi Y, et al. Case of ovarian dysgenesis and dilated cardiomyopathy supports existence of Malouf syndrome. *Am J Med Genet*. 1992;44(3):369-373.
3. McPherson E, Turner L, Zador I, et al. Ovarian failure and dilated cardiomyopathy due to a novel lamin mutation. *Am J Med Genet A*. 2009;149A(4):567-572.
4. Nguyen D, Leistriz DF, Turner L, et al. Collagen expression in fibroblasts with a novel LMNA mutation. *Bio chem Bio phys Res Commun*. 2007;352(3):603-608.
5. Chen L, Lee L, Kudlow BA, et al. LMNA mutations in atypical Werner's syndrome. *Lancet*. 2003;362(9382):440-445.
6. Gersak K, Strgulc M, Gorjup V, et al. Dilated cardiomyopathy and ovarian dysgenesis in a patient with Malouf syndrome: A case report. *Mol Med Rep*. 2013;8(5):1311-1314.
7. Gursoy A, Sahin M, Ertugrul DT, et al. Familial dilated cardiomyopathy hypergonadotrophic hypogonadism associated with thyroid hemiagenesis. *Am J Med Genet A*. 2006;140(8):895-896.
8. Şilfeler DB, Karateke A, Keskin KR, et al. Malouf Syndrome with hypergonadotropic hypogonadism and cardiomyopathy: two-case report and literature review. *Case Rep Obstet Gynecol*. 2014.
9. Burke B, Stewart CL. The nuclear lamins: flexibility in function. *Nat Rev Mol Cell Biol*. 2013;14(1):13-24.
10. Gruenbaum Y, Foisner R. Lamins: Nuclear intermediate filament proteins with fundamental functions in nuclear mechanics and genome regulation. *Annu Rev Biochem*. 2015;84:131-164.