

Lower gastrointestinal bleeding caused by stromal tumor of the jejunum - report of two cases

Abstract

We present clinical manifestations of a lower gastrointestinal bleeding caused by stromal tumor, discussing two cases of patients hospitalized and operated on at the Department of General and Colorectal Surgery, University of Medical Sciences in Poznań. In one case the female patient was admitted to the emergency department with signs of massive GI haemorrhage and consequently since within 2 hours she started to deteriorate with obvious signs of hypovolemic shock, the decision was made to perform exploratory laparotomy. The other patient's vital signs were clinically stable on admission that enabled diagnostics imaging. In both patients a part of jejunum with tumor was resected and side-to-side anastomosis was successfully performed, resulting in relatively fast recovery and hospital discharge on the 7th postoperative day. Although gastrointestinal stromal tumor is a rare type of cancer it may be the cause of massive, life threatening GI haemorrhage and has to be considered in a differential diagnosis.

Keywords: gastrointestinal stromal tumor, gastrointestinal haemorrhage, imatinib, molecularly targeted therapy

Volume 4 Issue 2 - 2016

Marta Magnuszewska, Karolina Horbacka, Piotr Krokowicz

Department of General and Colorectal Surgery, University of Medical Sciences, Poland

Correspondence: Karolina Horbacka, Department of General and Colorectal Surgery, University of Medical Sciences, Szajcarska 3, 61-285, Poznań, Poland, Tel +48 618739414, Email karolinahorbacka@hotmail.com

Received: October 24, 2015 | **Published:** March 29, 2016

Abbreviations: GIST, gastrointestinal stromal tumor; GI, gastrointestinal

Introduction

GI haemorrhage is one of the most common causes of emergency admission to surgical departments. Using emergency colonoscopy and gastroscopy the origin of bleeding can be ruled out in the majority of cases. Small bowel haemorrhage is a slightly different clinical entity which always has to be considered in differential diagnosis of GI bleeding, since it may result in a rapid deterioration and development of hypovolemic shock and it is the most difficult part of alimentary tract to be evaluated. Gastrointestinal stromal tumors (GIST) have been described as a distinctive tumor type in 1998 thanks to the recent breakthroughs in immunohistochemistry. They constitute about 1% of GI tract neoplasms and are believed to originate from interstitial cells of Cajal with pacemaker activity responsible for peristalsis. They usually grow within the muscle layer of alimentary tract wall outwards and consequently seldom cause mechanical obstruction comparing to colorectal cancer. They are diagnosed by the expression of proto-oncogene protein receptor c-kit-CD 117 antigen in 95% of the cases and in 60-70% - the expression of CD34 antigen is detected

by Immunohistochemistry.¹ The initial diagnosis of GIST influences surgical treatment (lymphadenectomy is not required after radical resection) and adjuvant strategy since GIST are refractory to standard chemotherapy and radiation but respond well to molecularly targeted therapies such as imatinib mesylate - inhibitor of protein tyrosine kinase. Undoubtedly radical resection is the only curative treatment but adjuvant molecularly targeted therapy is known to diminish the risk of local recurrence and is the only effective management of metastatic and recurrent disease in cases of limited possibilities of oncological resection.²

Case presentation

Case report I

A 40-year old woman (M.B., history number: KG-43875/14) was admitted to the Department of General and Colorectal Surgery,

University of Medical Sciences in Poznań on August 26, 2014 because of massive lower GI bleeding. On physical examination patient was pale with signs of severe hypovolemia, BP 105/50, HR 115-120/min, abdomen was soft, painless, without rebound tenderness, without distension, peristalsis is audible, fresh blood was detected on rectal examination. Laboratory tests: hemoglobin-4,4mmol/l, hematocrite 21%, red blood cell count $-2,4 \times 10^6/\mu\text{l}$, white blood cell count $-13,6 \times 10^3/\mu\text{l}$, electrolytes, blood urea, nitrogen, creatinine, glucose, amylase, bilirubin, aminotransferase within the recommended range. Coagulation parameters within normal limits. After admission intensive initial fluid resuscitation was started, blood and fresh frozen plasma transfusions were given and emergency endoscopy was performed. Gastroscopy ruled out duodenal haemorrhage. Colonoscopy revealed fresh blood in the entire colon and the active outflow of blood from terminal ileum but the bleeding site was not identified. Since the patient started to deteriorate with obvious signs of hypovolemic shock despite blood transfusions and fluid resuscitation, the decision for urgent operation was made, suspecting small bowel haemorrhage. The abdominal cavity was opened via ventral midline incision. There were no signs of inflammatory fluid or blood in the peritoneal cavity. A thorough exploration of small intestine revealed the tumor of the jejunum about 70cm from the ligament of Treitz causing massive bleeding to the lumen of the bowels (Figure 1). Radical resection of the tumor and adjacent jejunum with mesentery was performed followed by side-to-side anastomosis using the linear cutterstapler. Postoperative period was uneventful and the patient was eventually discharged home in a good condition on the 7th day after the operation. Postoperative initial histopathology examination showed fusocellular tumor 17x25x20mm with 3mitoses/50 HPF. Additional immunohistochemistry examination confirmed the diagnosis of GIST with characteristic immunophenotype: CD 117+, DOG1+, CD34+, SMA-, S100-, CKAE1/3-, Ki 67<2%.

Case report 2

A 54-year old man (W.K., history number: KG-25974/12) was admitted to the Department of General and Colorectal Surgery, University of Medical Sciences in Poznań on November 19, 2012 with the signs of lower GI bleeding. During physical examination

abdomen was soft, without tenderness or distention, dark blood on rectal examination was observed. The patient was afebrile with stable vital signs. Laboratory tests: hemoglobin - 5,6 mmol/l, red blood cell count - $2,8 \times 10^6/\mu\text{l}$, white blood cell count - $6,9 \times 10^3/\mu\text{l}$, hematocrite 25%, electrolytes, blood urea, nitrogen, creatinine, glucose, amylase, bilirubin, aminotransferases within a normal range. Coagulation parameters within normal limits. Gastroscopy and colonoscopy did not reveal the origin of bleeding. On ultrasound a solid tumor $33 \times 19 \times 21 \text{ mm}$ in hypogastrium 4 cm below the umbilicus was detected. Since patient's vital signs were clinically stable CT scan was performed showing exophytic enhancing tumor $24 \times 21 \times 35 \text{ mm}$ originating from small intestine and localized in the left midgastrium (Figure 2). With the suspicion of carcinoid the patient was qualified for laparotomy. Resection of the tumor and adjacent jejunum with mesentery was performed with side-to-side anastomosis using the linear cutter stapler. Postoperative period was uneventful and the patient was eventually discharged home in a good condition on the 7th day after the operation. Postoperative initial histopathology examination showed fusocellular tumor $25 \times 20 \times 23 \text{ mm}$ with 1 mitose/50 HPF.

Additional immunohistochemistry examination confirmed the diagnosis of GIST with characteristic immunophenotype: CD117+, DOG1+, SMA+, CKAE 1/3-, CD34, Ki 67 <5%.

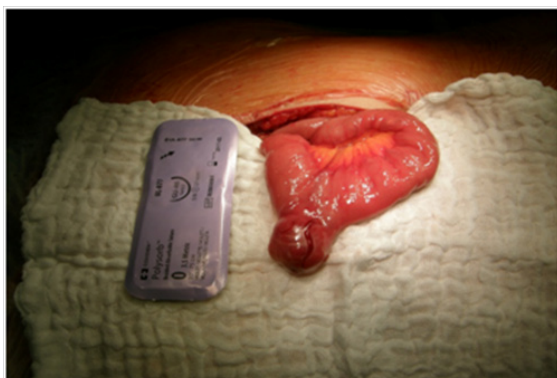

Figure 1 Intraoperative image at laparotomy demonstrating rectal injury gastrointestinal stromal tumor of the jejunum.

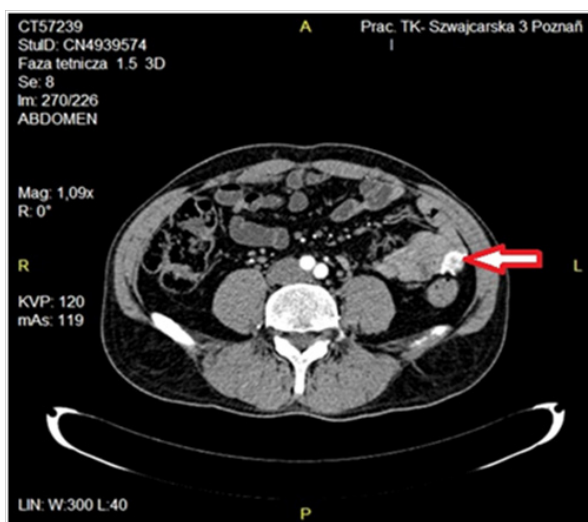


Figure 2 CT-enhanced scan - tumor localised in the left midgastrium originating from small intestine enhancing in arterial phase.

Discussion

We presented two patients operated because of lower GI bleeding caused by gastrointestinal stromal tumor of the jejunum. In the case of the female patient the decision for urgent laparotomy was made because of visible signs of hypovolemic shock. The young age of a mentioned patient and localization of GIST are not typical for a clinical picture of stromal tumors. The median age of patients diagnosed with GIST is 60-69 years and the onset of symptoms is influenced by the size of the tumor. Most of them are localized in the stomach (50-70%), which is associated with better prognosis, small intestine (20-30%), esophagus, colon and retroperitoneal space are unfrequent.³ The treatment strategy differs from GI cancer management. There is no need for extensive lymphadenectomy since lymph nodes are involved in less than 3% of patients.⁴ In case of recurrent disease and where the surgical options are limited because of the advanced stage, molecularly targeted therapy can be applied with a high respond rate. The course of the disease may be asymptomatic for a long time therefore the diagnosis is made in an advanced stage, which enables the only curative treatment - radical resection. The proliferation of blood vessels and infiltration on mesentery may result in massive GI bleeding and emergency operation is the only possible treatment. GIST should be considered in differential diagnosis of GI haemorrhage especially in the absence of the origin of sanguination on endoscopy. CT enhanced scan or MRI are useful imaging tools provided patient's vital signs are stable.

Acknowledgements

None.

Conflict of interest

The author declares no conflict of interest.

References

1. Tornillo L. Gastrointestinal stromal tumor - an evolving concept. *Front Med (Lausanne)*. 2014;1:(43).
2. The ESMO/European Sarcoma Network Working Group. Gastrointestinal stromal tumors: ESMO Clinical Practice Guidelines for diagnosis, treatment and follow-up. *Annals of Oncology*. 2014;25(suppl 3):iii21-iii26.
3. Mucciarini C, Rossi G, Bertolini F, et al. Incidence and clinicopathologic features of gastrointestinal stromal tumors. A population-based study. *BMC Cancer*. 2007;7:230.
4. Rutkowski P, Kulig J, Krzykowski M, et al. Nowotwory podścieliskowe przewodu pokarmowego (GIST). Aktualne (2010) zasady postępowania diagnostyczno-terapeutycznego; 2010.