Research Article

Open Access CrossMark

Morphological variation and dimensions of left coronary artery: a cadaveric study

Abstract

Background: Coronary arteries play an important role in perfusion of the heart tissues. Variations or anomalies in coronary arteries may be asymptomatic while some can be symptomatic and even cause sudden death. Knowledge of coronary artery variations is important in diagnosis and treatment of cardiovascular diseases. Aim: To describe variation of left coronary artery.

Materials and methods: We dissected and grossly examined a total of 78 human hearts to describe coronary artery variations in origin and course.

Results and discussion: The mean outer diameter of left coronary artery (LCA), left anterior descending (LAD) and circumflex artery (CA) was 4.34±2.01mm, 4.21±0.28mm, and 2.73±0.6mm respectively. Whereas the mean length of LCA, LAD and CA was 10.2±3.5mm, 83.4±17.8mm, and 44.6±17.9mm respectively. The main trunk of LCA bifurcated in 63 specimens (80.76%), trifurcated in 8 specimens (10.25%), quadrifurcated in 6 specimens (7.69%) and pentafurcated in 1 specimens (1.28%).

Conclusion: Knowledge of the normal and variant anatomy of coronary arteries is indispensable and imperative both in diagnosis, treatment and implementation of interventional measures.

Keywords: left coronary artery, variation, branching pattern, left anterior descending artery, circumflex artery

Volume 5 Issue 4 - 2018

Anil Kumar,[1] Madan Lal Ajmani,[1] Penprapa S Klinkhachorn[2]

[1]Department of Anatomy and Neurobiology, Oman Medical College, Oman

[2]Department of Pathology, Anatomy and Laboratory Medicine, West Virginia University Health Sciences Center, USA

Correspondence: Anil Kumar, Assistant Professor, Department of Anatomy and Neurobiology, Oman Medical College, Sohar, Al tareef, Postal code: 391, PO Box: 321, Sultanate of Oman, Tel 968 22314761, 968 95393982, Email anil@omc.edu.om

Received: June 15, 2018 | **Published:** August 21, 2018

Introduction

The heart is supplied by two coronary arteries (left and right) and their branches, which are located between the epicardium and myocardium. The right (RCA) and the left coronary arteries (LCA) arise from the aortic sinus of valsalva at the root of the aorta and encircle the base of ventricles like a crown.[1] The LCA is responsible for irrigation of most of the left ventricle and also a considerable proportion of the right ventricle.[2] It lies between the pulmonary trunk and the left atrial auricle, emerging into the atrioventricular (AV) groove, in which it turns left. Reaching the atrioventricular (AV) groove, the LCA usually divides into two main branches: left anterior descending (LAD) and circumflex artery (CA).[3]

Knowledge of normal and variant anatomy and anomalies of coronary circulation is an increasingly vital component in the management of congenital and acquired heart diseases. The term "anomaly" is used for variations that occur in less than 1% of the general population.[4] The LCA presents wide variability in its morphological expression. Thus, this study aimed to determine these variations in the LCA and its branches. The study of coronary arteries will be useful to the cardiologists and radiologists to predefine abnormalities by invasive and non-invasive studies. Hence increasing use of diagnostic and therapeutic interventional procedures requires a sound, basic knowledge of the coronary artery pattern.[5]

Numerous data on the variations of the arteries have been reported, but still it is better to explore them further with respect to their clinical significance. The present study intends to establish the branching patterns for the LCA in western population. This knowledge has significance as these variations have anatomical, pathophysiological diagnostic and therapeutic implications.

Materials and methods

Materials

The present observational descriptive study was conducted at the department of Anatomy and Neurobiology, Oman Medical College affiliated with West Virginia University (WVU), Sohar, and Sultanate of Oman. The specimens were collected from a cadaver sample provided by Department of Anatomy, West Virginia University, United States. With respect to the West Virginia University cadaver sample, the left coronary artery and its branches were dissected in situ and were used to document the variation of branching patterns of the aorta.

Ethical approval

Ethical approval for this research was granted by the Research Ethics Committee (REC) of the Oman Medical College affiliated with West Virginia University (WVU), Sohar, and Sultanate of Oman.

Cadaver sample

In this study, total seventy eight formalin fixed cadaveric hearts specimens irrespective of age, sex, and race were collected from year September 2011 to August 2017 for the purpose of teaching undergraduate students were utilized. As part of routine forensic examination the pathologists bisect the aorta longitudinally and examine the macroscopic appearance of the luminal surface from the proximal ascending aorta to the point of bifurcation into the common iliac arteries. The gross appearance of the vessel is recorded and categorised as normal, fatty streaks, plaques, ulcerations, calcifications, haemorrhage, thrombus or aneurismal. The specimens which were putrefied, showed crush and cut injury of heart specimens were excluded from the study.

© 2018 Kumar et al. This is an open access article distributed under the terms of the Creative Commons Attribution License, which permits unrestricted use, distribution, and build upon your work non-commercially.

Copyright: ©2018 Kumar et al.

Methodology

By cutting the ribs and sternum, the thoracic cavity was opened. The great vessels were ligated by thread at two then cut in between. The parietal pericardium was incised heart along with great vessels was taken out of the pericardial cavity. The aorta and pulmonary trunk were excised above the supra-valvular ridge. With gradual separation and retraction of the myocardial fasciculi, the coronary arteries and their branches were dissected on the surface of the heart in the atrioventricular and interventricular grooves. At collection, samples were placed in plastic jars containing 10% neutral buffered formalin and labelled according to the serial number allocated.

By micro dissection the epicardium was removed, and coronary arteries were observed. The left coronary artery (LCA) was dissected out carefully to avoid damage to small branches. The number of terminal branches of the main trunk was noted.

In the cadavers, the left coronary artery and its branches dissection in situ involved careful removal of any tissues, particularly fascia, from around the blood vessels. Once the left coronary artery and its branches were fully exposed, the identification of the branching vessels and their relative positions to key anatomical landmarks in situ were documented. Evidence of variations or anomalies in the vessels was recorded. The external diameters at the starting points of these branches were measured using 0.01mm sensitive digital calipers. Following dissection, a metal tag with the cadaver identification number was sutured to each heart, which was then stored in a large plastic container containing neutral buffered formalin. All data were initially recorded by hand on data sheets and subsequently transferred into Microsoft Office Excel 2007 for analysis. The dissected vessels and their branches were also photographed using a Sony Cyber-shot 7.2 mega pixel camera. Graphs and tables were generated using Microsoft Office Excel 2007.

Statistical analysis

All statistical analysis was conducted with help from the Department of public health and epidemiology (Statistical Sciences), Oman Medical College affiliated with West Virginia University (WVU), Sohar, and Sultanate of Oman. The data is reported as mean±standard deviation. Statistical analysis was performed using the Statistical Package for the Social Sciences version 16.0.0 for Windows (SPSS Inc, Chicago, IL, USA). Normality of the sample data was ascertained using the Shapiro-Wilk W Test, using a level of significance of 5%. Parametric analysis was performed on variables found to be normally distributed. The independent t-test was used in order to determine significant differences between mean values as the analysis looked at significant differences different sample sites.

Results

In all 78 heart specimens, the dissected left coronary artery (LCA) was found to arise from the left posterior aortic sinus of the ascending aorta. As mentioned in Table 1, the mean outer diameter and length of LCA was 4.34±2.01mm and 10.2±3.5mm respectively. The mean diameter of left anterior descending (LAD) was 4.21±0.28 mm and its length was 83.4±17.8mm whereas the mean diameter of circumflex artery (CA) was 2.73±0.6 mm and its length was 44.6±17.9mm.

Table 1 Mean diameter and mean length of LCA and its branches

S.No.	Name of artery	Diameter (in mm)	Length (in mm)
1	Left coronary artery (LCA)	4.34±2.01	10.2±3.5
2	Left anterior descending artery (LAD)	4.21±0.28	83.4±17.8
3	Circumflex artery (CA)	2.73±0.6	44.6±17.9

Main trunk of LCA after its origin runs for little distance and then mainly divides into LAD and circumflex artery CA. The most frequent type of division was a bifurcation into two terminal branches as LAD and CA (Figure 1A). Third branch coming from the main trunk of LCA other than LAD and CA is called ramus intermedius (diagonal) which is seen in trifurcation of LCA (Figure 1B). In quadrafurcation total four branches arise from main trunk, they are LAD, CA and two diagonal arteries (Figure 1C). In pentafurcation, it is divided into LAD, three diagonal and one circumflex branch (Figure 1D). The main trunk of LCA bifurcated in 63 specimens (80.76%), trifurcated in 8 specimens (10.25%), quadrifurcated in 6 specimens (7.69%) and pentafurcated in 1 specimens (1.28%).

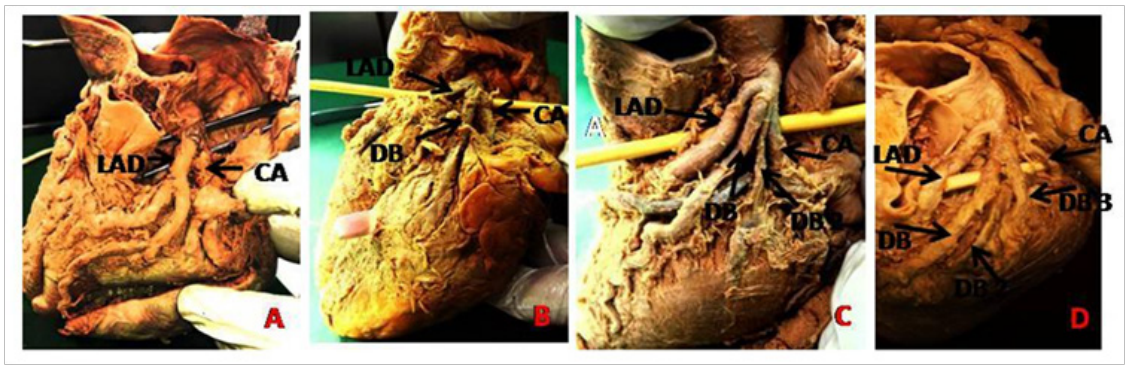

Figure 1 (A) Photographs show bifurcation in two branches of LCA arising as LAD and CA.
(B) Photographs show bifurcation in three branches of LCA arising as LAD, CA, diagonal branch (DB).
(C) Photographs show quadrifurcation in four branches of LCA arising as LAD, CA, 2 diagonal branches.
(D) Photographs show pentafurcation in five branches of LCA arising as LAD, CA, 3 diagonal branches.

Abbreviations: LCA, left coronary artery; LAD, left anterior descending; CA, circumflex artery; DB, diagonal artery

Citation: Kumar A, Ajmani ML, Klinkhachorn PS. Morphological variation and dimensions of left coronary artery: a cadaveric study. *MOJ Anat & Physiol.* 2018;5(4):266‒270. DOI: 10.15406/mojap.2018.05.00207

Copyright: ©2018 Kumar et al.

Discussion

Nowadays, with the extensive use of advanced image diagnostic techniques and the development of non-aggressive treatments, a in-depth knowledge of anatomy of the normal coronary and its variations and anomalies is important. Branches of coronary arteries may vary in origin, distribution, number and size. The origins of coronary arteries show great variability, about 90% of anomalies were anomalies of origin.[6] It was observed that in all the 78 heart specimens, 3 aortic sinuses were present and LCA arises from left posterior aortic sinus. Similar observations were reported by the Kalpana RA[7] James[8] Sahni & Jit et al.,[9] and Kulkarni J[10] The LCA is the main source of blood supply to the heart.[2,3] Kalbfleisch and Hort11, who conducted a study on the area irrigated by each of the coronary arteries using postmortem angiography, showed that the LCA irrigated 68.8% of the cardiac muscle mass and 79% of the left ventricular cardiac muscle mass. Hence, obstructive disease of the LCA may reduce the coronary flow to a large proportion of the ventricular myocardium, and as a result, atherosclerotic diseases of the LCA have more serious complications than those of the RCA.[11]

Bhele et al.,[12] reported, when the common trunk of LCA is less than 5 mm then it is considered to be short and when it is more than 15mm it's considered as long common trunk. In the present study 60 (77%) of the cases, the trunk of the LCA was short measuring less than 5 mm and in 18 (13%) of the specimens, found more than 10mm. The average length ranged from 2 mm to 16 mm. Results were consistent with Reig & Petit[2] study, an average of 10.8mm. Kalpana RA[7] observed length of the main trunk of LCA ranges between 6 mm to 15 mm. Study conducted by Kulkarni et al.,[10] revealed the length of LCA to be 5mm in 76.7% of specimens, while it was observed to be 10mm in 5% of specimens. Waller & Schlant[13] observed the length of LCA to be 6 mm in 76% of all specimens and 10mm in 3% of specimens. Banchi[14] observed that the length of the LCA trunk was <5mm in 2% of specimens. Fox et al.,[15] found the length of LCA to be <6mm in 36% of all specimens while >20mm in 5% of all specimens on cine angiofilms. Reddy & Pusala[16] reported, the left main (LM) coronary artery ranges in length from 1 to 25mm before bifurcating into the LAD and CA. The LAD coronary artery measures from 10 to 13cm in length, whereas the CA artery measures about 6 to 8 cm in length. In the current study, the mean length of LAD and CA was 83.4±17.8mm and 44.6±17.9mm respectively. Dattatray D et al.,[17] reported the mean length of LAD and CA was 85±25.2mm and 45.6±19.9mm respectively.

The short main LCA explain some failures of adequate coronary perfusion. During aortic valve surgery, myocardial perfusion depends on the placement of one or more cannulas in the coronary arteries. In this regard, the length of main LCA prior to its bifurcation is particularly important.[18] Short trunk of LCA could be at risk during aortic valve replacement surgeries. The catheter may be inserted into one of the terminal branches, thereby producing an ischemic area, which can lead to arrhythmia, myocardial ischemia or both. Short trunk also been considered as a risk factor in developing coronary atherosclerosis.[19] No relationship has been described between a long main LCA trunk and any type of pathology or technical complications.[18]

The diameter of main stem and larger branches of LCA was recorded. The mean diameter of LCA, LAD and CA was 4.34±2.01mm, 4.21±0.28mm and 2.73±0.6mm respectively. Similar findings were reported by Dattatray D et al.,[17] the mean diameter of LCA, LAD and CA was 4.64±1.02mm, 3.19±0.5mm and 2.94±0.7mm respectively. Fazliogullari Z et al.,[20] noted that the average diameter of LCA, LAD and CA was 4.44±1.79mm, 3.13±0.64mm, and 2.98±1.08mm respectively. Also Rex N et al.,[21] measured the human coronary artery size by cine-arteriography reported the mean diameter of LAD and CA was 3.5±0.5mm and 3.2±0.7mm respectively. Reg & Petit[2] studied all characteristics of the main trunk of LCA in 100 autopsy heart specimens found the diameter of the main trunk measured at its mid-point was between 3 to 7mm with average value 4.86±0.8mm. Jeffery JP[22] mentioned that balloon angioplasty of aorto-ostial lesions and ostial lesions of LAD and CA coronary arteries has been associated with reduced success and high recurrence rates owing to smooth muscle and eccentric intimal proliferation noted pathologically in ostial lesions.

As per the observations of Loukas et al.,[23] it is necessary to determine the incidence of the variations, which are possibly capable of inducing sudden cardiac death, in order to evaluate the value of screening. Variation in the origin of coronary arteries and their branching pattern can pose difficulties in imaging by conventional catheters, thereby creating problems in diagnostic and therapeutic interventions.[10] In present study, bifurcation of LCA was found in majority of cases 63 specimens (80.76%), trifurcated in 8 specimens (10.25%), quadrifurcated in 6 specimens (7.69%) and pentafurcated in 1 specimens (1.28%). Similar results have been reported by Fazliogullari Z et al.,[20] Surucu et al.,[24] Reig & Petit[2] and Kalpana R[7]. Bosco[25] observed that in 2% of the specimens, there was no division of the main LCA trunk, while 42% of the specimens had bifurcation and 55% had trifurcation. Hadziselimovic[26] reported that out of the 52% of cases with bifurcation in the series, 44% had trifurcation and only 4% had more than three branches. Benther et al.,[27] observed 2% of specimens with no division of the trunk, 89% with bifurcation and 9% with trifurcation. The published data from different studies show a certain degree of disparity in results, depending on the technique used by the authors. A comparison of the various studies is shown in Table 2. The Diagonal branch may be considered to be the artery located in the angle formed by the LAD and CA whereas a broader approach envisages that the Diagonal branch originates in the vertex of the angle formed by the terminal branches of the LCA or in the initial millimetres of the LAD and CA.[28] Identification of the diagonal artery is important clinically. Its area of distribution to the heart is small. In the absence of this artery the area is irrigated by the branches of LAD and CA. Therefore due to the occlusion of LAD & CA more area of the heart would be affected.[14]

Table 2 Comparison of branching pattern of left coronary artery with previous studies

S.No.	Authors and year	No. of cases (n)	Bifurcation (%)	Trifurcation (%)	Quadrification (%)	Pentafurcation (%)
1	Banchi[14]	-	64	31	5	-
2	Bosco[25]	-	42	55	-	-
3	Benther[27]	-	89	9	-	-
4	Kalbfleisch et al.[11]	400	41	53	6	-

Citation: Kumar A, Ajmani ML, Klinkhachorn PS. Morphological variation and dimensions of left coronary artery: a cadaveric study. *MOJ Anat & Physiol.* 2018;5(4):266‒270. DOI: 10.15406/mojap.2018.05.00207

Copyright: ©2018 Kumar et al.

Table continued...

S.No.	Authors and year	No. of cases (n)	Bifurcation (%)	Trifurcation (%)	Quadrification (%)	Pentafurcation (%)
5	Leguerrier et al.[35]	80	65-70	20-30	10-May	-
6	Kalbfleisch et al.[34]	141	51.1	44.4	4.3	-
7	Hadziselimovic[26]	-	52	44	4	-
8	Bapista[29]	150	54.7	38.7	6.7	-
9	Lo et al.[36]	200	69.3	36.6	-	-
10	Cavalcanti[32]	110	60	38.18	-	-
11	Kalpana[7]	100	47	40	11	1
12	Surucu[24]	40	47.5	47.5	2.5	2.5
13	Reig & Petit[2]	100	62	38	-	-
14	Lujinovic et al.[37]	20	65	35	-	-
15	Ortale[40]	20	50	46	4	-
16	Das Hirak[33]	100	60	35	5	-
17	Ballesteros & Ramirez[19]	154	52	42.2	5.8	-
18	Fazliogullari et al.[20]	50	46	44	10	-
19	Bhimalli et al.[30]	100	56.6	33.3	8.3	1
20	Dattatray et al.[17]	64	54.7	35.9	7.8	-
21	Agnihotri et al.[28]	100	66	30	4	-
22	Dharmendra[41]	93	58	35.4	6.4	-
23	Hosapatna et al.[38]	30	93.3	6.7	-	-
24	Jyoti[40]	60	50	10	-	-
25	Reddy & Pusala[16]	110	86	14	-	
26	Vandana & Tejas[42]	30	80	13.3	3.3	3.3
27	Bhele et al.[12]	50	70	24	6	-
28	Shetty & Tagi[39]	30	66.6	23.3	10	-
29	Present study	78	80.7	10.2	7.69	1.28

Conclusion

The high degree of variability of left coronary artery and its branching patterns have anatomical, pathophysiological diagnostic and therapeutic implications. Adequate knowledge of these variations with regard to source, and incidence is important for the interpretation of coronary angiography, stenting procedures and surgical myocardial revascularization.

Acknowledgments

The authors would like to acknowledge the support exerted by Dr. M. L. Ajmani, Professor and Head, Department of Human structure and Neurobiology, Oman Medical College (OMC), Oman. The authors submit their sincere thanks to the Head and all the faculty of Department of Anatomy, West Virginia University, United States, for providing the specimens. The authors extend their gratitude to Dr. Saleh Al Khusaiby, Dean, Dr. Mohammad Al Shafaee, Vice Dean, and Dr. Mubarak Pasha, Deputy Dean of OMC. The authors also thank the faculty and technicians of OMC for their help to complete this study.

Conflicts of interest

All Authors have none to declare.

References

1. Williams PL, Bannister LH, Berry M. *Gray's Anatomy*. 38th ed. New York: Churchill Livingstone; 1995:1016–1018.
2. Reig J, Petit M. Main trunk of the left coronary artery: anatomic study of the parameters of clinical interest. *Clin Anat*. 2004;17(1):6–13.
3. Gatzoulis MA. Heart and great vessels. In: Standring S, editors. *Gray's Anatomy: The anatomical basis of clinical practice*. 40th ed. Philadelphia: Churchill Livingstone (Elsevier); 2008:978–980.
4. Angelini P. Normal and anomalous coronary arteries: Definitions and classification. *Am Heart J*. 1989;117(2):418–434.
5. Alarming Statistics from India. 2013.
6. Garg N, Tiwari A. Primary congenital anomalies of the coronary arteries: a coronary arteriographic study. *Int J Cardiol*. 2000;74(1):39–46.
7. Kalpana R. A study of principal branches of coronary arteries in humans. *J Anat Soc India*. 2003;52(2):137–140.
8. James TN. Anatomy of the coronary arteries. New York: Paul B Hoeber, Inc. Medical division of Harper and Brothers; 1961:12–38.
9. Sahni D, Jit I. Origin and size of the coronary arteries in the north-west Indians. *Indian Heart J*. 1989;41(4):221–228.

Citation: Kumar A, Ajmani ML, Klinkhachorn PS. Morphological variation and dimensions of left coronary artery: a cadaveric study. *MOJ Anat & Physiol.* 2018;5(4):266–270. DOI: 10.15406/mojap.2018.05.00207

10. Kulkarni JP. Variant anatomy of coronary arteries. *Heart India*. 2013;1:46–51.

11. Kalbfleisch H, Hort W. Quantitative study on the size of coronary artery supplying areas postmortem. *Am Heart J*. 1977;94(2):183–188.

12. Bhele AV, Ughade HM, Shaikh S, et al. A study of course, branches and variations of the coronary arteries in the human cadaveric heart. *Int J of Cont Med Res*. 2017;4(7):1533–1537.

13. Waller B, Schlant R. *Anatomy of Heart. Husst's The Heart*. 13th ed. The McGraw-Hill Companies, Inc; 2011:2500.

14. Banchi A. Morfologia delle arteriae coronariae cordis. *Arch Ital Anat Embriol*. 1904;3:7–164.

15. Fox C, Davies MJ, Webb-People MM. Length of left main coronary artery. *Br Hear J*. 1973;35(8):796–798

16. Reddy MV, Pusala B. Anatomical variations in branching pattern and dimensions of coronary arteries: a cadaveric study from south India. *J of Dent and Med Sci*. 2016;15(8):21–28.

17. Dattatray DD , Takkallapalli A , Purushottam AG , et al. Clinically relevant morphometric analysis of left coronary artery. *Int J Biol Med Res*. 2012;3(1):1327–1330.

18. Green GE, Bernisters, Repper EH. The length of the left main coronary artery. *Surgery Dec*. 1967;62:1021–1024.

19. Ballesteros Le, Ramirez LM. Morphological expression of left coronary artery-A direct anatomical study. *Folia Morphol*. 2008;67(2):135–142.

20. Fazliogullari Z, Karabulut AK, Unver DN, et al. Coronary artery variations and median artery in Turkish cadaver hearts. *Sing Med J*. 2010;51(10):775–780.

21. MacAlpin RN, Abbasi AS, Grollman JH Jr, et al. Human coronary artery size during life. *Radiology*. 1973;108(3):567–576.

22. Nissen S. Coronary angiography and intravascular ultrasound imaging. *Am J Cardiol*. 2001;87(4A):15A–20A.

23. Loukas M, Groat C, Khangura R, et al. The normal and abnormal anatomy of the coronary arteries. *Clin Anat*. 2009;22(1):114–128.

24. Surucu HS, Karahan ST, Tanyeli E. Branching pattern of left coronary artery and an important branch of the median artery. *Saudi Med J*. 2004;25(2):177–181.

25. Bosco GA. *Diagnóstico anátomo-topográfico de la obstrucción arterial coronaria.* Buenos Aires: Artes Gráficas Modernas; 1935:27–30.

26. Hadziselimović H. *Blood vessels of the human heart*. Leipzig: Thieme; 1982:14–20.

27. Benther P, Barra JA, Blanc JJ. Descriptive anatomical study of the major coronary trunks and the principal epicardial collaterals. 125 cases. *Nouv presse med*. 1976;5(2):71–75.

28. Agnihotri G, Kaur M, Kalyan GS. Branching patterns of left coronary artery among north Indians. *Anat J of Africa*. 2013;2(2):145–150.

29. Leguerrier A, Calmat A, Honnart F, et al. Anatomic variations of the common trunk of the left coronary artery (apropos of 80 dissections). *Bull Assoc Anat (Nancy)*. 1976;60(171):733–739.

30. Kalbfleisch H, Hort W. Human coronary arterial patterns. *Dtsch Med Wochenschr*. 1976;101(29):1092–107.

31. Baptista CA, Didio LJ, Prates JC. Types of division of the left coronary artery and the ramus diagonalis of the human heart. *Jap Heart J*. 1991;32(3):323–335.

32. Lo EA, Dia A, Ndiaye A, et al. Anatomy of coronary arteries. *Dakar Med*. 1994;39(1):23–29.

33. Cavalcanti JS. Anatomical variations of the coronary arteries. *Arq Bras Cardiol*. 1995;65(6):489–492.

34. Lujinovic A, Ovcina F, Voljevica A, et al. Branching of main trunk of left coronary artery and importance of her diagonal branch in cases of coronary insufficiency. *Bosn J Med Sci*. 2005;5(3):69–73.

35. Ortale JR, Filho JM, Paccola AMF, et al. Anatomy of the lateral, diagonal and anterosuperior arterial branches of left ventricle of the human heart. *Revista Brasileira de Cirurgia Cardiovascular*. 2005;20(2):50.

36. Das Hirak. Termination of left coronary in the population of Assam. *Nat J of Bas Med Sci*. 2005;1(3):145–148.

37. Bhimalli S, Dikshith D, Siddibhavi M. A study of variations in coronary arterial system in cadaveric human heart. *WJ of sci and tech*. 2011;1(5):30–35.

38. Dharmendra P, Takkapalli A, Madan S, et al. Clinically significant anatomical variations of the left coronary artery in cadaveric hearts. *Int J Cur Res Rev*. 2013;05(12):39–44.

39. Hosapatna M, D'Souza AS, Prasanna LC, et al. Anatomical variations in the left coronary artery and its branches. *Sing Med J*. 2013;54(1):49–52.

40. Jyoti P Kulkarni. Variant anatomy of coronary arteries. *Heart India*. 2013;1(2):46–51.

41. Vandana R, Tejas. Anatomical variation in branching pattern and dominance in coronary arteries: a cadaveric study. *Int J Anat Res*. 2017;5(1):3611–3617.

42. Shetty NM, Tagi V. The study of Branching pattern and variations in the left coronary artery in human heart with a unique case of crossing of coronary arteries-A cadaveric study. *Indian J Clin Anat Phys*. 2017;4(1):48–50.

Citation: Kumar A, Ajmani ML, Klinkhachorn PS. Morphological variation and dimensions of left coronary artery: a cadaveric study. *MOJ Anat & Physiol.* 2018;5(4):266–270. DOI: 10.15406/mojap.2018.05.00207