

Case report on variant origin of the vertebral artery

Abstract

During routine dissection, of the thoracic cavity of 70years old donated embalmed male cadaver in the Department of Anatomy, K.J. Somaiya Medical College, Sion, Mumbai, India, we observed four branches arising from the superior surface of the arch of aorta. First branch on the right side was the brachiocephalic trunk giving out its two branches – right common carotid artery and right subclavian artery. The second branch found was the left common carotid artery, the third branch was the left vertebral artery and the fourth branch was the left subclavian artery. The vertebral artery is vital to posterior cerebral circulation. The left vertebral artery of aortic origin was found to be narrower and longer as compared to the vertebral artery of subclavian origin. No other associated congenital anomaly was observed. The photographs of the variant origin of the vertebral artery were taken for proper documentation. Knowledge of a morphological variation of the left vertebral artery is considerably important for all diagnostic and surgical procedures in the head and neck region. The present case report should be of significance for clinicians with regard to vascular variations in the neck and thoracic region.

Keywords: thoracic cavity, donated, embalmed, arch of aorta, brachiocephalic trunk, left common carotid artery, left vertebral artery, left subclavian artery, variations, diagnostic & surgical procedures, clinicians, surgeons

Volume 3 Issue 6 - 2017

Sharadkumar Pralhad Sawant, Shaheen Rizvi
Department of Anatomy, KJ Somaiya Medical College, India

Correspondence: Sharadkumar Pralhad Sawant, Department of Anatomy, KJ Somaiya Medical College, 25/2, Samrat Ashok Nagar Society, Shell Colony Road, Chembur, Mumbai-400 071, Maharashtra, India, Tel 9322061220, 022-25275775, Fax 02224091855, Email drspsawant@gmail.com

Received: April 10, 2017 | **Published:** June 19, 2017

Introduction

The arch of aorta gives three branches, Brachiocephalic (Innominate) artery, Left common carotid artery & Left subclavian artery. These branches supply blood to the head, face, neck and upper limb and are significant in clinical angiography. The proximal segment of these branches and the arch of aorta are frequent sites for atherosclerosis as a result of which the blood supply to brain can be compromised. Anomalies of origin and supply of these branches can alter the haemodynamics of the brain. Vertebral artery (VA) is a major branch of subclavian artery, both in origin and distribution.^{1,2} The vertebral arteries commence at the root of the neck as the first branch from the supero-posterior aspect of the subclavian arteries. They lie medial to the scalenus anterior muscle. The two vertebral arteries are frequently unequal in size; the left being larger than the right. The vertebral arteries take a vertical posterior course to enter the foramina transversaria of the sixth cervical vertebrae on both sides, they then continue through the transverse foramina of the upper six cervical vertebrae. On emerging from the foramen transversarium of the atlas, they turn posteromedially on its posterior arch, then penetrate the posterior atlanto-occipital membrane and dura and enter the cranial cavity through the foramen magnum.³ The segment of the VA from its origin at the subclavian artery to its entry into the respective transverse foramina is called the pre transverse or pre vertebral segment.⁴ The Vertebral arteries then join each other at the caudal border of the pons to form an unpaired basilar artery. This vessel courses along the ventral aspect of the pons and distributes blood to the brain.

Case report

During routine dissection, of the thoracic cavity of a 70years old donated embalmed male cadaver in the Department of Anatomy, K.J. Somaiya Medical College, Sion, Mumbai, India, we observed four

branches arising from the superior surface of the arch of aorta. First branch on the right side was the brachiocephalic trunk giving out its two branches – right common carotid artery and right subclavian artery. The second branch found was the left common carotid artery, the third branch was the left vertebral artery and the fourth branch was the left subclavian artery. The neck and thoracic cavity was opened and structures in the superior mediastinum were dissected. The branches of the arch of aorta were traced. The pre vertebral segment of bilateral vertebral arteries were studied from the origin till the Foramen transversarium of the cervical vertebra. Arteries were assessed morphometrically using the following parameters:

Diameter was measured at the origin using sliding calipers

Length of prevertebral segment was measured for each vertebral artery using a graduated measuring metered rule. The vertebral artery is vital to posterior cerebral circulation. The left vertebral artery of aortic origin was found to be narrower and longer as compared to the vertebral artery of subclavian origin. No other associated congenital anomaly was observed. The photographs of the variant origin of the vertebral artery were taken for proper documentation. The left vertebral artery was seen ascending behind the left common carotid artery with stellate ganglion and ventral rami of cervical spinal nerves posterior to it and thoracic duct arching anterior to it before it entered the foramen transversarium of C6 vertebra. Thereafter its course was normal. The Right VA originated from the posterosuperior aspect first part of the Right subclavian artery. It traversed medially behind the common carotid artery to enter the foramen transversarium of C6 vertebra.

The diameters of the arteries were determined at their origin with the aid of sliding callipers. The lengths of the prevertebral segments of

the arteries were also measured using a graduated measuring metered rule (Figure 1). The left vertebral artery of aortic origin was found to be narrower and longer as compared to the vertebral artery of subclavian origin (Table 1).

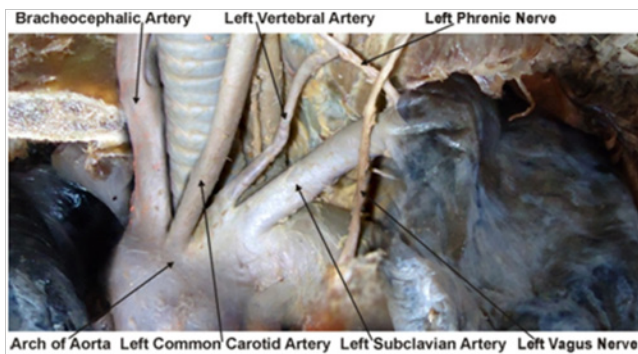


Figure 1 Photographic presentation of the origin of left vertebral artery from arch of aorta between left common carotid and left subclavian artery.

Table 1 The left vertebral artery of aortic origin was found to be narrower and longer as compared to the vertebral artery of subclavian origin

Diameter at origin	
Present case report Vertebral artery of aortic origin	3.7mm
Normal Vertebral arteries of subclavian origin	Between 5.5-6.9mm
Length of pre vertebral segment	
Present case report Vertebral artery of aortic origin	8.9cm
Normal Vertebral arteries of subclavian origin	Between 3.8cm-4.3cm

Discussion

In approximately 6% of the population the left vertebral artery arises from the arch of aorta, usually between left common carotid and left subclavian artery.⁵ The left vertebral artery usually enters the sixth cervical foramina transversaria (88%), only in 5–7% cases the left vertebral artery will enter seventh or fifth cervical vertebra.⁶ Nanthan & Seidal⁷ had reported a left vertebral artery of aortic origin associated with retroesophageal right subclavian artery and thoracic duct terminating on right side, yet with normal origin of right vertebral artery. Komiyama et al.⁸ reported the incidence of arterial dissection of the vertebral artery of aortic origin and vertebral artery of subclavian origin. According to their studies left vertebral artery of aortic origin was associated with a significantly higher incidence of vertebral artery dissection than left or right vertebral artery of subclavian origin. In our observations the diameter of left vertebral artery was 3.7mm at origin while it was 6.8mm on right side. Earlier studies by Pasturet⁹ had reported that left vertebral artery of <3.5mm diameter may be considered hypoplastic.

A vertebral artery of aortic arch origin has been earlier described by different authors in the range of 3.1-8.3% (Table 2 & Table 3). Nevertheless, most authors have stated that it is about 2.5-3%. The variant origin of vertebral artery was documented in the present case report is Lippert Pabst's Type A.

Origin point of the VA has also been reported from the thyrocervical trunk, from the brachiocephalic trunk, from the common carotid artery, from the external carotid artery, from a trunk formed by LSA and LVA.^{11–15}

Gluncic reported the length of the prevertebral segment of the left vertebral artery originating from aortic arch as 87.3mm and its diameter at the origin as 3.3mm. Panicker reported the diameter of left vertebral artery at origin was 3.1mm as compared to that of the right, which had a diameter of 6.5mm at origin. The length of prevertebral segments of right vertebral artery was 38mm and that of left vertebral artery was 92mm.¹⁶ Entry point of the LVA originating from the aortic arch, into the Foramen transversarium was also reported variable. Most common entry points were reported as C5 and C6, respectively. Overall, the most common entrance for vertebral arteries was at C6.¹⁷

Table 2 Incidence of left vertebral artery of aortic arch origin

No.	Author(year)	Incidence (%)
1	Bean (1905)	5.20%
2	Adachi (1928)	5.40%
3	Aso (1932)	3.20%
4	Mori (1941)	6.90%
5	Stein et al. ²²	6%
6	Argenson et al. (1980)	5.80%
7	Lippert Pab (1985)	3.00%
8	Nizanowski et al. (1982)	3.10%
10	Cavdar and Arisan (1989)	8.30%
11	Takafuji and Sato (1991)	6.90%
12	Vorster ²⁰	3.00%
13	Komiyama ¹⁰	2.40%
14	Panicker et al. ¹⁶	5%
15	Yamaki (2006)	5.80%

Table 3 Lippert Pabst's classified the LVA according to the origin from the aortic arch¹⁰

Type	Incidence	Site of origin
Type A	3%	Between the LCCA and LSA
Type B	<1%	Between a common trunk formed by BT and LCCA and LSA
Type C	<1%	After the LSA
Type D	<0,1%	After the LSA as the third branch
Type E	<0,1%	After a common trunk as the second branch
Type F	<0,1%	RSA appears from descending aorta
Type G	<1%	One of two roots as a penultimate branch
Type H	<0,1%	Both VA branch from the aortic arch

The lengths of the pre vertebral segments of the left vertebral artery of aortic origin were 8.9cm as compared to the vertebral artery of normal subclavian origin showing that the vertebral artery of aortic origin has a much longer course than normal which was between 3.8cm-4.3cm.

The diameter at the origin of the left vertebral artery of aortic origin were 3.7mm as compared to the diameter of the vertebral artery of normal subclavian origin showing that the vertebral artery of aortic origin has a much smaller diameter than normal which was between 5.5-6.9mm.

Embryological basis

Thirty or more branches of the dorsal aorta form the dorsal intersegmental arteries. They originate from the branchial aortic system. In the neck, the cervical intersegmental arteries unite to form a longitudinal artery on each side which develops into the vertebral artery. Most of the original links of the intersegmental arteries to the dorsal aorta disappear. Mostly the first part of vertebral artery develops from proximal part of dorsal branch of seventh cervical intersegmental artery proximal to postcostal anastomosis. The second part is derived from longitudinal communications of the postcostal anastomosis. Third part is from spinal branch of the first cervical intersegmental artery and fourth part is a continuation of third part.¹⁸

In the present case, the left sixth dorsal intersegmental artery may have persisted as the first part of vertebral artery hence left vertebral artery began from arch of aorta.

The left fourth aortic arch forms part of the arch of aorta. The proximal part of the arch develops from the aortic sac & the distal part from the left dorsal aorta. The left subclavian artery is not derived from aortic arch but from the left seventh intersegmental artery. As development proceeds, differential growth shifts the origin of the left subclavian artery cranially, subsequently it comes to be positioned in close proximity to the origin of the left common carotid artery.¹⁹

According to Vorster et al.²⁰ there are two factors that control the development of the branches of subclavian artery. First, ability of the blood to follow the longitudinal channels offering the least resistance and second, the tension on the vessels; resulting from the caudal shifting of the heart and aorta. The proximal parts of the segmental arteries are exposed to longitudinal tension and bending due to caudal shifting of the aorta resulting in retarded blood flow and abnormal connections between longitudinal channels (vertebral artery) and subclavian artery or aorta. Panicker et al.¹⁶ conceded the views of Vorster et al.²⁰ and opined that a left vertebral artery of aortic arch origin may be because of persistence of dorsal division of left 6th intersegmental artery becoming the first part of vertebral artery instead of that of left 7th dorsal intersegmental artery.

Arey²¹ is of the view that the anomalous blood vessels may be due to

- The choice of unusual paths in the primitive vascular plexus,
- The persistence of vessels normally obliterated,
- The disappearance of vessels normally retained,
- Incomplete development, and
- Fusions and absorption of the parts usually distinct.²¹

Clinical significance

A knowledge of a morphological variation of the left vertebral artery is considerably important for all diagnostic and surgical procedures such as vascular angiographies and arterial dissection as well as all non-invasive procedures in the head and neck region.²² Anomalous Vertebral Artery origin also represents a potential pitfall in diagnostic cerebrovascular injury.²³ An incomplete knowledge can result in complications. The extracranial portion of Vertebral Artery is frequently affected from atherosclerosis¹¹ and according to Fischer et al.,²⁴ the most common site of the resultant stenosis is at its origin from subclavian artery. According to Bernardi & Detori²⁵ the unusual origin of the Vertebral Artery “may favor cerebral disorders because of alterations in the cerebral haemodynamics”. According

to the literature, most patients with morphological variation of the left vertebral artery are clinically asymptomatic. Though the overall occurrence of anomalous origin of prevertebral segment of vertebral artery is low, it is of clinical importance to identify the origin and course of the prevertebral segment of the vertebral artery in detail so as to prevent complications.¹⁶ Preceding any medical procedures it is vital to gauge vascularisation of the region. The most significant benefit of detecting potential left vertebral artery origin variants is diagnostic improvements before vascular surgeries of supra aortic arteries. The knowledge is essential for planning aortic arch surgery or endovascular interventions.²² It is also of great consequence for assessing vertebro-basilar insufficiency thought to be due to atherosclerosis, and during cannulation of vertebral artery for endovascular procedures. Vitte et al.²⁶ stressed to keep the variant origin of vertebral artery in mind during its manual compression which is used routinely for positional haemodynamic vertebro-basilar insufficiency.

Conclusion

In approximately 6% of the population the left vertebral artery arises from the arch of aorta, usually between left common carotid and left subclavian artery. The left vertebral artery usually enters the sixth cervical foramina transversaria (88%), It occurs due to persistence of the left sixth dorsal intersegmental artery as the first part of vertebral artery, hence the aortic origin. A variant origin of vertebral artery of this kind may favor cerebral disorders because of alterations in cerebral haemodynamics. It is important to be aware of this rare variation in the origin and course of left vertebral artery as it might have serious implication in surgical and angiographic procedures. The knowledge is necessary and beneficial for planning aortic arch surgery or endovascular interventions.

Authors' contributions

SPS drafted the manuscript, performed the literature review & SR assisted with writing the paper.

Acknowledgements

Authors are thankful to Dean Dr. Vinayak Sabnis Sir for his support and encouragement. Authors are also thankful to Mr. M. Murugan for his help. Authors also acknowledge the immense help received from the scholars whose articles are cited and included in references of this manuscript. The authors are also grateful to authors/editors/publishers of all those articles, journals and books from where the literature for this article has been reviewed and discussed.

Conflict of interest

Author declares that there is no conflict of interest.

References

- Moore KL, Dalley AF. *Clinically Oriented Anatomy*. 4th ed. Philadelphia, New York: Lippincott Williams & Wilkins; 1999. p. 893–894.
- Hollinshead WH. Arteries: The Neck. In: *Anatomy for Surgeons*. The Head & Neck. Paul B Hoeber Inc, Medical Book Department of Harpers & Brothers, New York, USA; 1954. p. 467–474.
- Drake RL, Vogl AW, Mitchell AWM. *Gray's Anatomy for Students*. 2nd ed. New York: Edinburg-London-Melbourne, Churchill Livingstone; 2005. 976p.
- Matula C, Trating S, Tschabitscher M, et al. The course of the prevertebral segment of the vertebral artery: anatomy and clinical significance. *Surg Neurol*. 1997;48(2):125–131.

5. Koenigsberg RA, Pereira L, Nair B, et al. Unusual vertebral artery origins: examples and related pathology. *Catheter Cardiovasc Interv.* 2003;59(2):244–250.
6. Kubikova E, Osvaldova M, Mizerakova P, et al. A variable origin of the vertebral artery. *Bratisl Lek Listy.* 2008;109(1):28–30.
7. Nathan H, Seidel MR. The association of a retroesophageal right subclavian artery, a right-sided terminating thoracic duct, and a left vertebral artery of aortic origin: anatomical and clinical considerations. *Acta Anat (Basel).* 1983;117(4):362–373.
8. Komiyama M, Morikawa T, Nakajima H, et al. High incidence of arterial dissection associated with left vertebral artery of aortic origin. *Neurol Med Chir (Tokyo).* 2001;41(1):8–11.
9. Pasturet G. *Traite'd anatomic humaine: appareil circutoire (tome II, fasciula I).* Massm. Paris, France; 1958. p. 387–394.
10. Lippert H, Pabst R. Arterial Variations in Man. *Classification and Frequency.* New York: JF Bergmann Verlag Munchen; 1985:30–38.
11. Gluncic V, Ivkic G, Marin D, et al. Anomalous origin of both vertebral arteries. *Clin Anat.* 1999;12(4):281–284.
12. Mahmutyazicioglu K, Sarac K, Boluk A, et al. Duplicate origin of left vertebral artery with thrombosis at the origin: color Doppler sonography and CT angiography findings. *J Clin Ultrasound.* 1998;26:323–325.
13. Nonami Y, Tomosawa N, Nishida K, et al. Dissecting aortic aneurysm involving an anomalous right subclavian artery and isolated left vertebral artery: Case report and review of the literature. *J Cardiovasc Surg (Torino).* 1998;39(6):743–746.
14. Strub WM, Leach JL, Tomsick TA. Left vertebral artery origin from the thyrocervical trunk: a unique vascular variant. *AJNR Am J Neuroradiol.* 2006;27(5):1155–1156.
15. Yazar F, Yalcin B, Ozan H. Variation of the aortic arch branches: Two main trunks originating from the aortic arch. *Gazi Medical Journal.* 2003;14(4):181–184.
16. Panicker HK, Tarnekar A, Dhawane V, et al. Anomalous origin of left vertebral artery-embryological basis and applied aspects – A case report. *J Anat Soc India.* 2002;51(2):234–235.
17. Nayak SR, Pai MM, Prabhu LV, et al. Anatomical organization of aortic arch variations in the India: embryological basis and review. *J Vasc Bras.* 2006;5(2):95–100.
18. Keibel FN, Mall FP. Development of the vascular system. In: *Manual of Human Embryology.* Philadelphia, London: JB Lippincott Company; 1912. p. 659–667.
19. Congdon ED. Transformation of the aortic arch system during during the development of human embryo. *Contrib Embryol Carnegie Inst.* 1922;14(68):47–110.
20. Vorster W, Du Plooy PT, Meiring JH. Abnormal origin of internal thoracic and vertebral arteries. *Clin Anat.* 1998;11(1):33–37.
21. Arey LB. Development of arteries. The vascular system. In: *Developmental Anatomy. A Textbook and Laboratory Manual of Embryology.* 6th ed. Philadelphia, London: WB Saunders Company; 1957. p. 367–373.
22. Stein BM, McCormick WF, Rodriguez JN, et al. Postmortom angiography of cerebral vascular system. *Arch Neurol.* 1962;7:545–559.
23. Goray VB, Joshi AR, Garg A, et al. Aortic arch variation: a unique case with anomalous origin of both vertebral arteries as additional branches of the aortic arch distal to left subclavian artery. *AJNR Am J Neuroradiol.* 2005;26(1):93–95.
24. Fisher CM, Gore I, Obake N, et al. Atherosclerosis of the carotid and arteries—extracranial and intracranial. *J Neuropathol Exp Neurol.* 1965;24(3):244–245.
25. Bernardi L, Dettori P. Angiographic study of a rare anomalous origin of the vertebral artery. *Neuroradiology.* 1975;9(1):43–47.
26. Vitte E, Feron JM, Guerin Surville H, et al. Anatomical study of digital compression of the vertebral artery at its origin at the suboccipital triangle. *Anat Clin.* 1985;7(2):77–82.