

Congenital fusion of typical cervical vertebrae

Abstract

Developmental anomalies of the vertebral column are common especially in the cervical region and thus become the point of keen interest for a long time to the anatomists and related health professionals. Normal typical cervical vertebrae; i.e., 3rd to 6th are characterized by the presence of small body, triangular spinal canal, foramina transversarium, superior articular facet directed backwards and upward, inferior articular facet directed forward and downwards and a short bifid spine. Abnormalities in any of the features may be associated with neurological signs and symptoms. During routine osteology classes, we found two abnormally fused typical cervical vertebrae specimens in the Department of Anatomy, Desh Bhagat Dental College and Hospital, Sri Muktsar Sahib, Punjab, India. Both pairs of cervical vertebrae were unilaterally fused at the zygapophyseal joints on the right sides and in one of the case the laminae were also fused partially on the right side. Congenitally fused vertebrae results in biochemical stress in the adjoining segments of the vertebral column leading to premature degenerative change and this can lead to consequences like distal tear, spondylosis, among other problems.

Keywords: cervical vertebrae, zygapophyseal joint, congenital anomalies

Volume 2 Issue 6 - 2016

Ajitpal Singh,¹ Jeewanjot Sekhon,¹ Abhilasha,² Charanjeet Kaur³

¹Department of Anatomy, Desh Bhagat Dental College & Hospital, India

²Department of Anatomy, JCD Dental College & Hospital, India

³Department of Pharmacy & Technology, Khalsa College of Pharmacy, India

Correspondence: Ajit Pal Singh, Department of Anatomy, Desh Bhagat Dental College & Hospital, India, Tel +918437053030, Email doctoraps@gmail.com

Received: July 13, 2016 | **Published:** August 05, 2016

Introduction

There are seven cervical vertebrae numbered 1-7 from above downwards that form the basis of the bony skeleton of neck. They are small in size in comparison to thoracic and lumbar vertebrae as they have to carry less weight; and embryologically, the vertebrae develop from somites derived from paraxial mesoderm and differentiate into the sclerotome (ventro-medial part) and dermomyotome (dorso-lateral part). The sclerotome takes part in the development of the vertebral column. The mesenchymal cells from sclerotome condense to form the centrum (forms the vertebral body), vertebral arches (forms the pedicles, laminae, spine, articular process and transverse process).¹ Congenital anomalies are common in the vertebral column.² Variations in the cervical vertebrae have been recorded for many years in morphological and clinico-radiological studies. Normal typical cervical vertebrae; i.e., 3rd to 6th are characterized by the presence of small body, triangular spinal canal, long and narrow lamina, foramen transversarium, superior articular facet directed backwards and upwards, inferior articular facet directed forwards and downwards and short bifid spine.³ Abnormalities in any of the features may be associated with neurological signs and symptoms of clinical importance. Yin et al.⁴ analyzed 87 cases with fused cervical vertebrae at C2-C3 and C3-C4 without any malformation, but Erdil et al.⁵ reported neck pain, muscular weakness of both upper limbs and minor (but intermittent) head and neck pain. The present study was designed to highlight the osteological variation and its clinical correlation for preventing serious complication, misdiagnosis and early treatment.

Material and methods

During the routine osteology classes for BDS 1st year students in the Department of Anatomy at Desh Bhagat Dental College and Hospital, Sri Muktsar Sahib, Punjab, India - we came across two pairs of abnormally fused typical cervical vertebrae. The fused vertebrae were studied along with the normal typical vertebrae and were analyzed and photographed from different aspects.

Observations

Figure 1 shows the features of normal typical cervical vertebra. Based on observations, details of the abnormally fused typical cervical vertebrae were as follows:

- i. The cervical vertebrae of both the specimens I and II were fused at the zygapophyseal joint on the right side (Figure 2a) (Figure 2b) (Figure 3a) (Figure 3b).
- ii. In specimen I, the lamina and spinous process of upper and lower cervical vertebrae were also fused on the right side but it was not found in the specimen II (Figure 2a) (Figure 2b) (Figure 3a) (Figure 3b).
- iii. In specimen I, the groove for the spinal nerve was also narrow on the right side (Figure 2c).



Figure 1 Normal typical cervical vertebra.

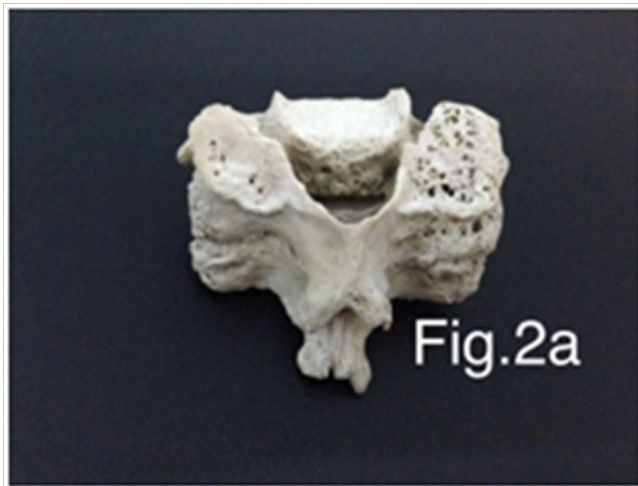


Figure 2a Specimen I (above view).

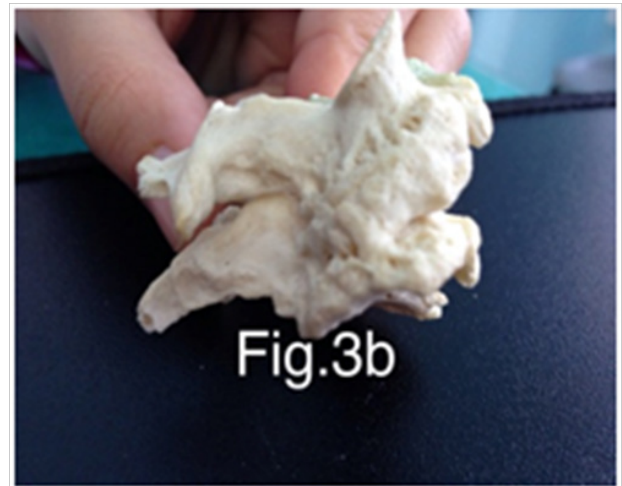


Figure 3b Specimen II (Postero-Lateral View) showing fusion at the zygapophyseal joint on the right side.

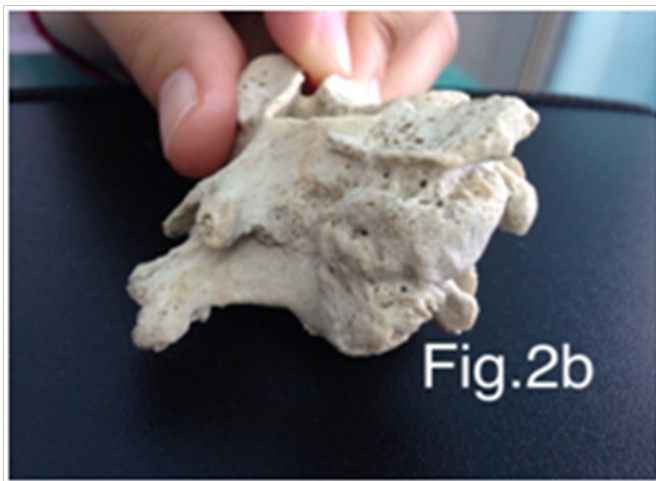


Figure 2b Specimen I (Postero-Lateral View) showing fusion at the zygapophyseal joint on the right side as well as the lamina and spinous process are also fused.

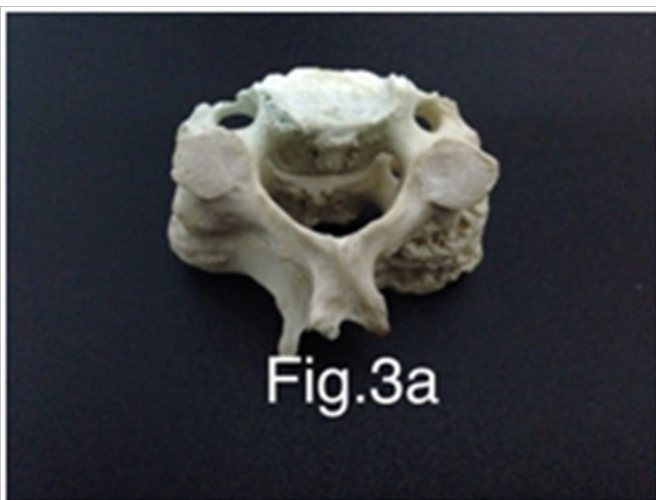


Figure 3a Specimen II (Above View).

Discussion

Congenitally fused cervical vertebrae is one of the primary malformations associated with chorda dorsalis⁶⁻⁸ that is believed to be due to defects taking place during the development of the occipital and cervical somites.⁹⁻¹¹ It is caused because of the combination of environmental and genetic factors which occur during the 3rd week of pregnancy.¹² Its diagnosis is complex in young age because it may give the appearance of a normal disc area, as the ossification of the vertebral body is not complete till adolescence and the cartilage is also not ossified.¹³ It is important to differentiate between a pathologic condition from it being congenitally-fused cervical vertebrae or acquired.^{14,15} The later can be associated with conditions like tuberculosis, juvenile rheumatoid arthritis and trauma¹⁶ and even with Klippel-Fiel Syndrome.¹⁷ In the congenitally-fused vertebrae, the antero-posterior diameter of the vertebra is decreased and the individual measurement of the two vertebrae bodies' height is equal to the two fused vertebrae height, including the inter-vertebral disc.

Though the fusion may appear silent, but in advanced age it causes degenerative changes in non-segmented cervical regions and also leads to development of hypermobility and degenerative arthritis above and below the fused cervical region, webbed neck, kyphosis, torticollis, compression of nerve roots resulting in hypoesthesia and paralysis of the concerned parts of the body. Early diagnosis can help in the prevention of degenerative process by motivating the patients to change their lifestyle. For instance, they can avoid undue trauma, extension and rotational maneuvers which may place the spinal cord and vertebral artery at risk.¹⁸ In both specimens examined, the vertebrae were fused on the right side at the zygapophyseal joint on the right side and in specimen II the groove for spinal nerve was reduced in size, so it may lead to compression of nerve roots-resulting into hypoesthesia and paralysis of the concerned parts of the body. Thus, diagnosis of congenital fusion of C2-C3 is helpful in treating and managing the related complicated outcomes yet to be appeared and its knowledge can further assist in planning the surgeries of head and neck.

Acknowledgements

None.

Conflict of interest

Author declares that there is no conflict of interest.

References

1. Singh Vishram. *Anatomy of Head, Neck & Brain Elsevier*. New Delhi, India; 2009:44–47.
2. Romanes GJ. *Cunningham's Text book of Anatomy*. 12th ed. Oxford: Oxford university press; 1981:90–98.
3. Tiwari A, Chandra N, Neeresh M, et al. congenital abnormal cervical vertebrae -A case report. *J Anat Soc*. 2002;51:88–89.
4. Yin HP, Yang KQ, Lou SQ. Clinical significance of congenital fusion of cervical vertebrae: a case report of 87 cases. *Zhonghua Wai Ke Za Zhi*. 1989;27(2):75–77.
5. Erdil H, Yildiz N, Cimen M. Congenital Fusion of Cervical Vertebrae and its Clinical Significance. *J Anat Soc India*. 2003;52(2):125–127.
6. Meschan I. *Analysis of roentgen signs in general radiology*. Philadelphia: WB Saunders Company; 1973;1:618–620.
7. Besnick D, Niwayama G. *Diagnosis of bone and joint disorders*. 2nd ed. WB Saunders Company; 1985;5:1081–1083.
8. Sutton D. *Textbook of radiology and medical imaging*. 5th ed. Edinburgh: Churchill Livingstone; 1993;1:12.
9. Dunsker SB, Brown O, Thompson N. Craniovertebral anomalies. *Clinical Neurosurgery*. 1980;27:430–439.
10. Sandler TW. *Langman's medical embryology*. 6th ed. Baltimore: Williams and Wilkins; 1990:151–153.
11. Chandraj S, Briggs CA. Failure of somite differentiation at the craniovertebral region as a cause of occipitalization of the atlas. *Spine*. 1992;17(10):1249–1250.
12. Bethany MU, Mette NC. A sequential developmental field of the vertebrae, ribs and sternum in a young woman of the (12th century AD). *American Journal of Physical Anthropology*. 2000;111:355–367.
13. Gray SW, Romaine CB, Skandalakis JE. Congenital fusion of the cervical vertebrae. *Surgery Gynecology Obstetrics*. 1964;18:373–385.
14. Graaf R. Congenital block vertebrae C2-3 in patients with cervical myelopathy. *Acta Neurochirurgica*. 1982;61(1–3):111–126.
15. Ericson LC and Greer RO. Ponticuluc, an anomaly of the first cervical vertebra as on the cephalometric head film. *Oral Surgery Oral Medicine and Oral Pathology*. 1984;57(2):230.
16. Resnick D. *Additional congenital or heritable anomalies and syndromes*. In: Bone and joint imaging. WB Saunders company; 1992;2:1071–1091.
17. Nagashima H, Morio Y, Teshima R. No neurological involvement for more than 40years in Klippel-Feil syndrome with severe hyper mobility of the upper cervical spine. *Archives of orthopedic Trauma Surgery*. 2001;121(1–2): 99–101.
18. Soni P, Sharma V, Sengupta J. Cervical vertebral anomalies: Incidental findings on lateral cephalograms. *Angle Orthod*. 2008;78(1):178–180.