

Variation of the musculocutaneous nerve: a case report

Abstract

In normal individuals the Musculocutaneous nerve is terminal branch of the lateral cord of the brachial plexus. During routine dissection conducted for undergraduates study in the Department of Anatomy, Tehran medical college, the Musculocutaneous nerve was found variation and two roots of median nerve have united and median nerve innervated muscles in one adult Iranian woman cadaver. In others words, Variations in the origins and distributions of the brachial plexus had been documented by previous researcher. Variations in the origin course, branching pattern, termination and connection of the Musculocutaneous nerve are not uncommon. Knowledge of these variations is important to the anatomist, orthopaedicians, neurologist and anesthetist.

Keywords: musculocutaneous nerve, variation, median nerve

Volume 1 Issue 4 - 2015

Arian Azimi,¹ Hossein Eyni,¹ Sadegh Ghorbani,¹ Parichehr Pasbakhsh²

¹Anatomical Sciences Department, Tarbiat Modares University, Iran

²Department of Anatomy, University of Tehran, Iran

Correspondence: Parichehr Pasbakhsh, Department of Anatomy, University of Tehran, Iran, Tel + 98(912)2249612, Email pasbakhsh@hotmail.com

Received: October 26, 2015 | **Published:** November 06, 2015

Introduction

The brachial plexus variations have been noted by other authors. It should be reported that the brachial plexus is the most variable portion of the peripheral nervous system.¹ The spread of variations ranges from 12.8 up to 53.^{1,2} The Musculocutaneous nerve is emerged from the lateral root of the brachial plexus and its nerve to muscles the biceps brachii, coracobrachialis, and the brachialis. This nerve supplies the lateral margin of the skin of the forearm. After the Musculocutaneous nerve is emerge from the lateral cord to innervate the muscles, the lateral cord continues as a lateral root of the median nerve, joining with the medial root at level of the distal margin of the pectoral minor muscle in front of the axillary artery. Any the muscle branch of the median nerve does not have in the arm. Variation of the Musculocutaneous nerve may occur in 6.25% cases³ and its absence has been reported with a prevalence ranging from 1.7 to 15%.⁴ Absence of the Musculocutaneous nerve has been described in many report.^{5,6} Prasad Rao et al.⁷ reported that the Musculocutaneous nerve was found to be absent.⁷ Buch Hansen⁸ reported these variation in 65% of the population. In this case, we observed the variation of the Musculocutaneous nerve with innervations of the anterior compartment of the muscle of the arm by the lateral root of the median nerve.

Case report

During a routine dissection of an old woman cadaver at the department of anatomy, Tehran University of medical science in Tehran-Iran, a variation of brachial plexus was observed in both arms. This paper reports on a variation of the Musculocutaneous nerve, in which its area of innervations was supplied by median nerve. First, the lateral cord of brachial plexus gives off a Musculocutaneous nerve. It was small and thin and it needed to look carefully to find it in the macroscopic dissection. The nerve emerged immediately from the head of coracobrachialis muscle. Then the lateral root continued as the lateral root of the median nerve. When the median nerve was formed, the muscular branch to the brachialis, the biceps brachii is innervated directly from the median nerve. In others words, the second branch emerged from the median nerve, it is close to the caudal extremity of the coracobrachialis muscle. It divide to two branches, one of them is

emerge in the middle of the arm and is innervate the biceps brachii. The length of the nerve was 5cm and finally other nerves emerge to innervate the brachialis. This nerve is long and the length of the nerve is 10cm. This branch is descend over on brachial artery and between the biceps brachii and brachialis muscles and come to the lateral margin of the forearm and then it descend over brachioradialis muscle as the lateral cutaneous nerve of forearm (Figure 1). This variation was present both upper limb. In the left upper limb, the brachial plexus is similar to right hand.

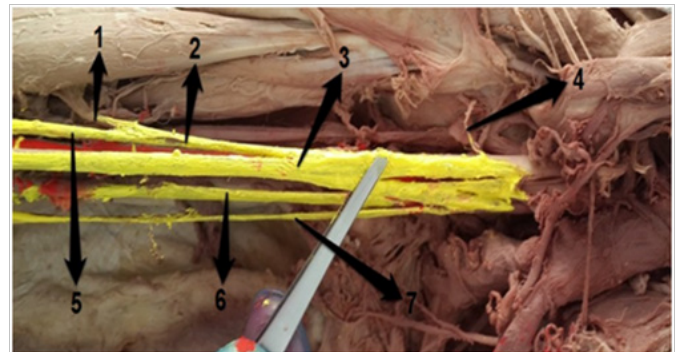


Figure 1 Innervation of arm region.

- 1, Nerve to biceps brachii muscle
- 2, Accessory branch
- 3, Median nerve
- 4, Musculocutaneous nerve
- 5, Nerve to brachial muscle
- 6, Ulnar nerve
- 7, Medial cutaneous nerve of forearm

Discussion

The Musculocutaneous nerve is organized by motor- sensory fibers coming from the primary ventral branches of the C5 to C7 spinal nerve. After emerging from the lateral fasciculus, it heads towards the coracobrachialis muscle, which it penetrates, and continues

deeply among the brachialis and biceps brachii muscles, to innervate all three of these muscles. Close to the cubital fossa, it comes to the surface laterally to the biceps brachii muscle and anteriorly to the brachialis muscle, and becomes known as the lateral cutaneous nerve of forearm. Then it descend along the lateral margin of the forearm and gives cutaneous braches to the lateral surface of the forearm.⁹ The embryological development of the upper limb may help in describing this anatomical variation. Mesenchymal, which comes from the dorsal lateral part of the somites, immigrates and forms the muscles into the limb bud. At the same time, the mesenchymal penetrated by the ventral primary rami of the suitable spinal nerves, located opposite to the bud. Contact between nerves and muscle cells are essential to provide mesenchymal condensation to form muscles. Nerves supplying the limbs are joined by connecting loops of the nerve fiber to form plexuses. The median nerve is formed by a combination of ventral segmental branches and Musculocutaneous nerve arises from it. Disturbances in three process, taking place in the 4th-7th weeks of development lead to anatomical variation in the innervations of the muscles by appropriate nerves.^{4,10} In accordance with this, absence of the Musculocutaneous nerve is noted meaning that this nerve did not emerged from the median nerve, thus its fibers came from median nerve.¹¹ Absence of the Musculocutaneous nerve does not lead to paralysis of the flexor musculature of the elbow and hypotheses of the lateral surface of the forearm, because the motor and sensitive fibers can arise from other nerves. The most common situation is that is fibers originate from the median nerve or less from the lateral root of the brachial plexus.¹¹⁻¹³ Thus, this anatomical variation has no clinical appearance and it is unlikely to be identified until a dysfunction of some of the nerve mentioned above appears. It is important for surgeons, clinicians and anatomists to be aware of possible anatomical variation to avoid unexpected complication.

Acknowledgements

None.

Conflict of interest

Author declares that there is no conflict of interest.

References

1. Elizabeth Johnson O, Marios Vekris, Theano Demesticha, et al. Neuroanatomy of the brachial plexus: normal and variant anatomy of its formation. *Surgical and Radiologic Anatomy*. 2010;32(3):291-297.
2. Pandey SK, Shukla VK. Anatomical variations of the cords of brachial plexus and the median nerve. *Clin Anat*. 2007;20(2):150-156.
3. Bhattarai C, Poudel PP. Unusual variation in musculocutaneous nerves in Nepalese. *Kathmandu Univ Med J (KUMJ)*. 2009;7(28):408-410.
4. Rodriguez-Niedenfuhr M, Vázquez T, Choi D, et al. Supernumerary humeral heads of the biceps brachii muscle revisited. *Clin Anat*. 2003;16(3):197-203.
5. Le Minor JM. A rare variation of the median and musculocutaneous nerves in man. *Arch Anat Histol Embryol*. 1990;73:33-42.
6. Nakatani T, Tanaka S, Mizukami S. Absence of the musculocutaneous nerve with innervation of coracobrachialis, biceps brachii, brachialis and the lateral border of the forearm by branches from the lateral cord of the brachial plexus. *J Anat*. 1997;191(3):459-460.
7. Prasada Rao PV, Chaudhary SC. Communication of the musculocutaneous nerve with the median nerve. *East Afr Med J*. 2000;77(9):498-503.
8. Buch-Hansen K. Variations of the median nerve and the musculocutaneous nerve and their connections. *Anat Anz*. 1995;102(9-14):187-203.
9. Williams PL, Dyson M, Bannister LH. *Gray's anatomy*. 1989.
10. Uzun A, Seelig LL Jr. A variation in the formation of the median nerve: communicating branch between the musculocutaneous and median nerves in man. *Folia Morphol (Warsz)*. 2001;60(2):99-101.
11. Song WC, Jung HS, Kim HJ, et al. A variation of the musculocutaneous nerve absent. *Yonsei Med J*. 2003;44(6):1110-1113.
12. Aydin ME, Kale A, Edizer M, et al. Absence of the musculocutaneous nerve together with unusual innervation of the median nerve. *Folia Morphol (Warsz)*. 2006;65(3):228-231.
13. Tatar I, Brohi R, Sen F, et al. Innervation of the coracobrachialis muscle by a branch from the lateral root of the median nerve. *Folia Morphol (Warsz)*. 2004;63(4):503-506.