

Comparison of ayoub shklar stain and routine haematoxylin and eosin stain for the keratin identification in kcot—a pilot study

Abstract

Aim: The aim of the present study was to compare the efficacy of special stains for keratin with standard H and E stain.

Objectives: i. To subject the diagnosed cases of keratin disorders to the selected special stains: Ayoub-shklar method. ii. To compare the staining specificity and staining intensity of special stains with respect to routine hematoxylin and eosin (H and E) stain.

Keratins are the most abundant proteins and are characteristic findings in many epithelial pathologies, making it diagnostically important marker, both histopathologically and immunohistochemically. Since, immunohistochemistry is an expensive diagnostic tool, special stains to detect the degree of keratinization could serve as a faster and economic option. The aim of the present study was to compare the efficacy of special stains for keratin with standard hematoxylin and eosin stain (H and E).

Volume 4 Issue 3 - 2018

Aiman Zafar, Pratibha Ramani, Anuja N, Herald J Sherlin, Gheena, Abhilasha R, Giffirina Jayaraj, Don KR

Department of Oral & Maxillofacial Pathology, Saveetha University, India

Correspondence: Aiman zafar, Department of Oral & Maxillofacial Pathology, Saveetha Dental College, Saveetha University, 162, Poonamalle High Road, Chennai -600077, Tamil Nadu, India, Email aimanzafar946@gmail.com

Received: November 13, 2017 | **Published:** June 27, 2018

Introduction

Keratins are one of the major and key structural proteins, found at their highest concentration and diversity in the keratinocytes of cutaneous as well as oral epithelium and accounts for almost 80% of the total protein content in differentiated cells of stratified epithelia. In the 1900s, keratins were believed to be the proteins, which could be extracted from the various epidermal modifications of animals such as wool, horns, claws, etc.^{1,2} Subsequently, with advancement in research and advent of 21st century technologies, keratin (cytokeratins) are now considered as intermediate filament proteins with specific physicochemical properties, found in any vertebrate epithelia.² They are part of the multi-gene family of proteins, occurring in basic and acidic protein pairs with varied expression pattern in different types of epithelia, as well as different layers of a single stratified epithelium. The main function of cytokeratins along with microtubules and microfilaments is to provide with structural integrity and mechanical resiliency to all the eukaryotic cells. The oral epithelium can be categorized into keratinized stratified epithelia (ortho and parakeratinized) and non-keratinized epithelia based on the presence or absence of keratinization. Keratinization or cornification involves the process of cytodifferentiation of the keratinocytes, starting from their post formative state, i.e., stratum basale to the final differentiated state of toughened cornified cells filled with keratin filaments found in the surface layer, i.e., stratum corneum.

Materials and methods

A total 5 paraffin embedded block collected of KCOT cases which previously diagnosed, 2 slides has been taken from each block and proceed with dewax and stain it one set of slide stain with ayoub shklar stain and other set of slide with HE stain.

Preparation of ayoub shklar stain

- i. 5% acid fuchsin solution
 1. Acid fuchsin 5gm
 2. Distilled water 100ml
- ii. Aniline blue 0.5gm
 3. Orange G 2gm
 4. Phosphotungstic acid 1gm
 5. Distilled water 100ml

Staining procedure

The sections were deparaffinized in xylene for 5min each.

- a) Later dehydrated in various grades of alcohol i.e. 90% and 70% and water washed for 10min
- b) Acid fuchsin solution was added for 3min
- c) Aniline blue OG was added directly to the sections for 30min
- d) Sections were transferred to 95% alcohol – 2 changes
- e) Sections were dehydrated, cleared and mounted

Results

(Figure 1)

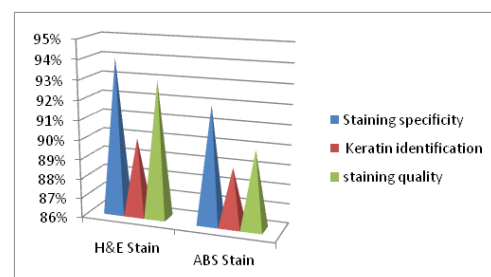


Figure 1 Graph represent the staining specificity, keratin identification and staining quality in ayoub shklar stain and H&e stain.

Discussion

The oral epithelium represents the primary barrier between oral environment and the deeper tissues. It is lined by stratified squamous epithelium and consists of cells tightly attached to one another and arranged in a number of distinct layers or strata. It maintains its structural integrity by a system of continuous cell renewal.¹

The epithelial surface of the masticatory mucosa, such as that of the hard palate and gingival is flexible, tough and resistant to abrasion. This is caused by the formation of a surface layer of keratin and the process of maturation is called keratinization. Keratin constitutes the major component of cytoskeleton of all epithelia and provides a mechanical support for the cells and nucleus.³

Special stains are the stains that are used to visualize specific tissues and cellular structures. These are the dyes that bind to the cellular components either physically or by chemical bonds. Ayoub-Shklar, Dane Herman method,² Schiff's reagent by oxidation with performic acid¹ are all special histochemical stains used to stain keratin specifically. These stains may highlight small foci of overt epithelial differentiation that sometimes is missed in routine H-E staining.

In this study shows that ayoub shklar stain has good specificity 89% whereas in H&E Stain shows 92% there is not much variation seen. Keratin plays an important role as a marker protein in establishing a definitive histological diagnosis, like for e.g.; in grading of squamous cell carcinoma,² to differentiate between the epithelial and mesenchymal tumors and in certain conditions like when the epithelial component may be sparse and may be identified only by the presence of keratin reactivity.

Keratin identification found in ayoub shklar stain 86%, in this study we found only parakeratinised, and in H&E Stain identified keratin about 89%. The staining quality of the ayoub shklar stain 90% and in H&E Stain 93% even in this parameter not much variation found.

Odontogenic keratocyst is a developmental cyst derived from the dental lamina, which in turn is a derivative of oral ectoderm. As

the name suggests, keratin is formed to a large extent in OKC. The cystic epithelium is lined by a regular keratinized stratified squamous epithelium, which are usually 5-8 cell layers thick with palisaded basal layer and without rete pegs. The form of keratinization is exclusively parakeratinized in about 80-90% but sometimes orthokeratinized or both forms are found in different parts of some cyst.⁴

Conclusion

The present study, to the best of our knowledge, H-E, and ayoub shklar stain for keratin. Hence, our study adds to the limited literature on application on paraffin embedded tissue sections and it is comparable to Ayoub shklar stain and H-E stain to stain surface keratin.

Ayoub shklar stain has good staining specificity, keratin also identified in this stain and has good staining quality, but still furthermore studies required to prove.

Acknowledgements

None.

Conflict of interest

The author declares that there is no conflict of interest.

References

1. Presland RB, Dale BA. Epithelial structural proteins of the skin and oral cavity: function in health and disease. *Crit Rev Oral Biol.* 2000;11:383–408.
2. Elzay RP. A modification of Papanicolaou exfoliative cytology stain to demonstrate keratin in paraffin-block tissue sections. *Oral Surg Oral Med Oral Pathol.* 1983;56(1):51–53.
3. http://en.wikipedia.org/wiki/Papanicolaou_stain.
4. http://en.wikipedia.org/wiki/Orange_G