

# Bilateral Sever's disease – An uncommon finding

## Abstract

Calcaneal apophysitis is a common cause of heel pain in children and is also known as Sever's disease. Rarely causes important disability and is transient in most of the times, but it can interfere with walking and physical performance in sports, causing concern to the patient and parents. It is the most common cause of heel pain in the physically active growing children—8-25 years-old—and is considered a benign, self-limiting condition of childhood and adolescence. Boys constitute two-thirds of the patients and the sport that tends to dominate is soccer. The diagnosis of calcaneal apophysitis is usually made with a typical history and physical examination. Pain with activity, especially running and jumping, and a positive “squeeze test”: pain is produced by medial and lateral compression of the heel where the calcaneal apophysis attaches to the main body of the calcaneus. Children with Sever's disease don't have growth disturbances in the calcaneal apophysis or any vary in bone density compatible with a necrotic or a repair process. Children with Sever's disorder respond variably, poorly, or not at all to anti-inflammatory drugs. Heel cup fixating the heel pad provided better pain relief in young boys with Sever's injury compared with the traditional heel wedge.

**Keywords:** calcaneus/diagnostic imaging, calcaneus/pathology, child

Volume 8 Issue 2 - 2018

Márcio Luís Duarte, Bruno Fernandes Barros Brehme de Abreu, Maura Harumi Ito, Maria Gabriela Varandas Costa, José Luiz Masson de Almeida Prado, Marcelo de Queiroz Pereira da Silva

Radiology, Webimagem, São Paulo, Brazil

**Correspondence:** Márcio Luís Duarte, Webimagem, Avenida Marquês de São Vicente 446, São Paulo, Brazil, Email marcioluisduarte@gmail.com

**Received:** November 24, 2017 | **Published:** April 19, 2018

**Abbreviation:** MRI: Magnetic resonance imaging

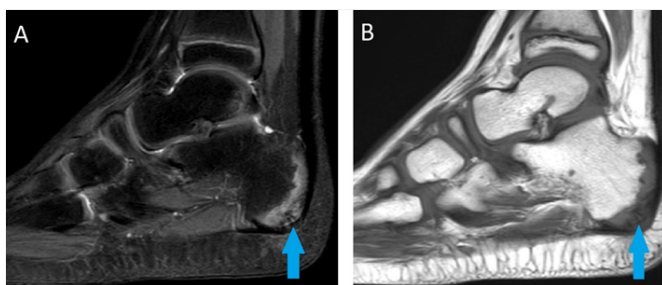
## Introduction

Calcaneal apophysitis is a common cause of heel pain in children and is also known as Sever's disease.<sup>1,2</sup> Rarely causes important disability and is transient in most of the times, but it can interfere with walking and physical performance in sports, causing concern to the patient and parents.<sup>1</sup> It is the most common cause of heel pain in the physically active growing children—8-25 years-old—and is considered a benign, self-limiting condition of childhood and adolescence.<sup>2-4</sup> Boys constitute two-thirds of the patients and the sport that tends to

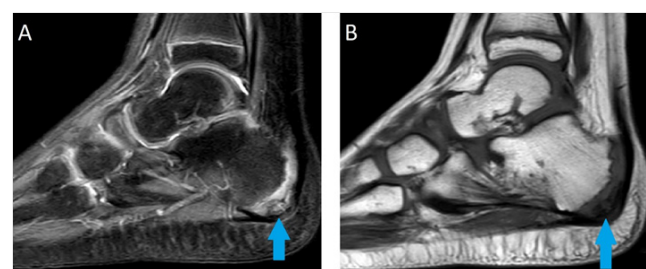
dominate is soccer.<sup>5</sup> Sever's disease is a chronic (repetitive) injury to the actively remodeling trabecular metaphysical bone that results in a variably sized stress injury with concomitant trabecular micro failure, hemorrhage, and edema, which is evident on MRI.<sup>4</sup>

## Case presentation

8 years-old boy with pain in the heel of both feet for three months. The pain started when they started to play basketball. Deny traumas and surgeries. Indicates pain at local palpation and walking. MRI demonstrated irregularity of calcaneal apophysis with important edema, corresponding to Sever's disease, with discrete edema of surrounding subcutaneous tissue, in both feet (Figure 1) (Figure 2).



**Figure 1** Sagittal MRI of the right foot in T2 SPIR sequence in A and T1 sequence in B demonstrating irregularity of calcaneal apophysis with important edema, corresponding to Sever's disease (blue arrow).



**Figure 2** Sagittal MRI of the left foot in T2 SPIR sequence in A and T1 sequence in B demonstrating irregularity of calcaneal apophysis with important edema, corresponding to Sever's disease (blue arrow).

## Discussion

The diagnosis of calcaneal apophysitis is usually made with a typical history and physical examination.<sup>2</sup> Pain with activity, especially running and jumping, and a positive “squeeze test”: pain is produced by medial and lateral compression of the heel where the calcaneal apophysis attaches to the main body of the calcaneus.<sup>3,5</sup> Foot x-rays are performed as part of the clinical evaluation in routine orthopedic practice.<sup>2</sup> Increased density and fragmentation of the

calcaneal apophysis are the two radiologic signs that are postulated to be noticeable differences between the radiographs of children with calcaneal apophysitis compared with their asymptomatic counterparts.<sup>2</sup> However, density of the calcaneal apophysis cannot be used as a pathognomic finding.<sup>2</sup> Fragmentation should not be misinterpreted as an abnormality; rather, it should be accepted as a normal variant.<sup>2,5</sup> Furthermore, x-ray can be normal in Sever's disease.<sup>4</sup> X-rays can be used to rule out other causes of heel pain

in children such as a bone cyst, osteoid osteoma, stress fractures or tarsal coalition.<sup>2,3,6</sup> Lateral radiographs alone are sufficient to rule out other pathology and additional orthogonal views are unnecessary for screening purposes, thereby reducing radiation exposure and cost.<sup>3</sup> MRI will show edematous changes within the calcaneal apophysis, possibly extending into the adjacent calcaneal tuberosity.<sup>6</sup> Moreover, in equivocal cases, MRI can be helpful in rule out other diseases of heel pain.<sup>6</sup> Children with Sever's disease don't have growth disturbances in the calcaneal apophysis or any vary in bone density compatible with a necrotic or a repair process.<sup>1</sup> Children with Sever's disorder respond variably, poorly, or not at all to anti-inflammatory drugs.<sup>4</sup> Heel cup fixating the heel pad provided better pain relief in young boys with Sever's injury compared with the traditional heel wedge.<sup>5</sup>

### Acknowledgement

Not applicable

### Conflict of interest

The authors declare that there is no conflict of interests regarding the publication of this paper.

### Patient consent

The written informed consent of the patient was obtained, for the publication of her case.

### References

1. Volpon JB, de Carvalho Filho G. Calcaneal apophysitis: a quantitative radiographic evaluation of the secondary ossification center. *Arch Orthop Trauma Surg.* 2002;122(6):338–341.
2. Kose O, Celiktas M, Yigit S, et al. Can we make a diagnosis with radiographic examination alone in calcaneal apophysitis (Sever's disease)? *J Pediatr Orthop B.* 2010;19(5):396–398.
3. Rachel JN, Williams JB, Sawyer JR, et al. Is radiographic evaluation necessary in children with a clinical diagnosis of calcaneal apophysitis (sever disease)? *J Pediatr Orthop.* 201;31(5):548–450.
4. Ogden JA, Ganey TM, Hill JD, et al. Sever's injury: a stress fracture of the immature calcaneal metaphysis. *J Pediatr Orthop.* 2004;24(5):488–492.
5. Perhamre S, Lundin F, Norlin R, et al. Sever's injury; treat it with a heel cup: a randomized, crossover study with two insole alternatives. *Scand J Med Sci Sports.* 2011;21(6):e42–47.
6. Lawrence DA, Rolen MF, Morshed KA, et al. MRI of heel pain. *American Journal of Roentgenology.* 2013;200(4):845–855.