

Rhino-orbito-cerebral mucormycosis (black fungus) in covid 19 patients in western Uttar pradesh India

Abstract

Mucormycosis (Black fungus) is a designated as a rare, rapidly progressive fatal disease of immunocompromised caused by saprophytic fungus of family mucorales. Early diagnosis with prompt medical and surgical treatment is the only tool available. Rhino-orbito-cerebral is the most common subtype. In India we saw a sudden rise in mucormycosis cases during second wave of COVID 19. This necessitated a systematic review of epidemic of mucormycosis in COVID 19. A Retrospective multi-centric study was conducted comprising of 51 cases of Rhino-orbito-cerebral mucormycosis with present or recent COVID19 in Western Uttar Pradesh positive status presenting to us during 14th April 2021- 31st May 2021. Either Type2 Diabetes Mellitus or history of recent use of steroids in high doses was present in all the patients. Contribution of virulence of the Delta strain B.1.617.2 is significant. FESS with sino-nasal debridement contributes significantly towards mortality reduction and cost of total treatment by significantly reducing days of Liposomal Amphotericin B therapy. Early diagnosis with prompt medical and surgical management along with blood sugar control and avoiding use of high dose of steroids remain to key to mortality and morbidity reduction.

Keywords: black fungus, mucor, mucormycosis, rhino-orbito-cerebral, causes, treatment, covid 19, india, sugar, steroids, steam, oxygen, surgery

Volume 13 Issue 3 - 2021

Keshav Gupta,¹ Mohit Srivastava,² Veenita Singh³

¹Senior Resident ENT, GSMCH, India

²Professor & Head ENT, GSMCH, India

³Professor Oral & Maxillo-Facial Surgeon, Dy Patil University, India

Correspondence: Dr. Mohit Srivastava, Professor & Head ENT, GSMCH, Hapur, House No 1153, 2nd Floor, Sector -5 Mohan Meekins Society Vasundhara, Ghaziabad, India, 201012, Tel +91 9999556665, ORCID 0000-0003-3249-9697, Email dr.mohit141180@gmail.com

Received: September 15, 2021 | **Published:** October 05, 2021

Introduction

Mucormycosis are a group of invasive infections caused by filamentous fungi of the Mucoraceae family.¹ It is the third invasive mycosis in order of importance after candidiasis and aspergillosis.² The incidence of mucormycosis is approximately 1.7 cases per 1000000 inhabitants per year, and the main risk-factors for the development of mucormycosis are ketoacidosis (diabetic or other), iatrogenic immunosuppression, use of corticosteroids or deferoxamine, disruption of mucocutaneous barriers by catheters and other devices, and exposure to bandages contaminated by these fungi.²

Rhino-orbito-cerebral is the most common clinical subtype of disease. Mucormycosis is a difficult to diagnose rare disease with high morbidity and mortality.³ This form presents with sinusitis, facial and eye pain, proptosis, progressing to signs of orbital structure involvement.^{4,7} Necrotic tissue can be seen on nasal turbinates, septum and palate. This may look like a black eschar.^{7,8} Intracranial involvement develops as the fungus progresses through either the ophthalmic artery, the superior fissure, or the cribiform plate.^{4,7}

Diagnosis of mucormycosis rests upon the presence of predisposing conditions, signs and symptoms of disease, observation of fungal elements of specific morphology in histological sections, and direct smears of material, and, to a lesser extent, culture results.^{6,7} There are no reliable serological tests for diagnosis at present.⁸ The incidence of mucormycosis has risen more rapidly during the second wave compared with the first wave of COVID 19 in Western Uttar Pradesh India, with at least 28,252 mucormycosis cases on 7th June 2021. 86% of them are known to have history of COVID 19 and 62.3% of them are known to be diabetic.⁹

Aim

To study various risk factors, clinical features, diagnosis, treatment and outcome of mucormycosis patients during second wave of COVID 19 in Western Uttar Pradesh India.

Study design

Multi-centric Retrospective.

Sample size

No of cases- 51

Study period- 14th April 2021- 31st May 2021.

Inclusion criteria

All the following criteria was satisfied

Patient presented during 14th April 2021 midnight- 31st May 2021 midnight.

COVID 19 RT PCR positive at any time during the study period or within 28 days before beginning of study period.

Biopsy proven mucormycosis and/or patient had features clinically consistent with diagnosis of mucormycosis, that is, two or more of following on presentation:

Black eschar within oral cavity and/or blackish eschar within nasal cavity and/or blackish eschar over face.

Severe facial pain and facial swelling of onset within last 28 days.

Eye swelling and/or ptosis and/or proptosis.

Computerised tomography or magnetic resonance and imaging suggestive of invasive fungal rhinosinusitis.

Exclusion criteria

Oral and sino-nasal malignancies, other conditions associated with oro-mucosal ulcerations, absence of present or recent COVID 19 status.

Material and methods

After all inclusion and exclusion criteria were satisfied, records were checked for presence and absence of various predisposing factors, treatment offered, histopathology reports, surgeries performed and outcome. All the data was gathered and tabulated in Microsoft Excel 2008 spreadsheet. SPSS 24 was used for statistical calculations. Results were systemized and summarized.

Observations

(Tables 1.1-1.6), (Images 1.1-1.3).

Table 1.1 Sex distribution of cases

Sex	No of cases
Male	28
Female	23
Total	51

Table 1.2 Age distribution of cases

Age distribution	No of cases
Less than 31	2
31-45	22
46-60	18
More than 60	9
Total	51

Table 1.3 COVID status of patients

COVID Status	No of cases
Active COVID	25
Post COVID	26
Total	51

Table 1.4 Various Risk Factors for mucormycosis with Delta stain of COVID 19 noted in our study

Risk factor	No of cases	Association
Diabetic	43	Strong
Recent history of Steroids	49	Strong
Either Diabetes or steroids	51	Definitive
Oxygen support	16	Weak
History of Tocilizumab	zero	Can not comment
Steam inhalation more than one hour a day	1	Absent

Table 1.5 Clinical features in 51 patients of Mucormycosis with COVID 19

Clinical feature	No of cases	Frequency
Eye swelling	34	66.67
Diminished vision	29	56.86
Ptosis	28	54.9
Black eschar	25	49.02
Facial swelling	23	45.1
Proptosis	18	35.29
Facial pain	16	31.37
Loss of vision	11	21.57
Nasal discharge	8	15.69
Nasal bleed	4	7.84
Altered sensorium	1	1.96

Table 1.6 Outcome in 51 patients of Mucormycosis with COVID 19

Outcome	No of patients	Frequency
Recovered during study period	18	35.29
Survived but did not recover during study period	23	45.1
Facial disfigurement	4	7.84
Permanent loss of vision from one eye	3	5.88
Permanent loss of vision from both eyes	1	1.96
Expired during study period	10	19.61

Table 1.7 Treatment offered in terms of Liposomal Amphotericin B and Debridement surgery to various patients

Treatment given	No of patients	Frequency
Liposomal Amphotericin B for 1-7 days	35	68.63
Liposomal Amphotericin B for 8-14 days	11	21.57
Liposomal Amphotericin B for more than 14 days	1	1.96
Debridement surgery	34	66.67

Table 1.8 Number of patients who took surgery charted with number of patients who survived the study period

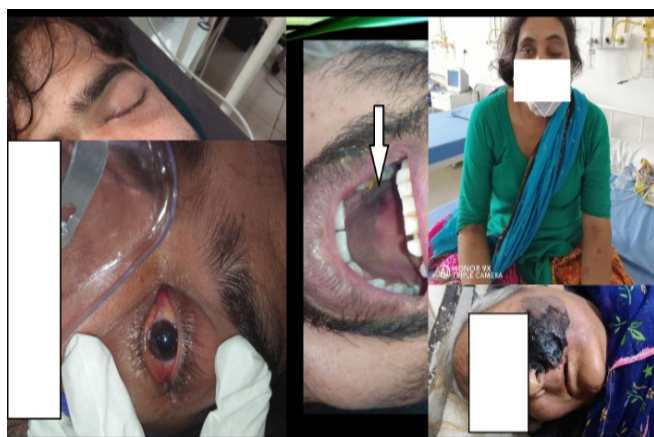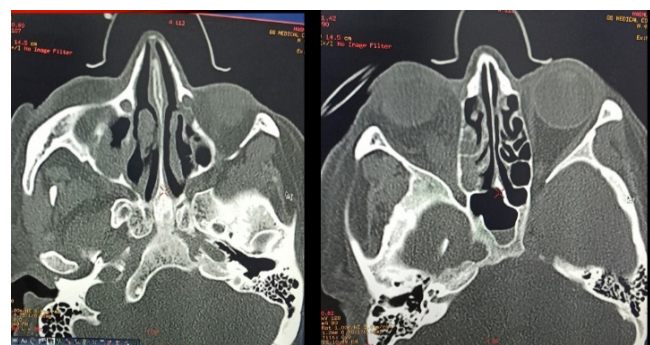
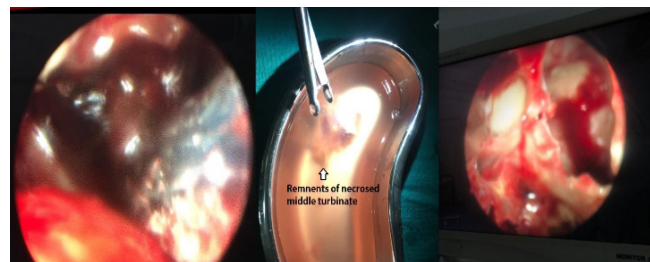
Surgery and survival	No of patients who took surgery	No of patients who did not take surgery	Total patients
No of patients survived during study period	32	9	41
No of patients expired during study period	2	8	10
Total patients	34	17	51

Table 1.9 Effect of surgery on duration of Amphotericin B therapy and hence cost of treatment

Duration of amphotericin B therapy	1-45 days
With Surgery	1-7 days
Without Surgery	1-45 days

Table 1.10 Figures of mortality from the time of presentation

Duration from presentation	No of patients who expired
Within 24 hours	4
24-48 hours	2
48-72 hours	1
More than 120 hours	3
Total	10

**Image 1.1** Clinical features of mucormycosis. Clockwise: Facial swelling, oral cavity eschar, eye swelling, facial eschar, congestion, diminished vision and ptosis of eyes.**Image 1.2** Computerised tomography. a. Rt maxillary sinus non-homogenous opacification, b. Rt orbital involvement with proptosis.**Image 1.3** A. Black Eschar in Nasal Cavity, B. Debrided Remnant of Middle Turbinate, C. Post Debridement Image.

Result

The disease is equally seen in both sexes. The disease is exclusively seen in either diabetics or those who have recently taken steroids. Immuno-compromised patients with Delta strain of COVID 19 Pango lineage B.1.617.2 have more risk of developing mucormycosis than their non COVID counterparts. Oxygen inhalation also contributes to the risk. There is no positive or negative effect of steam inhalation.

There is an increase in no of cases of mucormycosis because of delta strain of COVID 19. There is a shift of peak towards the younger age groups. There is increased frequency of eye involvement. Mortality is maximum within first 72 hours of presentation. However, mortality ratio is less when co-infected with delta strain of COVID 19.

Surgery offers significant benefit by decreasing mortality, decreasing duration of Liposomal Amphotericin B treatment and hence reducing cost of treatment.

Conclusion

Delta strain of COVID 19 Western Uttar Pradesh India has significantly increased the incidence of mucormycosis due to its immunosuppressive effect. Excessive use of steroids has also contributed to the same. Since, patients of younger age group are affected more with this strain, the peak of mucormycosis has also shifted in the same direction. In a young patient with unatherosclerosed and more patent vessels, there is early involvement of ethmoid and ophthalmic vessels and hence early necrosis of turbinate's is seen along with prominent eye symptoms. The massive coverage of black fungus by media has made people extra conscious about the mucormycosis, which has also contributed to early presentation and early diagnosis of the disease. Early diagnosis coupled with early surgery in younger patient may have contributed to lower mortality when recorded over a short time span.

Acknowledgments

None.

Conflicts of interest

None.

Funding

None.

References

- Mallis A, Mastronikolis SN, Naxakis SS, et al. Rhinocerebral mucormycosis: an update. *European Review for Medical and Pharmacological Sciences*. 2010;14(11):987-992.
- Bouza E, Munoz P, Guinea J. Mucormycosis: an emerging disease? *Clinical Microbiology and infection*. 2006;12(7):7-23.
- Global guideline for the diagnosis and management of mucormycosis. 2021.
- Strickland GT. *Hunter's Tropical Medicine*. Philadelphia, PA: WB Saunders. 1984:468-469.
- Koneman E, Allen S. *Diagnostic Microbiology*. Philadelphia, PA: JB Lippincott. 1992:812-814.
- Mucormycosis (Zygomycosis). 2021.
- Branscomb R. An overview of mucormycosis. *CE Update microbiology and virology*. 2002;33(6):1-3.

8. Rippon J. Medical mycology. Philadelphia, PA: WB Saunders. 982:615-637.
9. Black Fungus: These 2 states account for nearly 42% of India's 28252 mucormycosis cases. 2021.