

The versatility of the lateral crural strut graft for correction of abnormalities of the lateral crura in rhinoplasty: a case series

Abstract

Rhinoplasty is considered by many one of the most complex surgeries among all of the plastic surgeries. And the techniques used for the aesthetic modification of the nose have evolved greatly over time and currently rhinoplasty is going through a transitional phase from an aggressive conventional surgery to a more structuralized one. The present study aimed to present the many functions of the Lateral Crura Strut Graft (LCSG) which is a versatile graft technique of structured rhinoplasty to remodel, reposition or reconstruct the lateral cruras through the report of 4 cases of patients operated by the coordinator of the rhinoplasty fellowship service of Santa Casa de Misericórdia de Belo Horizonte.

Keywords: structured rhinoplasty, lateral crura strut graft, lateral crural deformities

Volume 10 Issue 6 - 2018

Alessandra Pereira dos Santos, Gustavo Figueiredo Nunes Rabelo, Renato Alves de Sousa

Fellow of Rhinoplasty of Santa Casa Hospital of Belo Horizonte, Brazil

Correspondence: Alessandra Pereira dos Santos, ENT doctor, fellow of rhinoplasty of Santa Casa Hospital of Belo Horizonte, Rua Professor Salvio Nunes 122, Brazil, Tel +55 31 988901716, Email ale_samt20@hotmail.com

Received: March 25, 2018 | **Published:** November 19, 2018

Introduction

Rhinoplasty is considered by many to be one of the most complex surgeries among all plastic surgeries.¹ The nose is considered to be one of the major structures responsible for adequate respiratory physiology and virtually all other systems are affected to a greater or lesser degree by the lack of predominantly nasal breathing. And due to this principle, nowadays, the functional complaint, besides esthetics, is being valued by surgeons.²

The techniques used for the aesthetic modification of the nose have evolved greatly over time. A few decades ago, surgeries had a radical intent in which excessive resections of the lower lateral cartilages were performed to refine the nasal tip.³ The results over the years were, in most cases, unfavorable both functional and from the aesthetic point of view, because aggressive resections of the lateral crura predisposes to the development of lack of definition, pinching or asymmetry of the tip, alar retractions and nasal valve insufficiency, for example.²

Currently rhinoplasty surgery is undergoing a transitional phase from a conventional aggressive procedure to a more structured one, in which the surgeon recognizes the importance of maintaining or improving certain anatomical structures of the nose for its good functioning and aesthetic appearance.^{2,3} The previous surgical principle of sectioning the nasal cartilages to reshape the nose evolved to the repositioning and restoration of the nasal tissues with the use of cartilage grafts made preferably from the patient's own cartilage.^{2,3}

Constitutional or acquired nasal deformities such as boxy nasal tips with poorly positioned lateral crura, alar retraction, and external nasal valve insufficiency can lead to both aesthetic and functional complaints.⁴⁻⁶ The use of the Lateral Crural Strut Graft (LCSG) is a versatile technique of structured rhinoplasty to remodel, reposition or reconstruct lateral crura.⁴ And due to its great value in the current rhinoplasty scene, the present study aimed to present some of its uses

through the report of 4 cases of patients operated by the coordinator of the Fellowship service of Rhinoplasty of Santa Casa de Misericórdia Hospital of Belo Horizonte.

Cases

Case 1

L.O.L, female patient, with a boxy nasal tip characterized by a cephalic position of the lateral crura. An open primary rhinoplasty was performed with repositioning of the lateral crura with the LCSG made of autologous cartilage of the nasal septum to improve the positioning of these structures (Figure 1).

Case 2

J.A.S, female patient, presented bilateral constitutional alar retraction due to cephalic malposition of lateral crura. An open primary rhinoplasty was performed with repositioning of the lateral crura with the LCSG made of autologous cartilage of the nasal septum to correct this deformity (Figure 2).

Case 3

A.C.M, female patient, with nasal valve insufficiency and consequently nasal obstruction due to previous resection of lateral crura. Open tertiary rhinoplasty was performed with reconstruction and repositioning of the excessively resected lateral crura with the LCSG made of autologous cartilage of the nasal septum.

Case 4

F.A.C, male patient, presented lateral crura convex to the right, concave to the left and cephalic mal position. An open primary rhinoplasty was performed with repositioning and reconfiguration of the lateral crura with the LCSG made of autologous cartilage of the nasal septum (Figure 3).

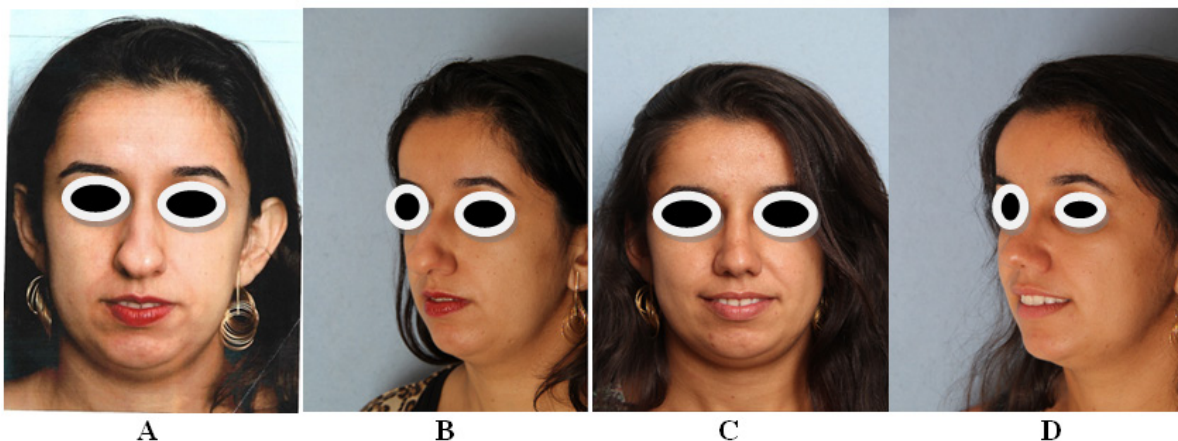


Figure 1 Frontal and profile view in the preoperative period (A and B); frontal and profile view with 5 months postoperative (C and D).

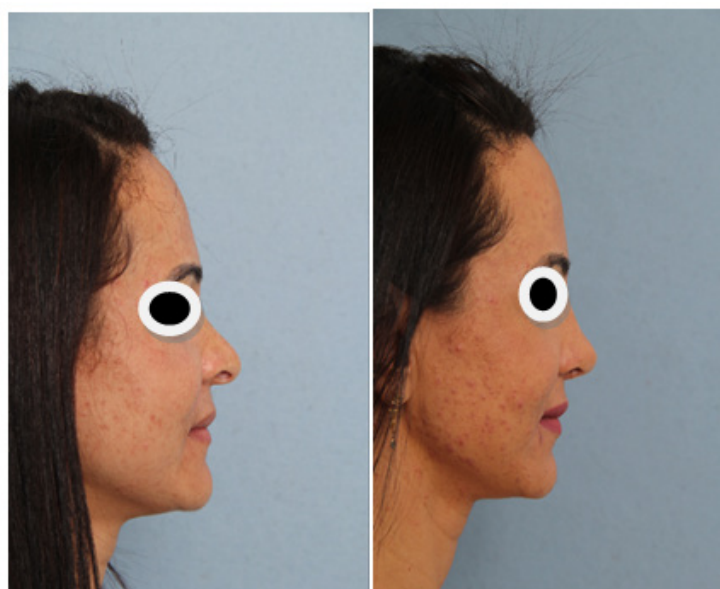

Figure 2 Profile view in the preoperative period (A); profile view in 5 months postoperative period.

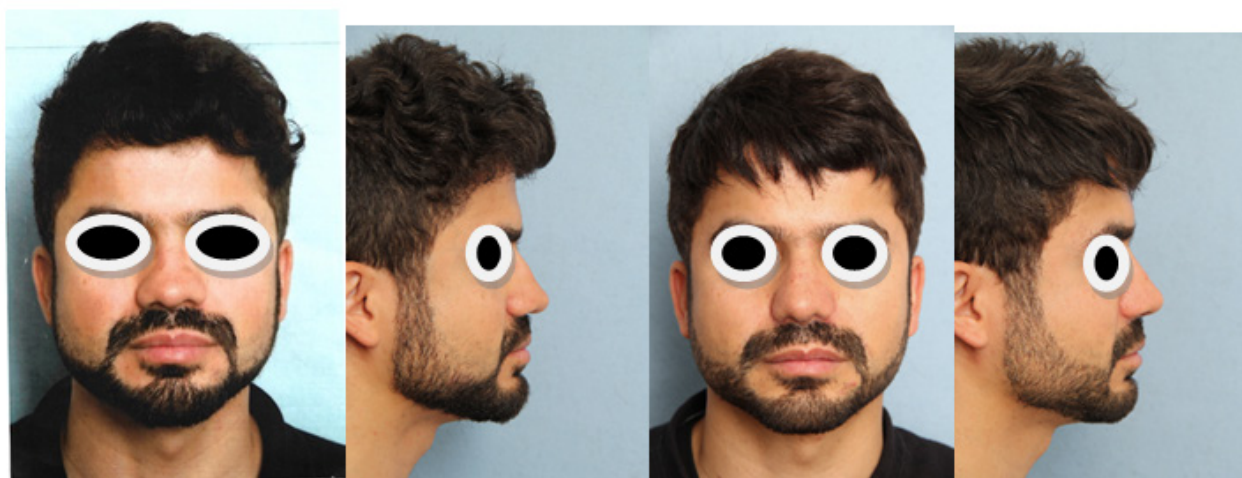

Figure 3 frontal and profile view in the preoperative period (A and B); Frontal and profile view with 1 month into the postoperative period.

Discussion

The ideal nasal tip is described as one in which we observe four luminous points on the surface of the nose that form two equilateral triangles or as a tip in which there is a smooth transition from the tip lobule to the alar lobule without a line of demarcation.¹ Being the shape of the nasal tip ideal or not, it is in all cases determined by different anatomical factors such as skin thickness, width of the inferior lateral cartilage, width and angulation of the domes, intercrural angle of divergence and by the contour, position and width of lateral crura, which is the main focus of this article.^{1,6,7}

There are several causes of abnormalities of lateral crura, such as cephalic mal positioning and irregularity of their shape, as when they are very convex or concave or with an inadequate width due to aggressive resections.^{1,5-7} And these anatomical alterations of lateral crura can directly influence the shape of the nasal tip and other important nasal structures in the ideal aesthetic of the nose, as is the case with the alar-columellar relationship.^{4,5,8-10} In addition, excessive resection of these structures may affect this relationship and cause alar retraction or external nasal valve insufficiency.^{4,5,9,10}

There can be found in the medical literature a variety of surgical techniques used for the correction of these primary or even secondary anatomical defects of the lateral crura, however, these techniques are used only for a specific abnormality and, as discussed above, there are several deformities that can be seen on these structures. The Lateral crura strut graft's (LCSG) greatest functionality is the fact that it is one of the most versatile techniques currently use to reconstruct, reorient and reconfigure the lateral crura.^{1,4,8} Its indications are diverse and include correction of boxy nasal tip with lateral crura cartilage poorly positioned or convex, alar retractions, external nasal valve insufficiency, among others.^{4,6-9}

Surgical technique

The LCSG is preferably made of the quadrangular cartilage of the patient's own nasal septum, but when there is insufficient cartilage it can be harvest from costal rib or auricular cartilage.^{4,8} Its ideal size is approximately 4 mm wide and 18-25 mm in length.⁸

In order to adequately position the graft, it is necessary to perform a dissection of the undersurface and release of the vestibular skin and mucosa from the domus region to the lateral margin of lateral crura. This surgical step can be facilitated by first using infiltration of anesthetic associated with adrenaline solution for hydro dissection followed by scalpel incision and dissection with converse scissors.

According to Toriumi (2015), once the lateral crus of the lower lateral cartilages is free, the next step would be to use the LCSG to help stabilize the dissected lateral crura and reposition them in a new prepared place.⁹ The medial border of the the graft should be beveled at a 45° angle and fixed just short of the domus with its cephalic margin close but not beyond the cephalic border of the lateral crus. And the apex of the angled end of the LCSG should be placed along the caudal margin of the lateral crus near, but not into the domus. Consequently, this angulation will help raise the caudal margin of the lateral crus, thus creating a more favorable orientation.⁹

In addition, its ideal to place the graft with its concavity directed

to the airway, therefore the risk of causing nasal obstruction in the postoperative period will drop considerably. And to avoid extrusion, the knot, when suturing the graft on the lateral crus, has to be made on the opposite side of the vestibular skin.⁹

The final step is to create a pocket initiated at the lateral end of the marginal incision toward the piriform aperture. The lateral margin of the LCSG is then inserted so that it does not curve into the newly created pocket.⁹ And finally it is important to emphasize that it is not always necessary to create the pocket and reposition the lateral crura. In cases where the lateral crura are well positioned but convex, the LCSG can only be sutured below them in order to flatten them and create a more aesthetically pleasing nasal tip.¹⁰

The boxy nasal tip case

In the thesis described in 2005 by Constantian, most individuals who present a boxy nasal tip have, in fact, malpositioning of the lateral crura and that this anatomical alteration is uncommon in patients with a normal positioning of these structures. Orthotropic or well-positioned lateral crura can be defined when the axis of these are towards the lateral corner of the eye. On the other hand, a poorly placed lateral crura or cephalic lateral crura are more towards the medial corner of the eye.⁶

From another author perspective, Rohrich et al.,⁷ described three types of boxy nasal tips. In type I there is an increase in the divergence above 30 degrees between the intercrural angle and a normal domal arc, that is, 4 mm or less manifesting as the tip defining points; type II, the interdomal divergence is normal or equal to or less than 30 degrees, but the domal angle is above 4 mm creating a widened domal arc; and type III shows a combination of increased angle divergence (greater than 30 degrees) and widened domal arc (4 mm or greater).⁷

Regardless of the definitions of what is in fact a boxy nasal tip, the LCSG can be used as one of the surgical steps in these cases for its correction. For example, in cases of repositioning of cephalic lateral crura, as defined by Constantian⁶, the LCSG is fixed in the region below the lateral crus and positioned inside pockets made on the side walls in order to redirect these structures in a more caudal direction.^{4,6,8} On the other hand, one of the surgical steps for the correction of type II and III boxy nasal tip described by Rohreich et al. (2001), is the use of transdomal suture to reduce the bilateral domal angle. When the lateral side of the lower lateral cartilage is constitutionally weakened, this point may cause a medial displacement of the lateral crura and cause a pinched nose or even nasal obstruction due to the narrowing of the airway. And the LCSG is precisely used in these cases to strengthen and prevent the concave shape of the lateral crura that the transdomal point may eventually cause.^{4,6,7}

Alar retraction case

Seen in profile, the ideal nose possesses an oval shape nostril where the alar margin forms the upper border of the nose and the columella the inferior border. And the distance from the long axis of the nostril to each of these edges should be 1-2 mm. If the distance from the long axis of the nostril to the alar margin is greater than 2 mm this characterizes an alar retraction, which is a nasal deformity that can either be primary or constitutional or as a consequence of previous rhinoplasty.¹¹

For years to diminish or refine a nasal tip, the most commonly used technique was partial cephalic excision of the lateral crus known as the cephalic trim technique. However, the dead space that remains after its excessive removal can cause a cephalic migration of the lateral crura and depending on the patient's alar-columellar relationship, this can lead to an evident alar retraction.^{5,12} According to the degree of retraction, the LCSG plays a key role in its correction. And the surgical steps are essentially the same for the repositioning of the lateral crura, because when the graft is fixed, they are reoriented caudally, with its final position being immediately adjacent to the rearmost retracted lining which will correct this defect.^{4,8}

Case of excessive cephalic excision of lateral crura

Excessive cephalic resection of the lateral crura may, in addition to the alar retraction, cause other nasal deformities such as the collapse of the external nasal valve, seen more commonly in patients with thick skin. During the clinical evaluation of these patients, a weakened cartilage is noticed during palpation and the external valve collapse is clear during normal or forced inspiration.⁵

Fortunately, there are several techniques to repair this anatomic and functional defect, and the LCSG is an excellent and effective option to reconstruct and strengthen the segmented or even absent lateral crura from the first operation.^{4,8}

Other applications of the LCSG

The transdomal point is a very accomplished technique in rhinoplasty with the intention of approaching or reducing the domal angle, thus creating a more ideal tip. However, sometimes this point may generate a secondary deformity in the lateral crura, especially when they are more convex.^{4,6,7} When the transdomal suture is made with the objective of narrowing the domal angle, this can dislocate medially the junction of the lateral crus with the accessory cartilage thus compromising the nasal air. LCSG can then be used precisely to prevent this potential problem by being sutured in the lateral crus and extended to the piriform cavity beyond the junction of the lateral crus with the accessory cartilages.^{4,8}

And finally, a concave lateral crura can generate an aesthetically unpleasant nose appearance in addition to potentially causing an external nasal valve insufficiency and consequently nasal obstruction. By positioning the LCSG below the lateral crura, this reconfigures them in a straighter or slightly convex format which helps stabilize the external nasal valve and provide strength to the lateral crura.^{4,8}

Advantage and disadvantage

As described, LCSG is a technique that can be used in a wide variety of deformities or nasal deficiencies. And as seen in this article, it is useful to aid in the contouring of the nasal tip in patients with cephalic malposition of the lateral crura, correcting alar retractions or external nasal valve collapse and reconfiguring lateral crura that are excessively convex or concave.⁶

In accordance with Conchran and Gunter (2014), the LCSG is one of the most accomplished techniques used by them for the reconstruction of the nasal tip in secondary rhinoplasty when there is excessive excision or weakening of lateral crura, as it provides support and corrects other defects of them. In addition, its positioning below the lateral crura has the advantage of invisibility in the postoperative

period, unlike other grafts, such as the batten graft that may form irregularities in the nasal tip, especially in patients with thin skin.^{6,8,9,13} Furthermore, it helps lateral displacement of lateral crura and minimizes medial movement of the nostrils during forced breathing, which results in the improvement of most cases of external nasal valve insufficiency.^{4,5,8}

Despite its numerous uses and advantages over other available techniques, LCSG is a technique that demands a lot of skill and time and requires an abundant source of graft, which is not always possible in a secondary patient. Therefore, such grafting should be indicated only when other, easier methods are not possible to achieve a satisfactory aesthetic and functional result.⁸

Conclusion

The techniques used for aesthetic modification of the nose have changed a lot over time.^{2,3} In the last decades there has been an evolution from conventional aggressive surgery to a more structured one. Currently, it is more valued the repositioning and restructuring of the nasal structures using cartilage grafts made mainly from the patient's own quadrangular cartilage.^{1,2,3} Because it is a highly versatile technique in the resolution of a range of primary and secondary nasal defects, the LCSG definitely becomes a plausible option in the absence of other easier techniques.^{4,8}

Acknowledgments

None.

Conflict of interest

The author declares there is no conflict of interest.

References

1. Angelos PC, Been MJ, Toriumi DM. Contemporary Review of Rhinoplasty. *Arch Facial Plast Surg*. 2012;14(4):238–247.
2. Rocha PR. Efficacy of Structured and Conventional Techniques on Aesthetic And Corrective Rhinoplasty. *Rev Bras Cir Plást, São Paulo*, 2017;32(1):28–36.
3. Costa SM, Penna WCNB, Souza GMC. Injectable Diced Cartilage Graft for Rhinoplasties: Technique and Experience of the Hospital Felício Rocho. *Brazilian Journal Of Craniomaxillofacial Surgery/Associação Brasileira De Cirurgia Cranio-Maxilo-Facial, São Paulo*, 2012;15(1):17.
4. Gunter JP, Friedman RM. Lateral Crural Strut Graft: Technique and Clinical Applications In Rhinoplasty. *Plast Reconstr Surg*. 1997;99(4):943–952.
5. Gubisch W, Eichhorn-Sens J. Overresection Of The Lower Lateral Cartilages: A Common Conceptual Mistake With Functional And Aesthetic Consequences. *Aesthetic Plast Surg*. 2009;33(1):6–13.
6. Constantian MB. The Boxy Nasal Tip, The Ball Tip, And Alar Cartilage Malposition: Variations On A Theme- A Study In 200 Consecutive Primary And Secondary Rhinoplasty Patients. *Plast Reconstr Surg*. 2005;116(1):268–281.
7. Rohrich RJ, Adams WP. The Boxy Nasal Tip: Classification And Management Based On Alar Cartilage Suturing Techniques. *Plast Reconstr Surg*. 2001;107(7):1849–1863.
8. Cochran CS, Gunter JP. Lateral Crura Strut Grafts. *Dallas Rhinoplasty: Nasal Surgery by the Masters*. 3^o Ed. Boca Raton, FL, 2014 Cap. 29, P. 605–621.

9. Toriumi DM, Asher SA. Lateral Crural Repositioning For Treatment Of Cephalic Malposition. *Facial Plast Surg Clin North Am.* 2015;23(1):55–71.
10. Toriumi DM. New Concepts In Nasal Tip Contouring. *Arch Facial Plast Surg.* 2006;8(3):156–185.
11. Gunter JP, Rohrich RJ, Friedman RM. Classification And Correction Of Alar-Columellar Discrepancies In Rhinoplasty. *Plast Reconstr Surg.* 1996;97(3):643–648.
12. Gruber RP, Zhang AY, Mohebbi K. *Plast Reconstr Surg.* 2010;126(2):581–588.
13. Dolci E.L.L; Dolci, J.E.L; Osman.S.A. *Rinoplastia Revisional. Tratado De Otorrinolaringologia E Cirurgia Cervicofacial, Vol.Iii 2ª Edição Sao Paulo, 2011. Cap. 43. P. 497*