

Middle nasal valve collapse: a way to resolve

Abstract

Middle nasal valve collapse is a partial or complete collapsing of soft structures of nasal pyramid, due to negative intranasal pressures resulting in complete anterior nasal obstruction of air-flow. Even though is relatively common, it is often misdiagnosed or neglected in diagnosis. There are too many suggestions of surgical resolution of the problem, giving an idea that all of them are actually only partially or insufficiently resolving the problem.

In this paper a possible solution of middle nasal vault collapse was presented. A triangle cartilage grafting with respecting of anatomical and functional principles was suggested. An open rhinoplasty approach by its large exposure was, in our hands, the election method for resolving the problem.

Keywords: nasal valve collapse, triangular cartilage, graft, open rhinoplasty

Volume 10 Issue 3 - 2018

Dunja Milicic,¹ Carolina Serodio²

¹Hospital da Luz Arrabida, Department of Otorhinolaryngology, Portugal

²Hospital da Luz Póvoa de Varzim, Department of Otorhinolaryngology, Portugal

Correspondence: Dunja Milicic, Hospital da Luz Arrábida, Praceta de Henrique Moreira 150, 4400-346 Vila Nova de Gaia, Portugal, Tel +351-22 377-6800, Email dmilicic@hospitaldaarrabida.pt

Received: February 01, 2018 | **Published:** May 21, 2018

Introduction

Collapse of nasal valve is a very common cause of nasal obstruction in European population.¹ However, it is not a primary cause of nasal obstruction, which is predominantly due to nasal septal deviation with its associate deformities, hypertrophic rhinitis and deformity of osseous and/or cartilaginous nasal pyramid.^{2,3}

This entity is very often neglected on routine ENT observation, due to professionals' superficial attitude, looking only for the obvious, not listening to the patient's complaints and lacking a standard diagnostic procedure which includes palpation and forced inspiration.^{1,2}

In the Portuguese population, the collapse of the nasal valve is not so common. The well-structured alar cartilage in this population, with hard and arched structure is actually preventing the nasal valve from collapsing. Instead, due to the presence of unilateral weakness of the cartilaginous structure, with no gender preference, the result is an unilateral collapse of the lateral side wall of the pyramid.

The principal problem in these patients is in the soft and weak triangular cartilage, on the contrary of strong and arched alar cartilage.

In previous surgeries, certain procedures from literature were applied which offer a solution to this problem, but in this population, we did not achieve such good results.^{1,5} For instance, the application of a reverse cephalic graft of lateral crura of alar cartilage, despite being a procedure applied predominantly to aesthetic surgeries, it is actually reinforcing the internal nasal valve and angle, especially if it preserves nasal mucosa and possibly muco-perichondrial junction.⁶ Still, the problem of nasal collapse was not entirely solved.

A rim alar graft and a lateral batten graft are strengthening only a part of the triangular cartilage and principally the lateral crus of alar cartilage, and its positioning on the outer side of the lateral alar crus is, again out of anatomical position of valve.⁷

Finally, a bulk resulting of its positioning on the lateral wall of

the nostril (lateral alar crura) is usually annoying the patients, by its hardness and cosmetic deformity, even though some authors minimize the importance of aesthetic dissatisfaction, especially using splay grafting.⁷⁻⁹

H-graft, spring graft technique, valve suspension, elliptic excision, Z-plasty technique and butterfly grafts were recommended by some authors, but we have no experience with these techniques.¹⁰⁻¹⁶

Results and discussion

M.I.V.M.M., ASA1, 53 years old presented bilateral nasal valve collapse, stronger on the right side (Figure 1) (Figure 2).

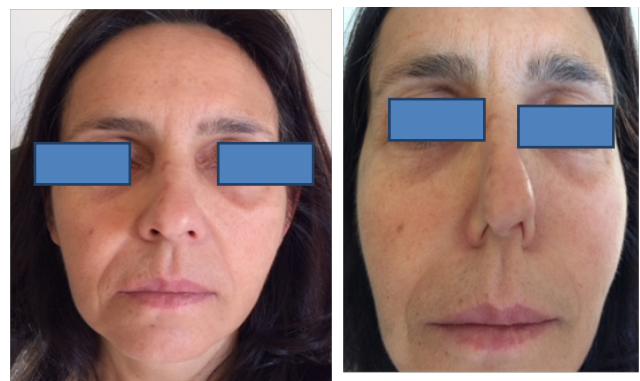

Figure 1 MIVMM, Pre-operative frontal view in normal (left photo) and forced inspiration (right photo) (complete collapse on the right photo).

An open rhinoplasty approach was used to expose all structures involved in the deformity with a possibility of reconstruction with wide access.¹⁷⁻¹⁹

Very long, weak and soft triangular cartilages with short nasal bones, were identified on both sides, giving no mechanical support to breathing and resulting in a middle vault complex collapse.²⁰ Apart

from this deformity, the lateral alar cartilages were very weak and very broad, contributing to the collapse of alar structure.

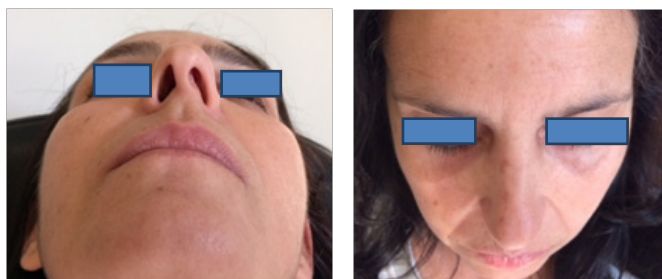

Figure 2 MIVMM, Pre-operative basal (left photo) and helicopter view (right photo).

Lateral crura of alar cartilages were exposed and separated. A returning flap of cephalic border of lateral crus of alar cartilage was formed and sutured (leaving 8 mm width of lateral crus on both sides).⁶

A 2 mm width and 1 cm long rim graft was sutured bilaterally to reinforce a curvature of lateral crura, with “on-lay” technique.

Triangular cartilages were separated from the septum (with preservation of perichondrium and underneath nasal mucosa). A 2-mm width (thickness) graft of septal cartilage with original rhomboid form completely imitating a triangular cartilage of patient (“in situ”) was sutured (5-0 PDS) (two sutures on each side) by “over-lay” technique to the triangular cartilage, doubling a strength of the original patient’s cartilage (Figure 3).

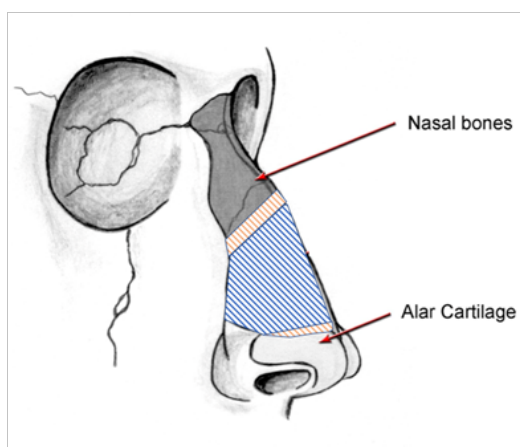


Figure 3 Positioning of “on-lay” graft of triangular cartilage, underlying cranially nasal bones and caudally lateral crus of alar cartilage (Draft based on reference 28).

Cranially, a separation was performed on the osseous/perichondria junction of nasal bones and triangular cartilage, preserving the underlying mucosa.²⁰ The cranial border of the graft was inserted (laid under the caudal border of the nasal bones bilaterally in the length of 6 mm) in order to secure K-area, as it was recommended (Figure 3).³

Caudally, the graft of the same size and form of the original triangular cartilage was sutured, by two permanent 5-0 PDS sutures, reinforcing the interior nasal vault (under-laying the cephalic border of lateral alar crus by 3 mm) (Figure 3). By this “under-lay” positioning and preservation of the mucosa of the internal valve, the anatomical e physiological standards were respected. This was done in order to prevent that negative inspiratory pressure causes a collapse of the

nasal internal angle which should be maintained at 10-15 degrees, as it is recommended.¹ The procedure was performed on both sides.

Finally, both triangular cartilages were sutured to the septal cartilages (three 5-0 PDS sutures), preserving the nasal mucosa and covered with perichondrium. This procedure was performed after a septoplasty with correction of subluxation of septum to the left side.

Postoperative course was normal, with no complications.

Figures 4 and 5 demonstrate the patient 3 months after surgery, without nasal valve collapse on forced inspiration and without any major external deformities with satisfactory aesthetic nasal result.

Even though the right nostril seems larger on a frontal view, on a basal view the asymmetry could be considered minimal (Figure 5).

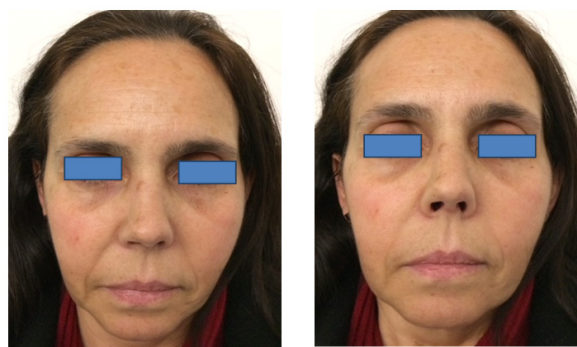


Figure 4 MIVMM, Post-operative frontal view in normal (left photo) and forced inspiration (right photo) (without collapse).

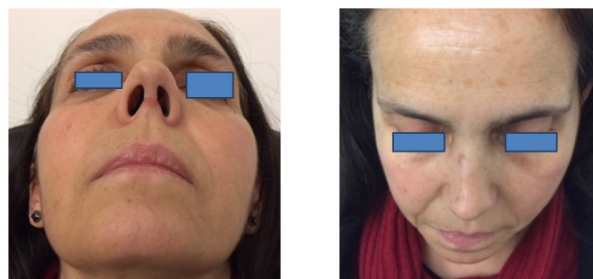


Figure 5 MIVMM, Post-operative basal (left photo) and helicopter view (right photo).

There are several techniques indicated in literature for solving nasal valve collapse.^{1,21,22} Even though all of them give a certain resolution of the problem, we felt that these techniques we regularly used, especially by endonasal approach, did not give us a definitive solution, at least for the Portuguese population.

The standard recommendation for the correction of this type of deformation is the use of spreader grafts.^{5,23,24} Even though there is no doubt of the value of this procedure, one or preferably two 2-4 mm thickness grafts are needed on both sides of the septal cartilage, which results in enlarging/widening of the nasal pyramid in middle vault at least 8 mm.

A “quadrate” form and wide nasal pyramid is not appreciated neither by patients nor by surgeons. This type of implantation is also enlarging the interior nasal vault angle and compromising breathing.^{5,20}

We consider the use of auto-spreader flaps a more anatomical and physiological option, giving the satisfactory aesthetic result, without enlargement of the nasal pyramid and internal nasal angle.²⁵ On the other side, auto-spreader flaps are not sufficient to reinforce the lateral part of triangular cartilage, in proximity to piriform aperture. The possibility of a side wall collapse continues to be present.

An “over-layer” suture of triangular cartilage was suggested by other authors, but only after major resection of nasal hump and consequent damage of triangular cartilage.²⁶

By the open rhinoplasty approach, we have used in this case, it was much easier to see, to define and to correct the deformity, as it had already been suggested in 1966.^{17,27}

Even though the modification of lateral crura of alar cartilage was a significantly important procedure to secure the strength of the interior of the nasal valve, the principal importance was given to strengthening the whole triangular cartilage. The replication of the patient’s original triangular cartilage was done in its whole dimension. The reinforcing of the whole lateral wall of the nasal pyramid, exactly in the middle nasal vault, was done by imitating the anatomical and physiological concept and in such “nature respectful” way, preventing it from collapsing in suction (inspiration) (Bernulli law).

The angulation of the nasal valve and nasal mucosa itself were preserved, as well as perichondrium, with no widening of the nasal pyramid nor the lateral side-wall of the nose, very appreciated by the patient.

The immediate and long term functional result was obtained and the aesthetic expectations of the patient were fulfilled.

Conclusion

Nasal valve collapse represents a complete or partial obstruction of anterior nasal air-flow, due to collapse of soft structures of the nasal pyramid.

A possible solution by triangular cartilage grafting was presented in this paper. The reinforcing of the strength the cartilages was suggested and confronted with some other surgical solutions.

The open rhinoplasty approach, as it was supposed, by its wide exposure was extremely useful in confirmation of exact diagnosis and permitted the exact correction of the deformity.

Acknowledgments

We would like to thank all professionals of the Operating theatre of Hospital Luz Póvoa de Varzim, Portugal for the help provided during the surgery.

Conflict of interest

I confirm there is no financial or personal relationship with any people or organization related to this report/opinion that could inappropriately influence this work.

References

- Bloching MB. Disorders of the nasal valve area. *GMS current topics in otorhinolaryngology, head and neck surgery*. 2007;6:Doc07.
- Constantian MB, Clardy RB. The relative importance of septal and nasal valvular surgery in correcting airway obstruction in primary and secondary rhinoplasty. *Plast Reconstr Surg*. 1996;98(1):38–54.
- Dispenza F, Saraniti C, Sciandra D, et al. Management of naso-septal deformity in childhood: long-term results. *Auris Nasus Larynx*. 2009;36(6):665–670.
- Teymoortash A, Fasnula JA, Sazgar AA. The value of spreader grafts in rhinoplasty: a critical review. *Eur Arch Otorhinolaryngol*. 2012;269(5):1411–1416.
- Haack S, Gubisch W. Lower lateral crural reverse plasty: a technique to correct severe concavities of the lateral crus. *Aesthetic Plast Surg*. 2011;35(3):349–356.
- Toriumi DM, Josen J, Weinberger M, et al. Use of alar batten grafts for correction of nasal valve collapse. *Arch Otolaryngol Head Neck Surg*. 1997;123(8):802–808.
- Byrd HS, Meade RA, Gonyon DL. Using the autospreader flap in primary rhinoplasty. *Plast Reconstr Surg*. 2007;119(6):1897–1902.
- Deylamipour M, Azarhoshangh A, Karimi H. Reconstruction of the internal nasal valve with a splay conchal graft. *Plastic and reconstructive surgery*. 2005;116(3):712–720.
- Tastan E, Demirci M, Aydin E, et al. A novel method for internal nasal valve reconstruction: H□ graft technique. *Laryngoscope*. 2011;121(3):480–486.
- Sen C, Iscen D. Use of the spring graft for prevention of midvault complications in rhinoplasty. *Plast Reconstr Surg*. 2007;119(1):332–336.
- André RF, Vuyk HD. Nasal valve surgery; our experience with the valve suspension technique. *Rhinology*. 2008;46(1): 66.
- Weeks DM. Internal Nasal Valve Functional Surgery—Reply. *Arch Facial Plast Surg*. 2012;14(6): 465–468.
- Stacey DH, Cook TA, Marcus B. Correction of internal nasal valve stenosis: a single surgeon comparison of butterfly versus traditional spreader grafts. *Ann Plast Surg*. 2009;63(3):280–284.
- Weeks DM. Internal Nasal Valve Functional Surgery—Reply. *Arch Facial Plast Surg*. 2012;14(6): 465–468.
- Scheila MG. Elliptic Excision of the Upper Lateral Cartilage in the Rhinoplasty for Correction of the Large Middle Third. *International archives of otorhinolaryngology*. 2009;13(3):633.
- Padovan I. *External approach in rhinoplasty (decortication)*. In: Symp ORL. 1966. p. 354–360.
- Jugo SB. Total septal reconstruction through decortication (external) approach in children. *Arch Otolaryngol Head Neck Surg*. 1987;113(2):173–178.
- William KW, Russell WH K. External septorhinoplasty: A tool for teaching and for improved results. *The Laryngoscope*. 1981;91(6):945–951.
- Stucker Fred J, de Souza C, Kenyon GS, et al. *Rhinology and facial plastic surgery*. Springer Science & Business Media, 2009.
- Spielmann PM, White PS, Hussain SS. Surgical techniques for the treatment of nasal valve collapse. *Laryngoscope*. 2009; 119(7):1281–1290.
- Orten SS, Hilger PA. Surgical solution: nasal valve collapse. *Archives of facial plastic surgery*. 1999;1(1):55–57.
- Sheen JH. Spreader graft: a method of reconstructing the roof of the middle nasal vault following rhinoplasty. *Plast Reconstr Surg*. 1984;73(2):230–237.

23. SHEEN, Jack H. Spreader graft revisited. *Perspectives in Plastic Surgery*. 1989;3(01):155–163.
24. Ozmen S, Ayhan S, Findikcioglu K, et al. Upper lateral cartilage fold-in flap: a combined spreader and/or splay graft effect without cartilage grafts. *Ann Plast Surg*. 2008;61(5):527–532.
25. Stucker FJ, Lian T, Sanders K. Management of severe bilateral nasal wall collapse. *Am J Rhinol*. 2002;16(5):243–248.
26. Toriumi DM, Mueller RA, Grosch T, et al. Vascular anatomy of the nose and the external rhinoplasty approach. *Arch Otolaryngol Head Neck Surg*. 1996;122(1): 24–34.
27. <https://emedicine.medscape.com/article/1820512-overview#a4>