

# Septoplasty and turbinoplasty through Le fort I osteotomy

## Abstract

**Aim:** We describe the technique of septoplasty and turbinectomy/turbinoplasty performed concomitantly with orthognathic surgery, via the Le Fort I, after the push down of the maxilla.

**Objective:** To describe the technique of septoplasty and turbinectomy concomitant with Le Fort I type osteotomy, through the same pathway, after the push down of the maxilla.

**Method:** Literature review and description of surgical technique.

**Keywords:** Le fort I type osteotomy, septoplasty, turbinoplasty, pyriformeplasty

Volume 10 Issue 1 - 2018

**Oscimar Sofia**

Faculty of Medicine of Santa Casa de São Paulo, Brazil

**Correspondence:** Oscimar Sofia, Faculty of Medicine of Santa Casa de São Paulo, R. Duarte de Azevedo, 284 - Santana, São Paulo - SP, 02036-020, Brazil, Tel 11-29505096, Email [oscimarsofia@gmail.com](mailto:oscimarsofia@gmail.com)

**Received:** September 11, 2017 | **Published:** February 16, 2018

## Introduction

Le Fort I type surgery patients can often be exclusively with mouth breathing, and therefore may develop maxillary atresia, vertical growth, with gingival (gingival smile) exposure, with incompetence of lip seal, with palate ogival, and finally dental malocclusion. For this reason, they need to undergo orthognathic surgery, almost invariably undergoing a Le Fort I type osteotomy. The treatment of deformities of the nasal septum and the hypertrophy of the turbinates is necessary because in many of these cases the deformity is of exclusive respiratory cause, in which case the patient will be submitted to maxillary impaction to correct this vertical skeletal growth pattern. When impacting the maxilla, it is a fact that the nasal cavity will be diminished, because when the maxilla is elevated vertically, the entire palatal bone will occupy an upper position of the nasal cavity, thus worsening nasal respiratory function.<sup>1,2</sup>

Controversies exist about which is the best technique for the treatment of inferior turbinate hypertrophy. The literature describes microdebrider assisted turbinoplasty, radiofrequency ablation, ultrasonic aspiration of the turbinate bone. It seems to be agreed that turbinoplasty techniques are more adequate than turbinectomy techniques.<sup>3</sup>

In 2016 Posnick et al.,<sup>4</sup> correlated the effectiveness and complications of nasal and maxillary procedures being performed at the same time. This retrospective study, with n=262, may conclude that bimaxillary surgery, possibly associated with mentoplasty and pyriform surgery, performed with septoplasty and volume reduction of the inferior turbinates, are feasible and highly effective techniques in indicated cases, and with a few complications. During orthognathic surgery, the surgeon has the opportunity to contribute to patients' quality of life through nasal surgery with increased nasal airflow, simultaneously performing septoplasty and turbinectomy/inferior turbinoplasty, and eventually promoting the widening of the pyriform aperture.<sup>5</sup> Moses et al.,<sup>6</sup> postulated that Le Fort I type osteotomy used for correction of skeletal deformities (for example, maxillary vertical overhang, anterior open bite, asymmetries of the middle third of the face) may aggravate obstruction to pre-existing nasal airflow and the sinus disease.

The Le Fort I type osteotomy provides excellent access to the nasal septum and lower turbinate. The consequences and management of

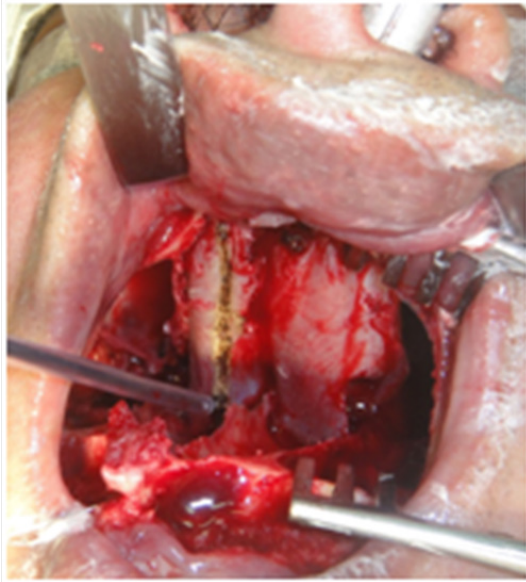nasal airway obstruction in patients with dentofacial deformity are evident. Authors describe the correlation between obstruction of nasal breathing and development of dentofacial deformities. The continuous open bite caused by nasal obstruction is directly correlated with maxillary growth deformity. When indicated, simultaneous operation of the jaws, Le Fort I type osteotomy, and correction of nasal abnormalities, septoplasty, reduction of the inferior turbinates and remodeling of the pyriform opening are effective for the treatment of nasal obstruction, and the level of complications is minimal and not greater procedures.<sup>7</sup> Initially we performed tracheostomy or orotracheal intubation and derived the probe to the floor of the mouth, so as not to interfere with the dental occlusion that would be corrected by orthognathic surgery. This determined a submandibular scar at the end. Subsequently, we adopted nasotracheal intubation to perform orthognathic surgery, and at the end of this, we asked the anesthesiologist to change the intubation to orotracheal so that we could operate the nose. This procedure was not very affective to anesthesiologists, because at the end of the orthognathic surgery it presented edema and some difficulty in intubation. Based on these difficulties, nasotracheal intubation technique, and after the "push down" of the maxilla, we incised the nasal floor mucosa to access the nasal turbinates, and detachment of the nasal septum and treatment of septal deviations that might present. Next, we describe the technique of septoplasty and turbinectomy via Le Fort I.

## Technical description

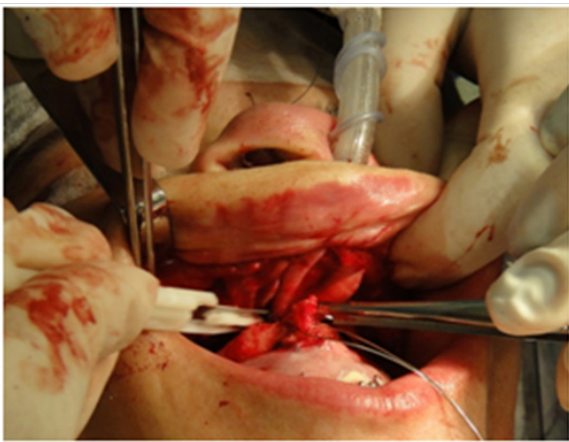
Through the Le Fort I type osteotomy, the patient can undergo septoplasty and turbinectomy/turbinoplasty by the same route, that is, can be submitted to treatment of the probable cause of the facial deformity.

Shortly after the push down, the lower jaw is exposed to the mucosa of the floor of the nose, including the nasal septum (Figure 1). At this time, the septum may undergo subpericondral and subperiosteal detachment and treatment of its deformity (Figure 2). After incision of the mucosa of the nasal floor, the inferior nasal turbinate is well evident, and can be treated with great efficiency (Figure 3) (Figure 4). After treatment of nasal septum deviations and turbinectomy or turbinoplasty, the mucosa of the nasal floor is sutured with cat gut wire 4.0 (Figure 5). After resection of the mucosal or bony tissue of the turbinates, and after careful hemostasis, the mucosa of the floor of the nose is sutured with cat gut 4-0 wire. After treatment of the

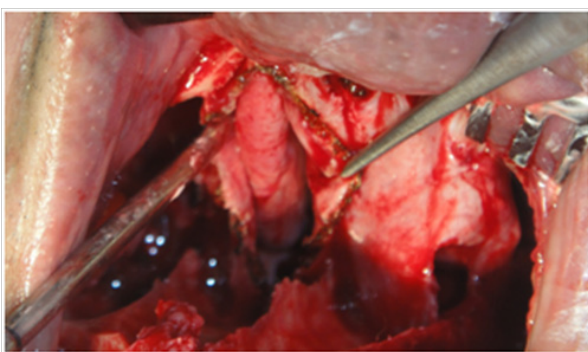
deformities of the septum and nasal turbinates, the maxilla can be repositioned in its orthognathic position, according to the previous planning, without causing greater damage to nasal breathing. At this point, the widening of the piriform opening can also be performed, if required.



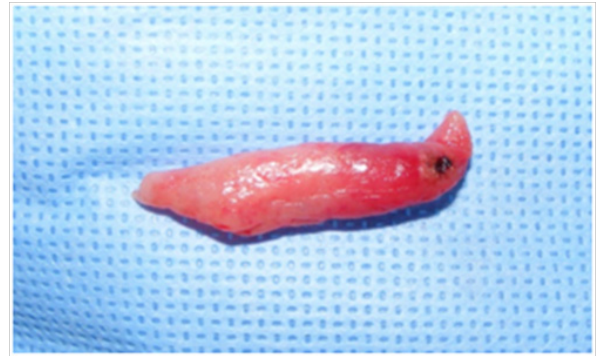**Figure 1** The mucosa of the nasal floor can be incised and through this route the inferior nasal turbinates are exposed, which can be submitted to the most varied techniques of treatment, turbinectomy or turbinoplasty.



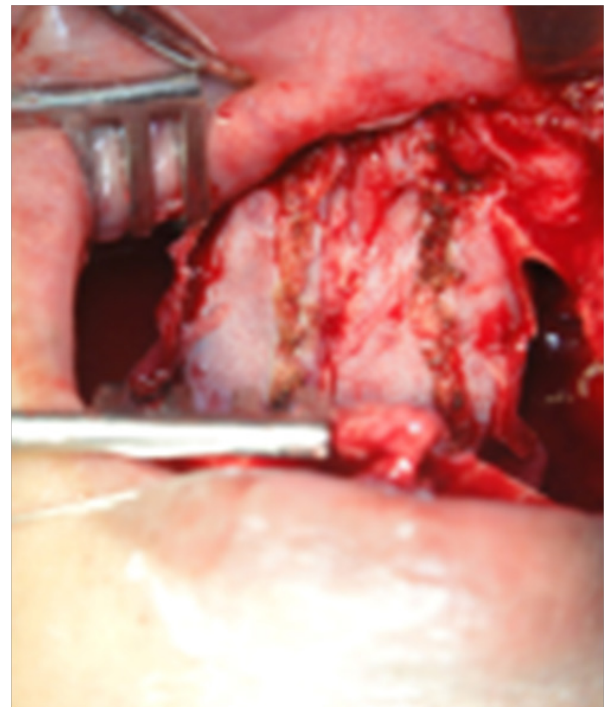
**Figure 2** Resection of cartilaginous septum portion with scalpel.



**Figure 3** Incision of the mucosa of the nasal floor and exposure of the inferior nasal turbinates.



**Figure 4** The portion of the inferior turbinate resected.



**Figure 5** After resection of the mucosal or bony tissue of the turbinates, and after careful hemostasis, the mucosa of the floor of the nose is sutured with cat gut 4-0 wire.

### Conclusion

Septoplasty and turbinectomy/turbinoplasty performed concomitantly with orthognathic surgery provide satisfactory results with an index of complications compatible with nasal surgery performed alone.

### Acknowledgements

None.

### Conflicts of interest

Author declares no conflicts of interest.

### Funding

None.

## References

1. Dhulipalla S. Comparative study of response through reduction in the size of hypertrophied inferior turbinate causing nasal obstruction by different surgical modalities: a prospective study. *Indian J Otolaryngol Head Neck Surg.* 2015;67(1):56–59.
2. Brunworth J, Holmes J, Sindwani R. Inferior turbinate hypertrophy: review and graduated approach to surgical management. *Am J Rhinol Allergy.* 2013;27(5):411–415.
3. Ye T, Zhou B. Update on surgical management of adult inferior turbinate hypertrophy. *Curr Opin Otolaryngol Head and Neck Surg.* 2015;23(1):29–33.
4. Posnick JC, Choi E, Adachie A, et al. Correction of Symptomatic Chronic Nasal Airway Obstruction in Conjunction With Bimaxillary Orthognathic Surgery: Does It Complicate Recovery and Is It Effective?. *J Oral Maxillofac Surg.* 2016;74(3):620.e1–11.
5. Posnick JC, Fantuzzo JJ, Troost T. Simultaneous intranasal procedures to improve chronic obstructive nasal breathing in patients undergoing maxillary (le fort I) osteotomy. *J Oral Maxillofac Surg.* 2007;65(11):2273–2281.
6. Moses JJ, Lange CR, Arredondo A. Endoscopic treatment of sinonasal disease im patients who have had orthognathic surgery. *Br J Oral Maxillofac Surg.* 2000;38(3):177–184.
7. Posnick JC, Agnihotri N. Consequences and management of nasal airwayobstruction in the dentofacial deformity patient. *Curr Opin Otolaryngol Head Neck Surg.* 2010;18(4):323–331.