

Nasal septal suture technique versus nasal packing after septoplasty: a prospective comparative study

Abstract

Background: The aim of this study is to compare the effect of nasal septal suturing versus nasal packing after septoplasty surgery.

Methods: This is a prospective comparative study done on 100 patients who underwent septoplasty with or without turbinoplasty. Patients in the age group 18- 60 years were included in the study. The patients were divided randomly into 2 groups. In group A: Nasal septal suturing was done and in group B: Internal nasal packing was done. The operating time, postoperative pain, outcome and complications were evaluated.

Results: Patients with group B complained more nasal pain and head ache in the immediate post-operative period. In these patients the mean postoperative pain scores were 4.75 ± 1 , where as in group A, it was 3.46 ± 1.5 . Internal nasal packing was found to be significantly more painful than nasal septal suturing ($p=0.009$). Though the mean operating time in Group A was found to be more prolonged than Group B, it was not statistically significant ($p=0.167$). Synechiae formation was more in group B compared to group A ($p=0.042$). There were no cases of infection, hematoma and septal perforation among these groups.

Conclusion: The use of nasal septal suturing technique is a useful alternative to nasal packing, with only minor increase in operating time.

Keywords: nasal septal suture, nasal packing, septoplasty

Volume 10 Issue 1 - 2018

Shambulinga Killera, Deepthi Padmanabhan,
Borlingegowda Viswanatha

Otorhinolaryngology Department, Bangalore Medical College & Research Institute, India

Correspondence: Borlingegowda Viswanatha, MS, PhD, FACS (USA), FRCS (Glasgow), Professor of ENT, Bangalore Medical College & Research Institute, Bangalore, India, Tel 919845942832, Email drbviswanatha@yahoo.co.in

Received: October 27, 2017 | **Published:** January 11, 2018

Introduction

Nasal septal surgery is one of the most common operations performed in Otorhinolaryngology department. Septoplasty corrects structural deformities of the nasal septum to relieve nasal obstruction.

Nasal packing materials are widely used in endonasal surgery, including septoplasty, turbinoplasty and paranasal sinus surgery. They are also used to prevent synechiae and haematoma formation, to support septal flap apposition, and to close dead space between cartilage and subperichondrial flaps.¹ Several types of nasal packs are used post-operatively in nasal and sinus surgery. There are various packing materials described in the literature, such as different types of gauzes with or without medication, Tefla, cellulose and foam, absorbable gelatin sponges, Merocel, internal nasal splint, polyethylene oxide gel and alginate.²

Post-operative pain, mucosal injury, worsening of breathing due to sleep disorders, displacement and aspiration of the packing material, allergy, toxic shock syndrome and postoperative infections are the complications associated with nasal packing.^{3,4} Rhinologists have not come to any conclusions about accepted standards regarding the materials used for nasal packing and the definite indications of its usage.⁵

In this study we aim to compare the effects of nasal septal suturing versus nasal packing in septoplasty surgery.

Materials and methods

This study is conducted on 100 patients visiting the outpatient and inpatients department of Otolaryngology, in a tertiary care institute, from July 2015 and July 2017. A total of 100 patients diagnosed with symptomatic deviated nasal septum (DNS) were distributed randomly into two groups. Patients with symptomatic DNS and who gave written informed consent were only included in the study.

Demographic information pertaining to their age, sex, occupation, and personal history was recorded. Detailed history regarding symptom onset, progression and associated features were elicited and recorded. Patients with vasomotor rhinitis, nasal polyposis, allergic rhinitis, immune deficiencies, pulmonary and/or cardiovascular disorders, and those who received long term drug therapy for any condition were excluded from the study. A comprehensive clinical examination was carried out in all the patients.

Following this, the patients were randomly categorized into two groups- Group A and group B each group with 50 patients. All patients underwent septoplasty with or without turbinoplasty as a standard procedure and in group- A nasal septal suturing was done, where as in group - B internal nasal packing was done.

All surgeries were performed under general anesthesia. Local infiltration on both sides of the septum and floor of nasal cavity was done with 1% lignocaine with 1: 100000 adrenaline. At the end of the surgery, the patients were randomly selected to have either nasal packs or nasal septal suturing.

In group A, 4 separate sutures were placed horizontally, vertically or obliquely depending on the elevated part of the septum, using 3/0 Vicryl as the suture material. The places and positions of the sutures were designed according to the elevated parts of the septum. The least number of sutures which was enough to stabilize the septum was applied. In Group B, septum on either side was packed by framycetin ribbon packs. The operative time for nasal septal surgery was measured from the incision over septum to complete nasal pack insertion or intranasal suturing.

Nasal packs were removed 24hrs later. Patients were asked to record their pain levels on a visual analogue score (VAS), at 24hrs post operative period. The pain score charts (VAS) consisted of a linear scale with 10 gradations ranging from 1 (no pain) to 10

(severe pain), and all the complications like hemorrhage, epiphora, discomfort upon swallowing, sleep disorder, septal hematoma, infections and adhesions were noted. The patients were discharged the day after surgery with analgesic (paracetamol tablet) and antibiotic (amoxicillin/clavulanic acid tablet) in weight-related doses. A follow-up visit was scheduled every month for three months, during which diagnostic nasal endoscopy was done to assess synechia, adhesion formation and septal perforation.

Data analysis

The data was statistically analyzed using the SPSS version 20.0. To compare the two groups with regards to nasal pain, headache and the Nasal Obstruction Symptom Evaluation (NOSE) score at 3months, Mann-Whitney U test was used. Chi-square test was used to compare the percentage of hemorrhage, epiphora, discomfort upon swallowing and sleep disturbances in the two groups. With regards to hemorrhage and postoperative pain were used, the Fischer and the Mann-Whitney tests, respectively. A *p* of 0.05 ($\alpha = 0.05$) was considered as statistically significant.

Results

A total of 100 patients with symptomatic DNS were included in the study. At the end of the surgery, the patients were randomly selected to have either nasal septal suturing or nasal packing groups (group A *n*=50, group B *n*=50). There were 64 males and 36 females in the study (Table 1). The mean age in the group A was 37.96 ± 10.9 years and the mean age in the nasal pack group was 38.66 ± 12.5 years.

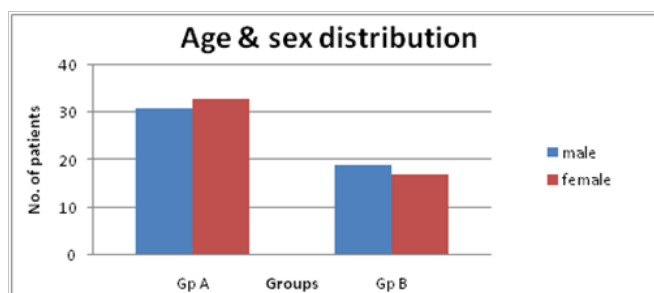


Table 1 Comparison of the male and female study in the nasal pack group

Septoplasty alone was done in 62 cases and with turbinoplasty done in 38 cases. Of the 100 patients studied, 46 patients had anterior septal deviation, 31 had posterior deviation and 33 had both anterior and posterior deviation. Mean operative time in group A is 43min which is little more than in group B is 32min ($p=0.167$), which was statistically not significant.

Nasal pain and headache at 24hrs, in patients in nasal packing group was found to be more (Table 2), which was found to be statistically significant.

8 (16%) patients in group A had bleeding in the postoperative period, compared to 3 patients (6%) in group B ($p < 0.05$) (Table 3). Epiphora, discomfort in swallowing and sleep disturbances was more frequent in patients with nasal packing, but only epiphora had statistical significance (Table 4).

Synechia was seen in 4 cases in group A and in 12 cases in group B, (p value = 0.042) which was statistically significant. Residual deviation were seen in 6 cases in group A and in 2 cases in group B, (p value = 0.08) which was statistically not significant. No septal perforations were seen in both groups.

Table 2 Comparison of the VAS median of postoperative pain in both groups

	Septal Suturing Group:A [n = 50]	Nasal Packing Group: B [n = 50]	p Value*
Nasal pain at 24hr	3.46 ± 1.5	4.75 ± 1.93	0.009
Headache at 24hr	4.2 ± 1.5	5.4 ± 1.65	0.006

*Mann Whitney U test

Table 3 Comparison of postoperative nasal hemorrhage in both groups

	Septal Suturing Group:A [n = 50]	Nasal Packing Group: B [n = 50]	p Value*
Postoperative Hemorrhage	8 (16%)	3 (6%)	0.11

*Chi square test

Table 4 Comparison of complications in both groups after surgery

Complications	Septal Suturing Group:A [n = 50]	Nasal Packing Group: B [n = 50]	p Value*
Epiphora	5 (10)	22 (44)	0.001
Swallowing discomfort	6 (12)	11 (22)	0.183
Sleep disorder	23 (46)	32 (64)	0.07
Synechia	4 (8)	12(24)	0.042
Infection	0	0	-

*Chi square test

Discussion

Nasal packing is used primarily to control bleeding in all endonasal surgery. It is also used for internal stabilization following operations on the cartilaginous and bony skeleton of the nose.⁶ Apart from hemostasis, packing is used to prevent complications of septal surgery including hematoma, infection, abscess formation, and perforation.³ In our study there were no such complications among both groups.

Ardehali et al.,³ compared the efficacy of a trans-septal suturing technique with conventional nasal packing in the classic septoplasty operation. They confirmed that patients who underwent septoplasty, intranasal packing insertion did not benefit more than those who had trans septal suturing. Being consistent with the literature our study showed that using trans septal suturing will have similar results to those from the nasal packing group, but the former results in less pain.

The disadvantages of nasal packing include the discomfort of breathing through the mouth, headache, dysphagia, aspiration, airway obstruction, Eustachian tube block and foreign body reaction or infection; moreover, a greater degree of pain, especially when the packing is removed, also total nasal obstruction, which leads to changes in respiratory mechanics and the arterial blood gas tension.^{7,8} In our study epiphora, discomfort in swallowing and sleep disturbances were more frequent in patients with nasal packing, but only epiphora showed statistical significance.

Painful nasal pack removal is often the most uncomfortable aspect of septoplasty surgery for patients. Pain may be caused by dislodgement of the blood clot and adherent tissues, following adherence of traditional nasal tampons to the nasal septum over the original bleeding site.⁹ There have been few studies suggesting that nasal packing should not be used because of the discomfort at the time of removal.¹⁰

Suturing the septum in septoplasty is suggested as a safe procedure that can replace nasal packing, so patients need not have to go through the painful event of pack removal (7,8). Korkut et al.⁷ studied postoperative pain levels, operation time and complications between nasal packing and suturing. They concluded that the use of continuous septal suturing is an easy modification of the standard procedure, with only a small increase in the operation time and without further increasing complication rates (7). In our study, patients with trans septal suturing experienced less pain post operatively with mean pain score of 3.46 ± 1.5 in VAS median scale.

The remaining complications were more frequent in patients with nasal packing and contributed to greater morbidity in the immediate postoperative period in these patients. Epiphora results from lacrimal duct obstruction and sleep disorders happen because of worsening in apnea and consequent frequent awakenings.

Septoplasty improved nasal breathing and quality of life for all patients when assessed 3 months after surgery, with no differences between the two groups. We can therefore infer that nasal packing does not guarantee better surgical outcomes. Quality of life improvements measured through the NOSE questionnaire of patients subjected to septoplasty has already been proven by Bezerra et al.,¹¹

Ozkiris et al.,¹² in their study concluded that, nasal septal surgery can be safely performed without postoperative nasal packing. Their study showed that trans septal suturing seems not only reliable but also comfortable and painless, compared to nasal packing, with only a minor increase in operating time. Suturing the septum in septoplasty is suggested by some authors as a safe procedure that can replace nasal packing.^{7,13}

Conclusion

The use of nasal septal suturing technique is a useful alternative to packing, with only minor increase in operating time. Routine anterior nasal packing should be challenged for not presenting proven benefit, increasing morbidity and it can potentially cause serious complications.

Acknowledgments

None.

Conflicts of interest

Author declares there are no conflicts of interest.

Funding

None.

References

1. Weber R, Hochapfel F, Draf W. Packing and stents in endonasal surgery. *Rhinology*. 2000;38(2):49–62.
2. Weber R, Keerl R, Hochapfel F. Packing in endonasal surgery. *Am J Otolaryngol*. 2001;22(5):306–320.
3. Ardehali MM, Bastaninejad S. Use of nasal packs and intranasal septal splints following septoplasty. *Int J Oral Maxillofac Surg*. 2009;38(10):1022–1024.
4. Watson MG, Campbell JB, Sheno PM. Nasal surgery: does the type of nasal pack influence the results? *Rhinology*. 1989;27(2):105–111.
5. Lubianca JF, Sant'anna GD, Mauri M, et al. Evaluation of time of nasal packing after nasal surgery: a randomized trial. *Otolaryngology - Head & Neck Surgery*. 2000;122(6):899–901.
6. Genç E, Ergin NT, Bilezikçi B. Comparison of suture and nasal packing in rabbit noses. *Laryngoscope*. 2004;114(4):639–645.
7. Korkut AY, Teker AM, Eren SB, et al. A randomised prospective trial of trans-septal suturing using a novel device versus nasal packing for septoplasty. *Rhinology*. 2010;48(2):179–182.
8. Yildirim A, Yasar M, Bebek AI, et al. Nasal septal suture technique versus nasal packing after septoplasty. *Am J Rhinol*. 2005;19(6):599–602.
9. Chheda N, Katz AE, Gynizio L, et al. The pain of nasal tampon removal after nasal surgery: a randomized control trial. *Otolaryngol Head Neck Surg*. 2009;140(2):215–217.
10. Orlandi RR, Lanza DC. Is nasal packing necessary following endoscopic sinus surgery? *Laryngoscope*. 2004;114(9):154.
11. Bezerra TF, Stewart MG, Fornazieri MA, et al. Quality of life assessment septoplasty in patients with nasal obstruction. *Braz J Otorhinolaryngol*. 2012;78(3):57–62.
12. Özkırış M, Kapusuz Z, Saydam L. Comparison of nasal packs with transseptal suturing after nasal septal surgery. *American journal of otolaryngology head and neck medicine and surgery*. 2013;34(4):308–311.
13. Lemmens W, Lemkens P. Septal suturing following nasal septoplasty, a valid alternative for nasal packing? *Acta Otorhinolaryngol Belg*. 2001;55(3):215–221.