

# The Obstructive Sleep Apnea Syndrome (OSAS)

## Abstract

Respiratory disorders are a big issue that affects around 60% of the population all over the world. It varies from simple snoring up to severe stridor which appears mainly during sleep. The cause of all respiratory disorders depends on obstruction, vibration or both. We can also find respiratory disorders in some rare cases like Obesity Hypoventilation Syndrome or Multisystem Disease. The respiratory events start with simple snoring without symptoms of dyspnea or hypopnea. It may extend to arousals due to respiratory efforts (RERAs Syndrome).

With more and more distress, the hypopnea (decrease in Oxygen) appears till complete apnea occurs with awakened stridor. The most common sequence of events in sleep respiratory disorders can be summarized into the following; simple snoring which leads to the increase in upper airway resistance and finally ending in a group of syndromes like OSAS (Apnea, Hypopnea, RERAs). In another sequence, snoring leads to Uvular Oedema which feels like morning Obstructive Sleep Hypopnea Apnea Syndrome (ObSHAS). This leads to increase in Arterial Hypertension which causes daytime sleepiness.

There are a lot of complications in OSAS which maybe local complications in nose, mouth, and chest, or CVS complications like Erythema or Hypertension or psychological problems like dizziness or loss of consciousness or daytime sleepiness.

One of the most common problems is how to exactly detect the size and site of the obstruction of air flow. There are several methods like full history of the patient and the partner, full clinical examination, full radiological examination or fiber-optic endoscopic examination. The treatment is either medical or surgical according to the case.

**Keywords:** OSAS; Airway obstruction; Snoring; Apnea; Hypopnea; Pharyngoplasty; Veloplasty; Polysomnography

## Research Article

Volume 5 Issue 2 - 2016

**Aysser Bassaly<sup>1</sup> and Claudio Vicini<sup>2\*</sup>**

<sup>1</sup>Arab Academy for Science and Technology, Egypt

<sup>2</sup>Department of Head and Neck Surgery, University of Pisa, Italy

**\*Corresponding author:** Claudio Vicini, Department of Head and Neck Surgery, University of Pisa, 2330, Celincordia, Street, 47023, Cesena (FC), Italy, Fax: +39 0543 735660; Tel: +39 335 5326206; Email: claudio@claudiovicini.com

**Received:** December 12, 2015 | **Published:** December 29, 2016

**Abbreviations:** OSAS: Obstructive Sleep Apnea Syndrome; OSAHS: Obstructive Sleep Apnea Hypopnea Syndrome; BMI: Body Mass Index; AHI: Apnea Hypopnea Index; ESS: Epworth Sleepiness Scale; UPPP: Uvulopalatopharyngoplasty; UARS: Upper Airway Resistance Syndrome; RERAs: Respiratory Effort Related Arousals; CAPSO: Cautery Assisted Palatal Stiffening Operation

## Introduction

The Obstructive Sleep Apnea Syndrome (OSAS) is a big social and medical problem. About 60% of world population complaining from simple snoring up to severe serious stridor. The concept of understanding these phenomena of sleep disorders:

- 1.1. Basic Phenomena.
- 1.2. Respiratory Events.
- 1.3. Syndromes.
- 1.4. Consequences.
- 1.5. Complications.

## Basic phenomena

It depends on 2 major categories:

- a. Vibrations: Both superficial (mucosal with its intraluminal contents of saliva and mucus) or deep (muscles and lymph) which is responsible for noise (snoring and stridor).
- b. Obstruction (Phenomena of wall): The participation of mucus lymphoid tissue muscles. The luminal narrowing of airway in different phases of respiration and with vibration increases resistance. Both vibration and obstruction produce what is called Respiratory Events.

## Respiratory events

- i. Snoring.
- ii. RERAs.
- iii. Awake due to related respiratory effort.
- iv. Hypopnea.

- v. Minor Apneas: waking up with the sense of suffocation.

Different respiratory events contribute to form what is called Syndromes.

**Syndromes**

- a) Simple snoring.
- b) UARS.
- c) OSAS (Apnea, Hypopnea, RERAs).

Related syndromes: Obesity, Hypoventilation Syndrome, Stridor of multiple system atrophy.

**Consequences**

Which lead to local or systemic pathology in high frequency in majority of patients. Snoring leads to uvular edema in the morning, for the OSAHS Arterial Hypertension and excessive day time sleepiness.

**Complications**

- A. Local: uvular apoplexy.
- B. General: cardiovascular (stroke, acute myocardial infarction, arrhythmia, etc.).
- C. Neuropsychic: mood disturbance, irritability, etc.
- D. Others: choking, sexual impotence, car accident, etc.

**The most important characteristic signs in snoring**

- a. Rhythmic: acoustic phenomena synchronized with breathing cycle.
- b. Variable Physical Features.
- c. Mucosal Component.
- d. Luminal Component.

**What is Hypopnea?**

- 1) Self-Aggravation.
- 2) Mechanical damage (edema, neuropathy).
- 3) No general physical damage.
- 4) Cross-section reduction (Bernoulli effect).
- 5) No significant flow reduction.

**How to measure obstruction or flow reduction?**

- I. The sensor to detect absence of air flow: The oronasal thermal sensor.
- II. The sensor for hypopnea is nasal air pressure transducer.
- III. The sensor for respiratory effort is esophageal manometry.
- IV. The sensor for blood oxygen is pulse oximetry.

**To summaries the respiratory events according to severity**

- a) Snoring: no flow reduction, no desaturation, no arousals.
- b) RERAs: Flow reduction not more than 10%, arousals with EEG changes >10 seconds.
- c) Hypopnea: Flow reduction from 3%-70%, arousals with EEG changes >10 seconds, desaturation >4%.
- d) Apnea: Flow reduction more than 70%, arousals with EEG changes >10seconds, respiratory effort, paradoxical breathing.

**Obstructive Non Apneic Respiratory Events (ONARES)**

Obstructive Hypopneas and RERAs are clinically important as producing sleep fragmentation but are much more difficult to detect and classify than obstructive apneas [1].

Now let us differentiate between apnea and hypopnea

Apnea	Hypopnea
Flow Reduction >70%	Flow Reduction 30%-70%
EEG Arousals with or without O <sub>2</sub> Desaturation>4%	EEG Arousals Desaturation>4% with or without O <sub>2</sub> .
Duration > 10 seconds	Duration >10 seconds
Obstruction Respiratory Effort Paradoxical Breathing Snoring	Obstruction Respiratory Effort Paradoxical Breathing Flow Limited Snoring

**Respiratory Effort Related Arousals (RERAs)**

It is sequences of successive respiratory efforts with increasing endo esophageal pressure which leads to an EEG arousal, reducing flow less than 30% and no changes in heart rate or O<sub>2</sub> saturation. It is also defined as Clustering of respiratory act with progressive increase of respiratory effort and final arousal (by polysomnography), duration >10 seconds, flow reduction <30%, no PO<sub>2</sub> or heart rate changes (Guilleminault C et al. 1995).

**Distinguishing Criteria of Upper Airway Resistance Syndrome (UARS)**

**Snoring**

- a. Simple snoring, primary snoring disorders.
- b. Continuous snoring.
- c. No other complains.
- d. No O<sub>2</sub> desaturation.
- e. No airflow reduction.
- f. Family social problem.
- g. Evolution to OSAHS.

**Upper Airway Resistance Syndrome (UARS)**

- 1) Snoring daily.
- 2) Non obese female.
- 3) AHI <5.
- 4) PSG clinically pattern.
- 5) Repeated respiratory effort with arousal.
- 6) EEG arousals.

**How to deal with simple snoring**

Snoring is a noisy vibration of soft tissue structure of upper airways during inspiratory with or without expiration phase during sleep. Vibration also occurs in tonsils. Vibration can be classified according to site as palatal, pharyngoepiglottis, or luminal. Simple snoring has a mechanical damage (edema-neuropathic).

The AHI <10% and O<sub>2</sub> saturation a not less than 90%. The main problem appears when simple snoring increase to UARS or OSAHS.

**Diagnosis of snoring**

It can be done in outpatient room by full clinical examination, fiber optic endoscopy, also with partner discussion. For more details about the problem, we can do sleep endoscopy to detect exactly type, level and cause of snoring. We also can see pattern of obstruction if it is anteroposterior, lateral, circular or luminal.

Palatal surgery is a good solution for snoring and it has many types. It can be summarized to:

- A. LAUP (Laser Assisted Uvuloplasty).
- B. UPPP (Uvulopalatopharyngoplasty).
- C. UPF (Uvulopalato Flap).
- D. FPL (Lateral Pharyngoplasty).
- E. FPA (Anterior Pharyngoplasty).

The most accepted surgical technique to reduce snoring is Anterior Pharyngoplasty which is done by CAPSO [2,3].

**Discussion****Anterior pharyngoplasty**

This technique is mainly in snoring due to palatal anteroposterior narrowing. It was done by removing rectangular part of mucosa and submucosa between posterior margin of hard palate and upper pole edge of tonsil (about 1.5cm). Then we suture double parts (mucosa, submucosa-mucosa, submucosa) to narrow and stiffen the soft palate.

In most cases it was done with tonsillectomy

**Radiofrequency (RFVR):** Minimal Invasive-Easy Performance-Outpatient Technique-Local Anesthesia-Speed Execution-Low Thermal Tissue Effect.

**Injected snoroplasty:** 1943 Dr. Jerome Strauss injected sclerosing agent in soft palate with good results in noise reduction of snoring. A few years ago, Prof. Dr. Claudio Vicini, from Italy, has a lot of cases with good success of injecting snoroplasty.

Now, off-label technique A Recent Procedure for Palatal Stiffness by Muscle Fibers Protein Chemistry Denaturation by Injection a Sclerosing Materials. This technique has a very good value especially in mild cases of snoring or residual snoring after surgery.

**Characteristics of off-label procedure**

- a) 5 outpatient sessions.
- b) 20 -30 days interval between every session.
- c) VAS (Visual Analogue Scale): used to evaluate the results after every session and at the end of the cycle.
- d) Every session is about 20-30 minutes.
- e) Noise of snoring improved after first week.
- f) Very useful with other procedures [4].

**Veloplasty surgery**

Up until now, the Veloplasty Surgery is the best solution for chronic snoring because soft palate is responsible for about 80% of snoring patients. But, the biggest problem is how to choose the suitable candidate for surgery. It is not easy so we depend on a lot of methods (history physical examination, awake endoscopy, polysomnography, lateral x-ray of the skull, sleep endoscopy).

At first, careful assessment of the anatomy of the obstructed area to choose the best procedure

- i. Presence and size of tonsils.
- ii. Shape of uvula.
- iii. Shape and thickness of palatal pillar.
- iv. Presence of fibrosis after tonsillectomy.
- v. Presence and size of palatine tonsils.
- vi. Shape and size of tongue.

**Palatal implant****Indications**

- I. Snoring/Mild OSAS.
- II. Soft palate >2cm and <3cm.
- III. Small size tonsils.
- IV. BMI <32.

**Advantages**

- a. No post-operative pain.
- b. No morbidity.
- c. Easy technique.

**What is the implant?**

(Pillar) cylinders of woven polyesters about 18mm in length and 2mm in diameter inserted in the soft palate at the junction of the soft and hard palate for permanent stiffening. The effect is limited. It is used in mild case of OSAS.

**Radio frequency ablation**

By using radio frequency, sclerosing and fibrosis lead to stiffness but the efficacy is also limited but we can use this method as an assistant technique with uvuloplasty.

**C.A.P.S.O (Cautery Assisting Palatal Stiffness Operation) for the treatment of OSAS**

By: Zachary Wassmuth, MD, CPT, USA; Eric Mair, MD, LTC, USA; Daniel Loube, MD, MAJ, USA; David Leonard, MD, LCDR, USN; Bethesda, Maryland.

**The technique**

- 1) Topical anesthesia (Local Benzocaine Spray).
- 2) Local anesthesia: Injection of Lidocaine with epinephrine submucosally in the center of the soft palate.
- 3) Outline Dissection: by electro Cautery and coagulate edges of dissection.
- 4) Mucosal elevation: 2 cm central palatal mucosal flap from 1 cm of junction and gently dissected down to the uvula.
- 5) Mucosal dissection: uvular elevated and the muscular uvula ridge identified.
- 6) Uvular dissection: an inverted U-incision is made to dissect the mucosa of the uvular ridge. Cauterization to the mid line mucosa on the nasal service of the uvula will increase the stiffening effect.
- 7) Palatal stiffening: 2 to 3 weeks post-operative, the palate is stiffened and the snoring is greatly reduced with no voluntary palatal flutter.

**Pharyngoplasty**

At the beginning of the 80s, before the CPAP, the UPPP was the main solution of OSAS. Nowadays, Oropharyngeal surgery is the most common surgery for OSAS, because of its large spread and the fact that in 75% of OSAS patients there is a retro palatal obstruction.

UPPP now-a-days has a limited value because of its complications and recurrence of snoring and OSAS after 1 to 3years although there are extremely positive results in improving the polysomnographic parameters of OSAS patients after surgery.

**Difficult selection of patients**

- i. Multifactorial nature of OSAS.
- ii. Extreme anatomical and function variability of the upper airways.
- iii. Presence of multisite collapse.

- iv. Variable cephalometric parameters.

Therefore, it is so difficult to find the suitable candidate for this operation.

Endoscopic and manometric studies indicate the presence of retro palatal obstruction in 80% of failure in UPPP patients with possible worsening of AHI after UPP is due to excessive scar stiffening of the palate (de Vries, 2002).

The low therapeutic effectiveness of UPPP and the need to reduce the important and often irreversible side effects present in 50%-60% of patients have produced a trend towards a lower invasiveness of surgery-muscle conserving. The conservative techniques have reduced the risk of velo-palatal incompetence but the therapeutic results are not better ones. The studies of pathophysiology of Schwap on the importance of the collapse of the side wall in pharyngeal obstruction and with the use of sleep endoscopy allowed us to see that the collapse depends on the stability of the side wall and that the failure of UPPP depends largely on the persistence of the retro palatal obstruction. Therefore, we radically changed the surgical techniques not only to reduce the redundant tissue (morphological outcome) but also we must have to increase stabilizing effect of the lateral wall of pharynx (functional outcome).

The technique of endoscopic examination of the patient under sedation has radically changed the surgical approach to pharyngeal obstruction. This examination has allowed us to see the obstructive pharyngeal mechanism and to select the best patients by evaluating the degree of participation of the tongue-based epiglottis region that was not well estimated with the Mullar's maneuver. It also allowed us to understand how the pharyngeal obstruction in many cases is linked to the collapse of the side walls in patients with grade 1 and 2 tonsils. This data has significantly changed the method of selecting the surgical patient and completely changes the velo-pharyngeal surgical planning.

**Lateral pharyngoplasty: a new treatment for obstructive sleep apnea hypopnea syndrome****Steps**

- a) Tonsillectomy.
- b) Dissection of the palatopharyngeus muscle.
- c) Horizontal transection of the palatopharyngeus muscle.
- d) Palatal intramuscular tunnel.
- e) Superolaterally rotation of the medially-based muscular flap through the palatal tunnel and suture of the flap causing lateral soft tissue retraction.

**The summary of the technique**

We create an inter-palatal tunnel to the pterygoid plates without section of the palatal mucosa laterally, anteriorly and superiorly transposition of the muscle flap creates the basic line of scars that will be responsible for the stiffness of the palate and the stabilization of the lateral wall of the pharynx. All of this is done with complete palatal muscle and uvula preservation, with no swallowing disturbance (Figure 1 & 2).

We can also do this technique in a previous tonsillectomy patient by scarification of posterior pillars and by dissection of the palatopharyngeus muscle then preparation of two medially based muscular flaps by the horizontal section in this muscle and then by Supero-laterally rotation of flaps and suture on to soft palate musculature to perform lateral wall tension (Figure 3).

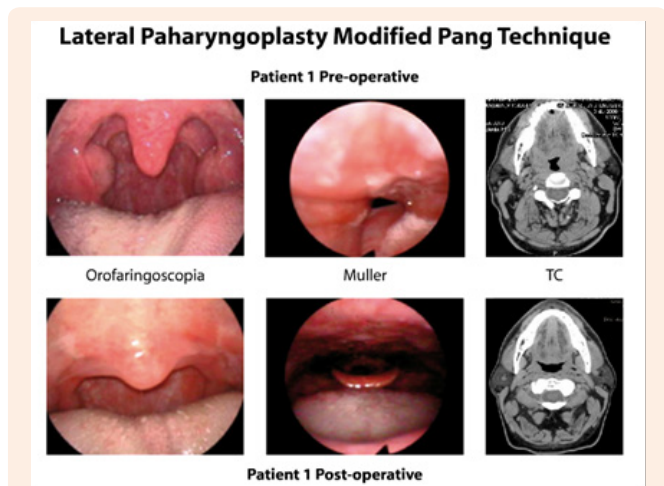


Figure 1: Lateral Pharyngoplasty modified pang technique.

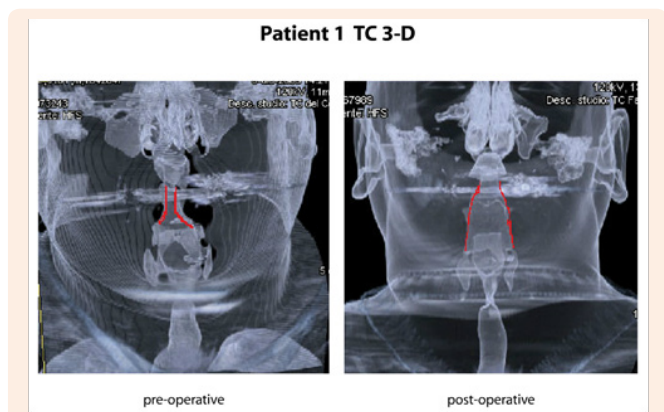


Figure 2: Patient 1 TC 3D.

**Advantages of lateral pharyngoplasty**

- a. Pharyngeal lumen expansion (increased lateral dimension).
- b. Stabilization of pharyngeal lateral walls (lateral soft tissue retraction).
- c. Reduction of palate and pharyngeal collapsibility (without palatine muscle damage).
- d. Minimal effects on swallowing and pharyngeal comfort.
- e. Reduction of CPAP usage.
- f. High effectiveness with all patients with small tonsils and lateral pharyngeal walls collapse.

**Lateral Pharyngoplasty in previous Tonsillectomy**

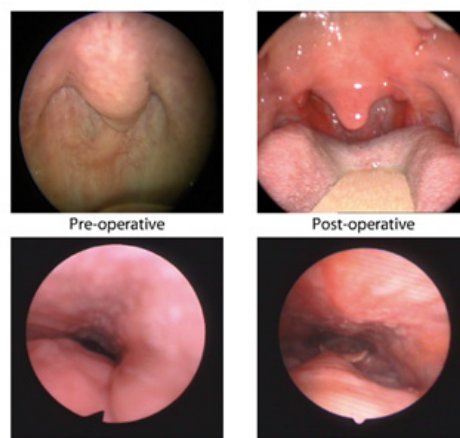


Figure 3: Lateral pharyngoplasty in previous tonsillectomy.

**The perfect candidate for this operation**

- A. AHI 12 ->100
- B. BMI <30
- C. Redundant soft palate and uvula and tonsils (1-4) by oropharyngoscopy.
- D. Retropalatal obstruction (Muller’s maneuver).
- E. Lateral wall collapse-tongue base and larynx, stable during sleep endoscopy.
- F. Cephalometric examination-no micromandibulia or low hyoid.
- G. By CT of the pharynx, no reduction of airway lumen due to thickening of the lateral walls.

**Hyoid suspension**

Hyoid bone plays a central role in the upper digestive ways and consequently in the dynamics of both respiratory and hypopharyngeal swallowing. The main purpose of the hyoid suspension is to increase the space at the level of tongue bas and also at the level of the side walls. The hyoid bone structure shows a central anterior body, two strong posterior extensions (big horn) and two small superior apophyses (small horns).

We can classify lateral pharyngeal wall by using hyoid bone, the portion above is oropharyngeal (between hard palate and the hyoid) and hypopharyngeal (below the hyoid). The oropharyngeal is also divided into palatal and lingual portion.

**Classification on the basis of hyoid surgery**

- I. Interruptive intervention: the purpose is to obtain transverse pharyngeal expansion (hyodoplasty).
- II. Non-interruptive intervention: through sutures for suspension to adjacent structure which leads to the repositioning of the hyoid (hyoid suspension).

**The technique of hyoid suspension (based on Claudio Vicini, 2007, Snoring and OSAS surgery)**

- a) Draw the landmarks on the inferior edge of the hyoid bone and the thyroid notch. Between these two lines, we will perform our incision.
- b) We dissect the body of the hyoid bone close to periosteum, spreading the muscles posteriorly.
- c) We dissect along the midline separating sternohyoid and thyrohyoid muscles to obtain full exposure of thyroid cartilage.
- d) We apply four sutures; each one passing through the thyroid cartilage and then behind and close to the hyoid bone.
- e) We finish the thyrohyoid-pxy by tightening the four sutures and moving inferiorly and anteriorly the hyoid bone towards the thyroid cartilage.

The hyoid surgery is performed as a part of the treatment of OSAS in multi-level obstruction cause.

**The selection criteria for the patients of hyoid suspension**

- i. OSAS clinically and PSG demonstrated.
- ii. CPAP refusal.
- iii. Lateral wall collapse evident by Muller's maneuver or sleep endoscopy.

**Advantages**

- a) The hyoid suspension is effective in reducing the average AHI from 34 preoperative to 15.6 postoperative.
- b) Simple, quick and easy procedure in multi-level surgical approach.
- c) Thyrohyoid-Pexy is probably the best balanced hypopharyngeal procedure in terms of costs/efficacy ratio.

**TORS (Trans-Oral Robotic Surgery)**

It is a new Era in snoring surgery for a large reduction of the tongue base and epiglottis surgery.

**The criteria of selected patients for TORS of tongue bas are**

- a. Mild to severe OSAHS with AHI >20.
- b. Excessive daytime sleepiness with ESS >10.
- c. Significant tongue base obstruction.
- d. With or without epiglottis obstruction (supraglottic area prolapse).
- e. Good oropharynx exposure.

The aim of TORS in sleep disordered breathing surgery consists of 2 steps: the reduction of tongue base and supraglottoplasty.

The main problem in TORS is its high cost but compared to the traditional trans-cervical procedure cost, it doesn't differ. Reduction of tongue base with TORS is 3-4 times faster and

hospital stay can be reduced by about 1/3 compared to trans-cervical surgery. At the end TORS is a feasible, safe, effective and reproducible procedure.

**Maxillo-mandibular advancement in the treatment of OSAS**

It is one of the surgeries done especially in OSAS patients which detected facial skeleton abnormalities (Facial Dysmorphoses) and in patients with failure of CPAP and nature therapy (treatment of obesity, positional therapy). The Maxillo-mandibular advancement has been shown to be able to expand the pharyngeal airspace and hypopharyngeal by the physical expansion of the facial skeletal structure.

The surgical approach is indicated in patients with moderate to severe OSAS who don't tolerate CPAP treatment, with or without facial deformity. The results are very good in improving fatal OSAS patient's but this advantage is not:

- 1) An easy operation (needs a well-trained team).
- 2) Bleeding.
- 3) Infection.
- 4) Mal-occlusion.
- 5) Nerve injury (alveolar nerve).

**Oral appliance (OA)****Indications**

- a) Primary snoring or UARS.
- b) Mild to moderate obstructive apnea: (AHI up to 30 per hour), Positional (supine), BMI (30 kg/m<sup>2</sup>).
- c) Patient tolerance: denture or bite.
- d) Patient with stable occlusion.
- e) Patient refuses CPAP.
- f) Patient OSAHS of any severity with all previous treatment failure [5].

**Advantages of OA**

- a. Noninvasive procedure.
- b. Rapid execution.
- c. Excellent patient compliance.
- d. Several therapeutic options.

**Disadvantages of OA**

- i. Dry mouth or excessive flow.
- ii. The movement of protrusion can cause jaw and muscle problem.
- iii. Cephalometric changes.
- iv. Dental movements.

## Anesthesia for OSAS

The OSAS patient is a big problem for the anesthesiologist because he identifies a group of patients at high risk of respiratory complications especially in the postoperative period.

Most patients are complaining from difficult intubation due to narrowing of the upper airways. We must avoid opioids as a pain control in any stage of the anesthesia.

## Conclusion

Nowadays, Snoring and OSAS are not a big problem. There are a lot of solutions to overcome the problem from easy procedures to ultra-major ones according to the severity of the problem.

## Acknowledgments

Special thanks to both Prof. Dr. Claudio Vicini and Prof. Dr. Filippo Montevercchi, Morgagni-Pierantoni of Forli.

## References

1. Cracowski C, Pépin JL, Wuyam B, Lévy P (2001) Characterization of obstructive nonapneic respiratory events in moderate sleep apnea syndrome. *Am J Respir Crit Care Med* 164(6): 944-948.
2. Wassmuth Z, Mair E, Loube D, Leonard D (2000) Cautery-assisted palatal stiffening operation for the treatment of obstructive sleep apnea syndrome. *Otolaryngol Head Neck Surg* 123(1 Pt 1): 55-60.
3. Pang KP, Tan R, Puraviappan P, Terris DJ (2009) Anterior palatoplasty for the treatment of OSA: three-year results. *Otolaryngol Head Neck Surg* 141(2): 253-256.
4. Brietzke SE, Mair EA (2001) Injection snoroplasty: how to treat snoring without all the pain and expence. *Otolaryngol Head Neck Surg* 124(5): 503-510.
5. Thorpy M (1a995) Practice parameters for treatment of snoring and obstructive sleep apnea with oral appliance. *Sleep* 18(6): 511-513.