

Primary Large B-Cell Lymphoma of the Base of Tongue

Abstract

We describe a 72 year old female who presented with a bulky lesion involving the base of tongue which was diagnosed as diffuse large mantle B-cell lymphoma. Despite the considerable size of the lesion, neither local signs nor symptoms were complained, unless a change of her voice and a slight respiratory obstruction from three months. The patient experienced no B symptoms (fever, weight loss, night sweats). The woman complained the unaesthetic appearance of a single laterocervical adenopathy (III level), on the right side, from two months. Blood parameters were normal (Lactate Dehydrogenase 172 U/l, WBC 5,8 μ /L). The fiber optic endoscopic examination revealed a fungating mass covered by smooth mucosal tissue originating from the base of tongue and extended laterally to the tonsillar fossae and posteriorly towards the pharyngeal wall; the vallecula were entirely occupied and the epiglottis couldn't be notice. Chest X-rays resulted negative. The MRI revealed a remarkable thickening of the pharynx at the level of the lingual tonsil which causes considerable limitation of pharyngeal lumen at a supraglottic level. Such lesion appeared homogeneous after contrastografic enhancement as well as the laterocervical adenopathy, which was excised without any complication. Histological analysis demonstrated a subverted lymph nodal architecture, irregular nuclei and a nodular/mantle growth pattern. Immunohistochemical phenotype was CD20+, CD5+, Cyclin D+, Bcl2+, CD23-, CD10- and Bcl6-. A total body PET scan showed no lymphadenopathies in any other region. The patient was classified as IIA according to the Ann Arbor classification and was treated with chemotherapy which consisted of Bendamustin-Rituximab twice a month for six months. After these cycles of chemotherapy, the lesion was completely disappeared. Clinical condition of the patient after the treatments was uneventful and she is currently at the 20th month of follow-up. We want to report an uncommon case of a base of tongue Non-Hodgkin lymphoma with an almost asymptomatic clinical presentation.

Keywords: Base of tongue; Lymphoma; Extra nodal lymphoma; B-cell lymphoma; Non-Hodgkin; Oropharynx; Neck mass; Clinical presentation; Asymptomatic lesion; Dysphagia; Cyclophosphamide; Hydroxydaunorubicin; Oncovin; Prednisone; Oral Cavity

Abbreviations: BOT: Base of Tongue; CHOP: Cyclophosphamide Hydroxydaunorubicin Oncovin Prednisone; NHL: Non-Hodgkin Lymphoma

Introduction

Non-Hodgkin lymphoma (NHL) represents the third most common group of malignant lesions of the oral cavity, following squamous cell carcinomas and salivary gland neoplasms. It accounts for 3-5% of all malignant lesions of the oral cavity [1]. Further, only 1% of all lymphomas are primary oral cavity lymphoma. Non-Hodgkin's lymphoma of the tongue is extremely rare. It can arise from Waldeyer's ring, including the tonsils, nasopharyngeal lymphoid tissue, soft palate, and BOT [2].

Case Presentation

A 72-year-old woman was admitted to the Head and Neck Surgery Department of our hospital with an asymptomatic growing of a large mass involving the base of tongue. The medical and family histories were negative for significant disorders. The patient complained a slight change of her voice from three months and the appearance of a lymphadenopathy in the neck,

on the right side, from two months. No hepatosplenomegaly was detected on physical examination. The Eastern Cooperative Oncology Group (ECOG) performance status of the patient was 2. The results of laboratory analyses obtained on admission were as follows: White Cell Count, 5.8 μ /L, hemoglobin, 13.0 g/dL, Lactate Dehydrogenase 172 U/L (normal range 160-580), platelet count 225,000 μ /L, calcium 10.3 mg/dl, creatinine 0.9 mg/dl.

Inspection of the oral cavity revealed a large mass lesion. In the fiber optic endoscopic examination such lesion severely limited the oropharyngeal lumen (Figure 1). MRI scan showed lymphadenopathies in the jugular and submandibular regions, bilaterally. Furthermore, it revealed a remarkable thickening of the pharynx at the level of the lingual tonsil which caused a considerable limitation of pharyngeal lumen at the supraglottic level (4cm x 3.8cm x 2.46cm) (Figures 2 & 3). A total body positron emission tomography (PET) was performed as part of the staging work-up and there were no other lesions. The laterocervical lymphadenopathy was excised with no complications. Histological analysis demonstrated a subverted lymph nodal architecture, irregular nuclei and a nodular/mantle growth pattern (Figure 4). Immunohistochemical phenotype was CD20+, CD5+, Cyclin D+,

Case Report

Volume 3 Issue 5 - 2015

Michele Busoni*, Isabella Bozzini and Luigi Raimondo D'Ottavi

Department of Otolaryngology, Ospedale Cristo Re Hospital, Italy

***Corresponding author:** Michele Busoni, Via il Prato 11-50123-Firenze, Italy, Tel: 0039 3284430014; Email: michelebusoni@gmail.com

Received: June 05, 2015 | **Published:** November 17, 2015

Bcl2+, CD23-, CD10-, Bcl6-, growth fraction (Ki67) ≈20%. The patient was treated with chemotherapy which consisted of three courses of Bendamustin-Rituximab every 28 days for 6 months followed by 2 years of maintenance therapy. After chemotherapy, the lesion was completely disappeared.

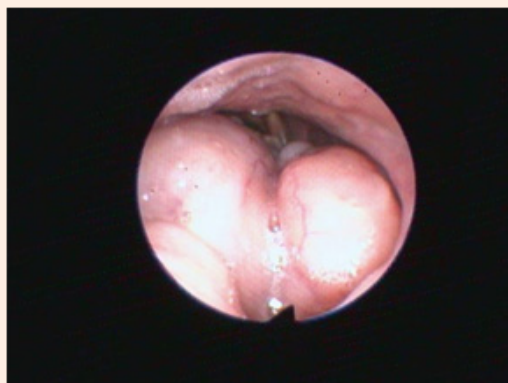

Figure 1: Base of tongue lesion (flexible endoscopic view).

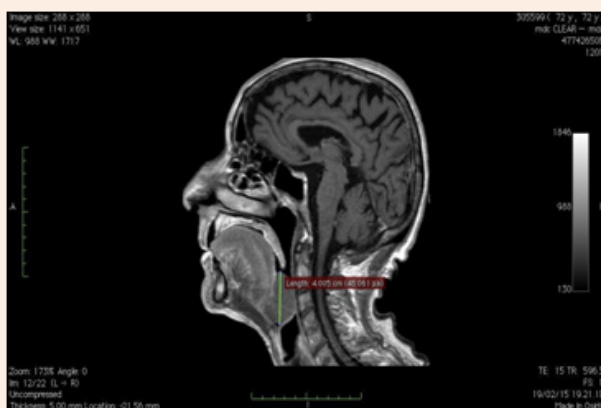


Figure 2: Sagittal view of the lesion at the MRI.

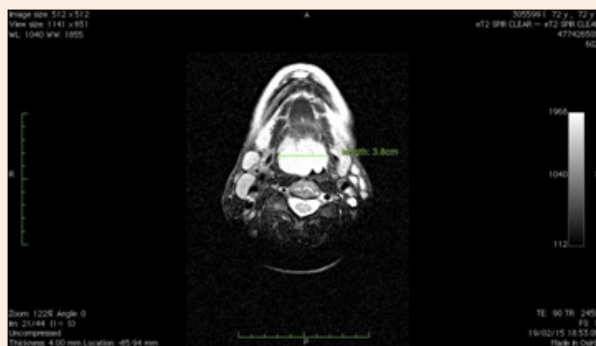


Figure 3: Axial view of the lesion at the MRI.

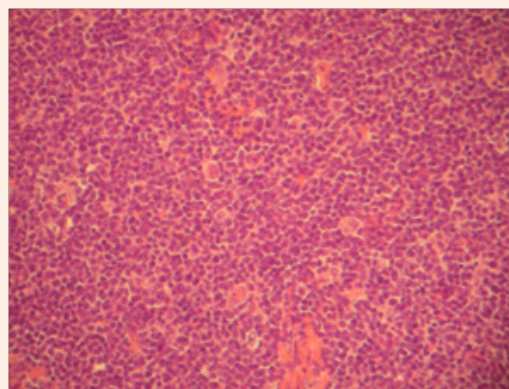


Figure 4: Histological analysis showing atypical lymphoid cell proliferation, irregular nuclei and nodular/mantle growth pattern.

Discussion

Only a few cases of primary lymphomas in the oral cavity have been reported in the English literature [3-6]. The largest case series encountered twenty-six cases of large B-cell lymphoma in the base of tongue retrieved in 9 years, with the aim to illustrate a practical approach to the identification of prognostically important subtypes of large B-cell lymphomas [7].

20 to 30% of Non Hodgkin lymphoma arise from extra nodal disease. The head and neck is the second most common region for extra nodal lymphoma after the gastrointestinal tract [3]. Location of oral lymphomas is more frequent in masticatory mucosa than in movable mucosa; the lingual and buccal mucosa are rarely involved [8], whereas the gingival vestibule and Waldeyer's ring seem to be the most frequent site of occurrence [9]. Little is known about the etiology of primary BOT lymphoma, although some cases have been reported in association with the acquired immune deficiency syndrome [10].

Clinically, BOT lymphomas may present with local swelling, pain or discomfort, change of voice and, occasionally, the tumor may cause upper airway obstruction. Despite the large volume of the primary lesion, our patient was almost asymptomatic, complaining only the unaesthetic appearance of a lump in the neck and a slight change of her voice. Despite the RMI revealed signs of cortical-subcortical atrophy and localized gliotic foci, the patient completed with good success the mini mental state examination test (score 26).

The combination of bendamustine and rituximab (BR) has been shown to be a well-tolerated and an active treatment regimen. The randomized, non inferiority (NI), global, phase 3 BRIGHT study evaluated the efficacy and safety of bendamustine plus rituximab (BR) vs a standard rituximab-chemotherapy regimen (rituximab plus cyclophosphamide, doxorubicin, vincristine, and prednisone [R-CHOP] or rituximab plus cyclophosphamide, vincristine, and prednisone [R-CVP]) for treatment naïve patients with indolent non-Hodgkin's lymphoma or mantle cell lymphoma. BR was non inferior to R-CHOP/R-CVP, as assessed by the primary end point of complete response rate (31% vs 25%, respectively; P=.0225 for

NI [0.88 margin]). The overall response rates for BR and R-CHOP/R-CVP were 97% and 91%, respectively ($P=.0102$) [11]. The potential benefit of maintenance therapy for MCL, in particular rituximab, has been hotly debated. The German Mantle Cell Group randomized 560 older MCL patients to R-CHOP or to fludarabine, cyclophosphamide, and rituximab induction therapy, which was followed by a second randomization to maintenance therapy with either rituximab or IFN. Results showed that maintenance rituximab resulted in better progression-free survival compared with IFN in patients who were initially treated with R-CHOP but not in patients who were treated with purine analogue-containing regimens; Bendamustine plus rituximab was better tolerated than R-CHOP. Moreover, among patients treated with R-CHOP induction therapy, maintenance therapy with rituximab significantly improved overall survival (4-year overall survival rates of 87% vs 63% with IFN; $P = .005$) [12].

Conclusion

Base of tongue NHL is very uncommon, and all reported studies include a small number of patients. It should always be considered in differential diagnosis of benign and malignant lesions in this region. Differential diagnosis includes metastatic tumors in the tongue, melanomas, poorly differentiated squamous cell carcinomas, poorly differentiated adenocarcinomas, and rare tumors such as neuroblastomas, rhabdomyosarcomas and Ewing's tumor [13]. We report this case for its unique presentation, as a bulky non-ulcerated submucosal mass of the base of tongue, with change of voice and slight respiratory obstruction as presenting symptom.

References

- Zapater E, Bagan JV, Carbonell F, Basterra J (2010) Malignant lymphoma of the head and neck. *Oral Dis* 16(2): 119-128.
- Lee SJ, Suh CW, Lee SI, Kim WS, Lee WS, et al. (2014) Clinical characteristics, pathological distribution, and prognostic factors in Non-Hodgkin lymphoma of Waldeyer's ring: nationwide Korean study. *Korean J Intern Med* 29(3): 352-360.
- Terada T (2011) Primary non-Hodgkin B-cell lymphoma of the tongue. *Br J Oral Maxillofac Surg* 49(5): e18-19.
- Teh CS, Jayalakshmi P, Chong SY (2014) Waldeyer ring lymphoma: a case series. *Ear Nose Throat J* 93(9): E22-E25.
- Singh A, Sood N, Kaur H, Garg B, Munjal M (2014) Primary diffuse large B cell lymphoma of the base of tongue: a rare entity. *Am J Otolaryngol* 35(3): 435-438.
- Hmidi M, Touiheme N, Elboukhari A, Kettani M, Elmejareb C, et al. (2012) Primary B cell lymphoma of the tongue: a case report. *Pan Afr Med J* 12: 5.
- Owosho AA, Bilodeau EA, Surti U, Craig FE (2014) Large B-cell lymphoma of the base of the tongue and oral cavity: a practical approach to identifying prognostically important subtypes. *Oral Surg Oral Med Oral Pathol Oral Radiol* 118(3): 338-347.
- Zanakis SN, Kambas I, Gourlas PG (1992) A non-Hodgkin's lymphoma in the buccal mucosa. A case report. *Oral Surg Oral Med Oral Pathol* 74(3): 340-342.
- Piattelli A, Di Alberti L, Artese L (1996) Non-Hodgkin's lymphoma of the tongue: a case report. *Eur J Cancer B Oral Oncol* 32B(3): 207-209.
- Delecluse HJ, Anagnostopoulos I, Dallenbach F, Hummel M, Marafioti T, et al. (1997) Plasmablastic lymphomas of the oral cavity: a new entity associated with the human immunodeficiency virus infection. *Blood* 89(4): 1413-1420.
- Flinn IW, Van der Jagt R, Kahl BS, Wood P, Hawkins TE, et al. (2014) Randomized trial of bendamustine-rituximab or R-CHOP/R-CVP in first-line treatment of indolent NHL or MCL: the BRIGHT study. *Blood* 123(19): 2944-2952.
- Rummel MJ, Niederle N, Maschmeyer G, Banat GA, von Grunhagen U, et al. (2013) Bendamustine plus rituximab versus CHOP plus rituximab as first-line treatment for patients with indolent and mantle-cell lymphomas: an open-label, multicentre, randomised, phase 3 non-inferiority trial. *Lancet* 381(9873): 1203-1210.
- Yaris N, Kutluk T, Akcoren Z, Yalcin B, Gogus S, et al. (1998) Primary non-Hodgkin lymphoma of the tongue in a child. *Med Pediatr Oncol* 30(6): 372-373.