

Spontaneous tonsillar hemorrhage

Abstract

A case report of tonsillar hemorrhage.

Keywords: spontaneous tonsillar hemorrhage, measles, infectious mononucleosis, telangiectasia, adenoidectomy, tonsillectomy

Volume 2 Issue 5 - 2015

Menwal Harb

Department of Otolaryngology, American Crescent Health Care Center, UAE

Correspondence: Menwal Harb, Department of Otolaryngology, American Crescent Health Care Center, Abu Dhabi, UAE, Tel 00971 528046377, Email menwalh@yahoo.com

Received: November 20, 2014 | **Published:** June 06, 2015

Introduction

Spontaneous tonsillar hemorrhage is a rare event, and is defined as continuous bleeding for more than one hour, or more than 250mL of blood loss regardless the duration of bleeding. Most of these cases have been the result of infectious tonsillitis. There are reported cases of spontaneous tonsillar hemorrhage in medical literature associated with bacterial infection, measles viral infection, infectious mononucleosis, peritonsillar abscess, less frequently, vascular malformations, aneurism or pseudoaneurism of the carotid artery, Von Willebrand disease and local or regional cancer.

In a review of literature, Lourenco et al.¹ found 21 cases of spontaneous tonsillar hemorrhage, resulting from acute tonsillitis, cases of spontaneous hemorrhage have been reported in peritonsillar abscess, mostly when spontaneous drainage occurred during the pre-antibiotic era. The prevalence of hemorrhage associated with infectious mononucleosis is 3-6.9%, of these 2.2% presented oropharyngeal hemorrhage. Thrombocytopenia is associated with this condition, but hemorrhage may result only due to local inflammation, necrosis and erosion of superficial tonsillar blood vessels.²

In measles, hemorrhagic complications are uncommon, however there is a rare variant known as hemorrhagic measles that affects mostly immunocompromised patients.³ Tonsillar hemorrhage (Figure 1) is a rare finding in Von Willebrand disease, there are two cases reported in literature where the tonsillar hemorrhage was the first manifestation of the disease.⁴

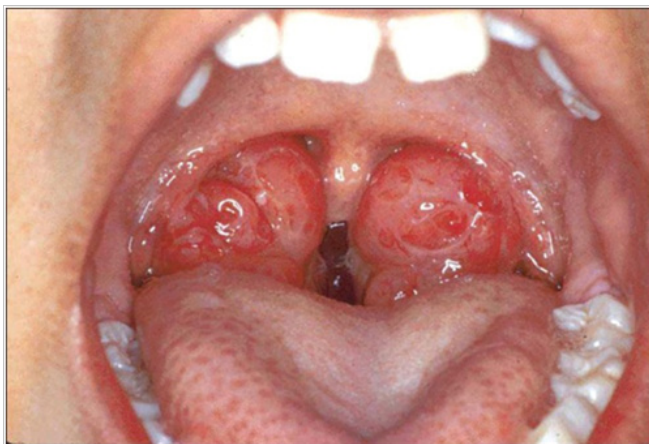


Figure 1 The tonsillar hemorrhage.

Case report

A 17years girl with a complain of a recurrent sudden mouth bleeding, persists for about one minute and resolves spontaneously, there is no medical problems, no history of surgeries, with regular menstrual periods. No teeth problems, no history of nasal bleeding, hemoptesis, hematuria, or inferior intestinal bleeding. All blood tests are normal, except Hb: 10.5 g/dl (Note: the bleeding began at the first attack after acute tonsillitis which was diagnosed by another specialist). The physical examination is within normal limits, without bleeding, and without any suspected area to be the source of bleeding. A Pan endoscopy was done for: Nasopharynx, Larynx and Hypopharynx, Upper digestive endoscopy, and Diagnostic Bronchoscopy by a company with Gastroenterologist, and Pulmonologist. It was normal except mild degree of esophagitis at the lower 3-4cm of the esophagus.

But under treatment of Omeprazole 20mg once daily. No bleeding for 3months, with normal activities and normal life style. Then the bleeding occurred again, with erosive tonsillitis, with bleeding from the left superior tonsillar pole. She admitted in the hospital, with intravenous antibiotics, observation, gurgling with 3% of Hydrogen peroxide solution, and a Tonsillectomy was done after 10days of the attack.

Histopathologic examination

Tonsillar tissue with signs of chronic inflammation. The final diagnosis is Spontaneous Tonsillar Hemorrhage.

Discussion

Most of these patients are aged between 20 to 30years. There is no gender predominance. The average duration of symptoms is 2 to 5days. In our case the bleeding lasts for about one hour at every attack, with a very small amounts of blood mixed with saliva at the rest of the day. The superior tonsillar pole is the most common site of bleeding as in our case.

On being examined, half of these patients present active bleeding or blood clots, while at the first attack of our case, the examination was negative with no site of bleeding, and became clearly noted that the source is the left superior tonsillar pole at the second attack. According to Rios et al.,⁵ recurring tonsillitis is the main predisposing factor leading to spontaneous hemorrhage, with the infection as the main etiology, our patient has chronic cryptic tonsillitis, with acute attack. Treatment includes local control of bleeding with chemical cauterization, electro coagulation or nebulizing with adrenaline, in our case the treatment was local control, then Tonsillectomy.⁶

Conclusion

Acute bacterial tonsillitis is currently the most important cause of spontaneous tonsillar hemorrhage. The incidence is 1.1%. The etiology of bleeding should be investigated. Exams such as a complete blood count, coagulation tests are not the ideal exams for final diagnosis, but may be useful. Most authors recommended local control of bleeding, tonsillectomy is rarely indicated, in our case the bleeding reoccurred and didn't resolved by conservative treatment, so it was treated by Tonsillectomy.

Consent

Consent was taken from the patient and her parents for publication of this case as a case report.

Acknowledgments

None.

Conflicts of interest

Author declares there are no conflicts of interest.

Funding

None.

References

1. Lourenço EA, Almeida CIR, Pinto CAL, et al. Hemorragia Espontânea de Amígdalas Palatinas. Relato de Dois Casos. *Rev Bras de Otorrinolaringol*. 1991;57(1):36–39.
2. Koay CB, Norval C. An Unusual Presentation of an Unusual Complication of Infectious Mononucleosis: Haematemesis and Melena. *J Laryngol Otol*. 1995;109(4):335–336.
3. John DG, Thomas PL, Semerano D. Tonsillar haemorrhage and measles. *J Laryngol Otol*. 1988;102(1):64–66.
4. Gumprecht TF, Cichor JV. Otolaryngology and von Willebrands Disease. *Arch Otolaryngol*. 1981;107:491–493.
5. Rios OAB, Lessa RM, Grwnato L. Hemorragia Espontânea da Amígdala. Relato de Caso e Revisão da Literatura. *Rev Bras Otorrinolaringo*. 1999;1 65:457–460.
6. Rowlands RG, Hicklin L, Hinton AE. Novel Use of a nebulised Adrenaline in the treatment of secondary oropharyngeal haemorrhage. *J Laryngol Otol*. 2002;116(2):123–124.