

Canalplasty in revision radical cavity surgery using a meatal t- skin flap technique

Abstract

Background: In literature no technique of canalplasty in revision radical cavity surgery has been reported. Yet, inadequate canalplasty is a known contributing factor in troublesome cavities and should be addressed when necessary.

Methods: Retrospective cohort analysis of patients undergoing revision radical cavity surgery in which a canalplasty was indicated. All received a canalplasty using a skin flap technique which enables maximal preservation of the delicate epithelial lining of the osseous external auditory canal (OEAC).

Results: The described canalplasty technique resulted in quick re-epithelialization (median 8.9 weeks) and dry ears. Only one minor complication was seen.

Conclusions: We describe a canalplasty technique that can be used in revision radical cavity surgery and show it is safe and effective. This technique can easily be combined with radical cavity obliteration.

Keywords: canalplasty, ear canal, radical cavity, surgery, otologic surgical procedures, surgical flaps

Volume 1 Issue 1 - 2014

Van Spronsen E, Waterval JJ, Geerse S, Kos IEM, Dreschler WD, Ebbens FA

Department of Otorhinolaryngology, Academic Medical Center, Netherlands

Correspondence: Van Spronsen E, Department of Otorhinolaryngology Head & Neck Surgery, Academic Medical Centre, Meibergdreef 9, 1105 AZ Amsterdam, Netherlands, Tel +31-20-5663789, Fax +31-20-5669573, Email e.vanspronsen@amc.uva.nl

Received: November 15, 2014 | **Published:** December 23, 2014

Introduction

Open cavity mastoidectomy is a commonly performed operation for chronic otitis media with or without cholesteatoma. Radical cavities, however regularly remain troublesome cavities¹ resulting in clinician dependence as the self cleansing mechanism of the osseous external auditory canal (OEAC) is disrupted.^{2,3} A multifactorial etiology for these troublesome cavities has been mentioned by many authors and revision surgery has been shown to be very effective.⁴⁻⁷

Well known etiologies of troublesome cavities include a high facial ridge, an inadequate meatoplasty and persistent cell tracts. Less frequently, an inadequate canalplasty is mentioned. Bercin et al demonstrated that an inadequate canalplasty is present in 67% of their troublesome cavities.⁶ When adequate, a canalplasty successfully removes the excess of bone of the tympanic bone segment of the OEAC resulting in a straight and wide OEAC, thereby facilitating the postoperative care and the self cleansing property of the OEAC.⁷ Maximal preservation of the epithelial lining of the OEAC will facilitate fast healing. In addition, the unique properties of the epithelium of the OEAC will be preserved.⁸

In radical cavities, three regions of the OEAC which should be considered for revision surgery can be identified (Figure 1E, hatched area): the anterior curvature, the pretympenic recess and the epitympenic remnant of the posterior OEAC. In this paper, we propose a novel and simple method for canalplasty in revision radical cavity surgery using a T-flap meatal skin flap. The procedure in our series was performed during reconstructive surgery of the posterior canal wall and subsequent obliteration of the mastoid.

Materials and methods

Patients and statistics

We retrospectively analyzed the medical records of 46 consecutive individuals with a draining radical cavity undergoing revision surgery including a canalplasty procedure. All operations were

performed by the first author of the manuscript in the Academic Medical Center, Amsterdam, the Netherlands, a tertiary center for otorhinolaryngology. Patient characteristics, time to heal (i.e. time to complete epithelialization), complication rate, type of complications and success rate (i.e. a dry and waterresistant ear) were recorded. *Mann-Whitney U tests* were performed to check for significant changes from baseline in time to heal in relation to smoking habits and the frequency of prior surgery. We decided to use a non-parametric test as sub analysis of data was performed on unequal size low sample groups. *P* values of less than 0.05 were considered statistically significant. As this study was a retrospective cohort analysis of regular care no IRB was necessary as in the Netherlands such research does not need ethical committee review by Dutch law as long as the presented data is not reducible to patients. Informed consent was obtained in all cases.

Surgical technique

All canalplasty procedures were performed in combination with the obliteration of the mastoid bowl and reconstruction of the posterior canal wall using cartilage, hydroxyapatite and a midtemporal flap (which is a slightly modified technique as was described earlier by Yung et al.⁹ All steps are described as if a right ear is involved. Briefly, one starts with a post-aural incision and the creation of a periosteal flap, thus allowing external auditory canal exposure via a lateral incision (Figure 1A). Another incision allows inspection of the epithelial lining of the cavity and the preparation of two skin flaps (Figure 1B). The quality of the skin in a radical cavity is variable. If the cavity is mainly mucosal, inevitably the skin flaps will become shorter as one should take care not to include the mucosal lining in the skin flaps. Next, one could choose to remove all remaining cell tracts of the mastoid first or one could decide to proceed directly with a third incision which is positioned anteriorly and just lateral of the tympanic membrane remnant and facial nerve and defines the medial border of the T-flap (Figure 1C). Preferably, good exposure of and direct view on the remnant of the tympanic membrane and the suspected position of the facial nerve is realised. Using sharp dissection, flaps are created in areas where the skin is not in direct contact with bone.

Blunt dissection is easily performed in areas where skin is in direct contact with a bony surface. Both inferior and superior sides of the flap are prepared (Figure 1B). Then, using Rosen and Williger raspatories, the anterior section of the flap is prepared until the entire tympanic bone is exposed and the T-shape is revealed (Figure 1D). Next, this anteriorly pedunculated flap is fixated outside the operation field, thereby achieving maximum skin preservation (Figure 1E). Finally, a medial circular skin flap is created using a Rosen raspatory. Now, one can remove the excess of bone in all problem areas (hatched area) using the burr in a circular fashion (Figure 1F). One should take care not to open the mandibular joint and to sufficiently lower the ear canal to expose the entire tympanic annulus. After enlargement of the OEAC, the medial skin flap is repositioned, thereby allowing adequate alignment of skin within the new bony ear canal (Figure 1G). Several partial incisions can be made or in some cases the tympanic membrane can be reconstructed using fascia.

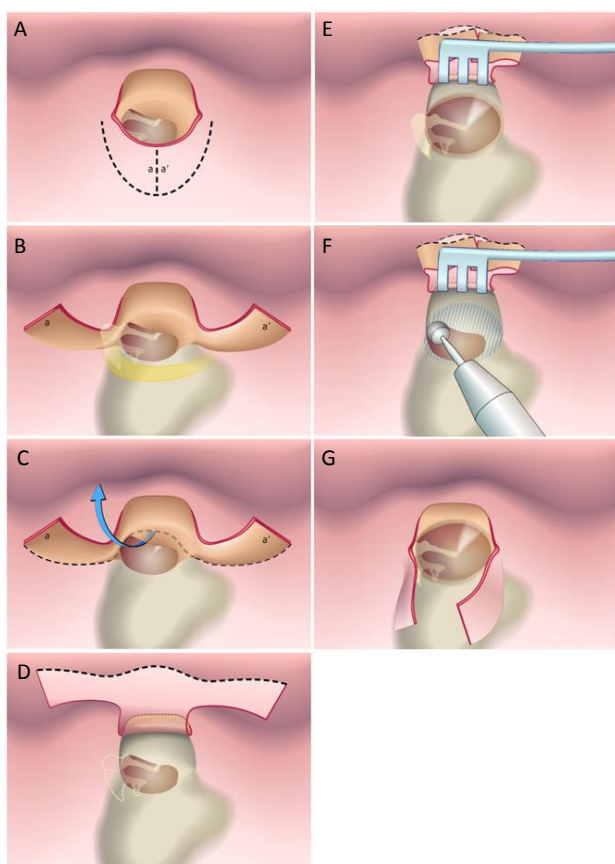


Figure 1 T-Flap technique, step by step.

Figure 1A Canal exposure via a lateral incision. The incision between a and a' allows inspection of the epithelial lining of the cavity and the preparation of two skin flaps.

Figure 1B Preparation of skin flap a and a'.

Figure 1C A third – anterior – incision, just lateral to the tympanic membrane defines the medial border of the T-flap.

Figure 1D Using sharp and blunt dissection, the flap is created over the mastoid cavity and the entire tympanic bone, revealing the T-shape.

Figure 1E and **Figure 1F** A medial circular skin flap is created, allowing the removal of bone excess in all problem areas (hatched area).

Figure 1G The medial skin flap is repositioned, thereby allowing adequate alignment of skin within the newly formed bony ear canal or newly formed cavity.

Although in our case series, the canalplasty procedure as described above was performed in combination with reconstruction of the posterior wall with cartilage and a midtemporal flap and obliteration of the mastoid cavity with hydroxyapatite, one can use the technique in combination with many other procedures such as partial obliteration of a radical cavity with a Palva flap or bone pate or revision radical cavity surgery. Whichever procedure is chosen, after completing the work in the mastoid cavity, the T-flap is to be repositioned (Figure 1G). Using sponges and gauzes, its delicate skin is kept in place. Sometimes it is needed to excise excess skin as the resulting cavity (i.e. canal) may be much smaller in size. Postoperatively, special care should be taken not to displace the skin flaps as antibiotic gauzes are changed every fortnight until complete re-epithelialization of the OEAC has occurred.

Results

Between 2008 and 2013, 46 patients (17 females and 29 males; mean age 48,1years), a revision radical cavity surgery procedure was performed in combination with a canalplasty procedure. Table 1 gives a comprehensive overview of baseline characteristics. Of these individuals, 12 patients smoked at the time of surgery (26%) and 1 patient suffered from diabetes (2%). In 12 cases (26%), prior revision radical cavity surgery had been performed on the side of intervention not resulting in a dry cavity. In 3 of these 12 cases (7%), only a meatoplasty procedure was performed. On the affected side, prior otologic surgery was performed once in 18 cases (39% primary radical cavity), twice in 10 cases, three times in 4 cases, four times in 7 cases and five, six and seven times in 2 cases each. In 59% of the cases, radicalization was secondary to multiple canal wall up attempts. Follow-up of individuals ranged from 3 to 56 months with a mean of 18 months. Median re-epithelialization of the OEAC lasted 8.9 weeks (range 3.6 to 25.6 weeks). Smoking had no significant effect ($p=0,11$) on the time to complete re-epithelialization. No significant difference in healing time was observed between those individuals who underwent prior revision radical cavity surgery and those undergoing a first attempt ($p=0,29$).

Table 1 Baseline characteristics of all operated patients (n = 46)

| Baseline characteristics | | | |
|----------------------------|-------------|-----------|--------------|
| Male gender, n (%) | 29(63%) | | |
| Smokers, n (%) | 12(26%) | | |
| Diabetes | 1(2%) | | |
| | Mean | SD | Range |
| Age (y) | 48,1 | 17,7 | 13,6-86,1 |
| Time to heal (wk) | 8,6 | 4,6 | 3,6-25,6 |
| amount of prior operations | 2 | 2 | 1-9 |
| Follow up (mos) | 17,9 | 12,9 | 3-56 |

In our series, only one complication related to the T-flap (formation of granulation tissue) was seen in the healing period. This complication was successfully treated with local removal and application of polycresulen. Five patients in our series underwent revision surgery afterwards, all related to middle ear problems: a protruding prosthesis (one case), disappointing hearing result (three cases) and a persistent tympanic membrane perforation (one case). A dry, waterresistant ear was reached in all cases (in the aforementioned five cases not primarily, but after revision surgery).

Discussion

Inadequate canalplasty during a canal wall down procedure has been shown to contribute to a draining cavity. Yet, to our knowledge, only few reports and no description of the surgical technique and its results have been published. We suggest the evaluation of the shape of the OEAC when contemplating revision radical cavity surgery and advocate its use in revision surgery as it allows the complete exposure of the entire OEAC, thereby facilitating the creation of a smooth OEAC as drilling movements can be made in a circular fashion without exerting direct lateral to medial force. Furthermore maximal preservation of the delicate epithelial lining of the OEAC is allowed, rendering the use of skin grafts less likely or not necessary at all. Another advantage is the ease with which subcutaneous fibrosis (which is regularly present in prolonged inflamed ears) can be removed if necessary. Complete re-epithelization lasted approximately two months, a result comparable to another report studying revision radical cavity surgery.¹⁰ When compared to regular canalplasty, the time to complete re-epithelialisation is however prolonged.⁸ In concordance with our earlier report on canalplasty⁸ smoking did not significantly influence the time to heal. The number of prior procedures did not influence results.

Complications related to the canalplasty procedure occurred in 2% of cases. Revision surgery was indicated in 11% of cases however. One could argue that in these 11% of cases, a complication occurred as revision surgery was indicated. The need for revision surgery was however not related to the canalplasty procedure in only one case. In all other cases, the epithelial lining healed without problems.

In all cases a dry ear and water resistant was attained. Although the results of this study do not directly prove that an adequately performed canalplasty would result in a dry ear, at least it describes a surgical technique that provides good accessibility of an area that is thought to be involved with ongoing infection in chronically discharging ears (pre-tympanic sulcus) and that enhances easier cleaning in outpatient setting. If the cause of chronic discharge is thought to be located in the radical mastoid cavity itself, obliteration of the cavity is a wise surgical step in many cases. Different obliteration and canal wall reconstruction techniques are available and discussion of the pros and cons each single technique are outside the scope of this article. Reconstructing the posterior canal wall without adequate canalplasty however, may result in an undesirably narrow canal, thereby exchanging one problem for another. This surgical technique should therefore be thought of whilst performing a reconstruction of the canal wall. Our study is retrospective and therefore subject to limitations. First, no control group was included. Thus, the added value of canalplasty over, for example, revision radical cavity surgery

without canalplasty was not possible. Second, follow-up in some patients (n=5) was very short (less than 6 months), perhaps creating a slight positive bias. Even so, the represented results do show the added value of a canalplasty with a T-flap meatal skin flap in revision radical cavity surgery.

Conclusion

This retrospective series shows that the described technique for canalplasty using a T-flap in revision radical surgery is of added value and contributes to favourable end results in otosurgery.

Acknowledgments

None.

Conflicts of interest

The authors declare that there is no conflicts of interest.

References

1. Yung M, Tassone P, Moumoulidis I, Vivekanandan S. Surgical management of troublesome mastoid cavities. *J Laryngol Otol.* 2011;125(3):221–226.
2. Khalil HS, Windle-Taylor PC. Canal wall down mastoidectomy: A long term commitment to the outpatients? *BMC Ear Nose Throat Disord.* 2003;3(1):1.
3. Ojala K, Sorri M, Sipila P, Palva A. Late changes in ear canal volumes after mastoid obliteration. *Arch Otolaryngol.* 1982;108(4):208–209.
4. Megerian CA, Cosenza MJ, Meyer SE. Revision tympanomastoid surgery. *Ear Nose Throat J.* 2002;81(10):718–726.
5. Black B. Mastoidectomy elimination. *Laryngoscope.* 1995;105(12 Pt 2 Suppl 76):1–30.
6. Bercin S, Kutluhan A, Bozdemir K, et al. Results of revision mastoidectomy. *Acta Otolaryngol.* 2009;129(2):138–141.
7. Nadol JB Jr. Revision mastoidectomy. *Otolaryngol Clin North Am.* 2006;39(4):723–740.
8. Van Spronsen E, Ebbens FA, Mirck PG, et al. Canalplasty: The technique and the analysis of its results. *Am J Otolaryngol.* 2013;34(5): 439–444.
9. Yung M, Smith P. Mid-temporal pericranial and inferiorly based periosteal flaps in mastoid obliteration. *Otolaryngol Head Neck Surg.* 2007;137(6):906–912.
10. Ucar C. Canal wall reconstruction and mastoid obliteration with composite multi-fractured osteoperiosteal flap. *Eur Arch Otorhinolaryngol.* 2006;263(12):1082–1086.